Washington State Health Care Authority
Health Technology Assessment

Stereotactic Radiation Surgery and Stereotactic Body Radiation

Health Technology Assessment Program

Final Key Questions - Public Comments

July 18, 2012

Health Technology Assessment Program (HTA)
PO Box 42712
Olympia, WA 98504-2712

http://www.hta.hca.wa.gov
SHTAP@HCA.WA.GOV
(360) 725-5126

Public Comments and Responses

Stereotactic Radiation Surgery and Stereotactic Body Radiation Therapy

July 18, 2012

Center for Evidence-based Policy
Oregon Health & Science University
3455 SW US Veterans Hospital Road
Mailstop SN-4N, Portland, OR 97239-2941
Phone: 503.494.2182
Fax: 503.494.3807
http://www.ohsu.edu/xd/research/centers-institutes/evidence-based-policy-center/index.cfm

Table of Contents

Response to Public Comments 2
Table 1. Reponse to Public Comments on Key Questions 2
Public Comments on Key Questions 18
American Association of Neurological Surgeons (AANS) and Congress of Neurological Surgeons (CNS) 18
American College of Radiation Oncology (ACRO) 18
American Society of Radiation Oncology (ASTRO) 21
Jeanne R. Berry 24
Thomas Carlson (Wenatchee Valley Medical Center) 27
CyberKnife Coalition 28
Elekta 40
International RadioSurgery Association (IRSA) 40
Nancy Lang 58
L. Dade Lunsford (University of Pittsburg Physicians, Department of Neurological Surgery. 59
Berit L Madsen, R. Alex His, and Health R. Foxlee (Peninsula Cancer Center) 60
Dean G. Mastras and Randy D. Sorum (Tacoma/Valley Radiation Oncology Centers) 61
James F. Raymond (RadiantCare Radiation Oncology) 65
Eric W. Taylor (Evergreen Radiation Oncology) 67
Tumor Institute Radiation Oncology Group 68
University of Washington Medicine / Seattle Cancer Care Alliance Department of Radiation Oncology, UW Department of Neurological Surgery 80
Us TOO International 87
Varian Medical Systems 89
Sandra Verneulen (Swedish Radiosurgery Center) 97
Virginia Mason Medical Center 111
Appendix A. Sample SRS and SBRT Policies Submitted by ASTRO 118
Appendix B. References and Attachments Submitted by Elekta 150
Appendix C. References Submitted by Varian Medical Systems 178

RESPONSE TO PUBLIC COMMENTS

The Center for Evidence-based Policy is an independent vendor contracted to produce evidence assessment reports for the WA HTA program. For transparency, all comments received during the comments process are included in this response document. Comments related to program decisions, process, or other matters not pertaining to the evidence report are acknowledged through inclusion only.

This document responds to comments from the following parties:

Key Questions

- American Association of Neurological Surgeons (AANS) and the Congress of Neurological Surgeons (CNS)[1]
- American College of Radiation Oncology (ARCO)
- American Society for Radiation Oncology (ASTRO)
- Jeanne R. Berry
- Thomas Carlson, MD (Wenachee Valley Medical Center)
- Cyberknife Coalition
- Elektra
- International RadioSurgery Association (IRSA)[2]
- Nancy Lang
- L. Dade Lunsford, MD (University of Pittsburg Physicians, Department of Neurological Surgery)
- Berit Madsen, MD, FACR (Peninsula Cancer Center)
- Dean G. Mastras, MD and Randy D. Sorum, MD (Tacoma/Valley Radiation Oncology Centers)
- James F. Raymond, MD (RadiantCare Radiation Oncology)
- Eric W. Taylor, MD
- Tumor Institute Radiation Oncology Group
- University of Washington Medicine / Seattle Cancer Care Alliance Department of Radiation Oncology, UW Department of Neurological Surgery
- Us TOO International

[1] This public comment was received in July 2012 in response to revised Key Questions.
[2] This public comment was received in July 2012 in response to revised Key Questions.

- Varian Medical Systems
- Sandra Vermeulen, MD (Swedish Radiosurgery Center)
- Virginia Mason Medical Center

Specific responses pertaining to each comment are included in Table 1 below. The full version of each public comment received is available in the Public Comments section, beginning on page 20.

Additional resources provided by parties can be found in Appendices A to C starting on page 145.

Table 1. Response to Public Comments on Key Questions

Reviewer	Comment	Disposition
American Association of Neurological Surgeons (AANS) and the Congress of Neurological Surgeons (CNS)		
	"We are concerned that some of the key questions in the "*DRAFT Key Questions and Background Stereotactic Radiation Surgery and Stereotactic Body Radiation Therapy"* are very general and we are eager to provide more specific details in response to the draft technical assessment expected on July 6, 2012." [*see page xx for full comment*]	*Thank you for comments.* *No changes to the Key Questions.*
	Summary KQ1. [*see page 20 for full comment and evidence cited*] • Discusses effectiveness of SRS for patients with CNS tumors and non-CNS cancers	*Thank you for comments.* *All references were forwarded to TAC for consideration in the review process.* *No changes to the Key Questions.*
	Summary KQ2. [*see page 21 for full comment and evidence cited*] • Discusses harms of SRS compared with EBRT	*Thank you for comments.* *All references were forwarded to TAC for consideration in the review process.* *No changes to the Key Questions.*
	Summary KQ3. [*see page 21 for full comment and evidence cited*] • Discusses effectiveness of SRS in subpopulations including gender, age, setting, provider characteristics, equipment, quality assurance standards and procedures.	*Thank you for comments.* *All references were forwarded to TAC for consideration in the review process.* *No changes to the Key Questions.*
	Summary KQ4. [*see page 21 for full comment and evidence cited*] • Discusses cost-effectiveness of SRS for patients with brain metastases, spinal metastases, and skull base tumors	*Thank you for comments.* *All references were forwarded to TAC for consideration in the review process.* *No changes to the Key Questions.*
American College of Radiation Oncology (ACRO)		

Reviewer	Comment	Disposition
	"There is clear and increasing evidence that in certain circumstances, SBRT and SRS may be equivalent and/or preferable to conventional fractionated and protracted radiation. SBRT and SRS, unlike IMRT, relate to "biology" and not "technology," in that they merely represent the delivery of high-dose, short-course radiation (5 or fewer treatments, rather than daily, protracted, lower-dose, longer-course therapies). Evidence mounts that numerous sites, including brain, spinal cord, liver, and lung, as well as other emerging indications, are appropriately treated by SRS (for central nervous system) and SBRT (for non-central nervous system). We understand that the American Society for Radiation Oncology (ASTRO) has included its own model coverage policies on SRS, SBRT and IMRT for your review that outline specific technology of each treatment, clinical indications, coding considerations and references. ACRO supports your review of these materials and their conclusions. We also are aware that physicians with the Swedish Medical Center are submitting information regarding studies that have been performed relating to SRS, SBRT and IMRT. We would encourage the committee to review these in detail." [*see pages 18 to 19 for full comment*]	*Thank you for comments.* *No changes to the Key Questions.*
American Society of Radiation Oncology (ASTRO)		
	"The Key Questions posed for the SRS, SBRT, and IMRT are extensive and ask for a level of detail that we can not produce within the time frame allotted. The information requested for all three technologies, specifically comparisons to external beam radiation therapy) benefits and harms), and diferential efficacy or safety issues in subpopulations including consideration of gender, age, site and type of cancer, stage and grade of cancer and setting, provider characteristics, equipment, quality assurance standards and procedures, constitutes a full research study that would take many months to produce. While ASTRO believes these technologies offer clear benefits to many of the cancer patients our members treat, we would require significantly more time to adequately address the important issues raised in the Key Questions.	*Thank you for comments.* *No changes to the Key Questions.*

Reviewer	Comment	Disposition
	ASTRO plans on reviewing the draft report that will be produced as a result of the public comment period and we look forward to reviewing this report in early July. We have noted that the Health Technology Clinical Committee that will be reviewing the technology assessment reports and making coverage decisions does not include a radiation oncologist and we strongly recommend that a radiation oncologist be added to this committee. In anticipation of the more detailed comments that we will submit in response to the draft report, we offer a general observation relating to the fundamental basis of some of our positions about IMRT in particular. During the past two decades, an abundant number of clinical studies have characterized the relationship between the dose given to various normal tissues using 3D EBRT and the risk of toxicity to those tissues. There are recogonized dose thresholds know to relate to the risk of toxicity for bowel, bladder, spinal cord, and other important organs. Whereas IMRT offers the capacity to avoid exceeding those recognized thresholds for toxicity, it is considered an appropriate standard for numberous indications as a result of this property. The field of radiation oncology has not considred it ethical or resource-efficient to conduct head-to-head tcomparisons of 3D EBRT vs. IMRT in all settings where a clear improvement in a surrogate measure of toxicity risk is easily demonstrated. We have included ASTRO's model coverage policies on SRS, SBRT, and IMRT for your review that outline the specific technology of each treatment, clinical indications, coding considerations, and references." [*see pages 21 to 22 for full comment*]	
Jeanne R. Berry		
	Summary – Shared story of husband's experience with prostate cancer and Cyberknife treatment. [*see pages 24 to 26 for full comment*]	*Thank you for your comment.* *No changes to Key Questions.*
Thomas Carlson, MD (Wenatchee Valley Medical Center)		
	"I am concerned with respect to the path we have been going down regarding the	*Thank you for your comment.*

Reviewer	Comment	Disposition
	complexity of reimbursement evaluation. We seem to be reimbursing physicians based on the tools they are using to accomplish a task as opposed to the task itself. In the case of IMRT, Stereotactic Radiosurgery (in the brain or body) or brachytherapy, we are reimbursing based on the tool. Do we reimburse a surgeon for using one scalpel blade over another? No. The surgeon chooses what's most appropriate for the situation and is paid for the job. I believe a tremendous amount of waste could be removed from the system if a case rate reimbursement model was initiated." [*see page 27 for full comment*]	*No changes to Key Questions.*
CyberKnife Coalition (John Rieke, MD FACR [MultiCare Regional Cancer Center] and Linda F Winger, MSc, FACHE)		
	Summary: General background information on CyberKnife system. [*see pages 28 to 29 for full comment*]	*Thank youfor your comment.*
	Summary KQ1. [*see pages 29 to 36 for full comment and evidence cited*] • Comparative data of conventiaonl external beam radiation treatment (EBRT)versus CyberKnife Clinical Outcomes for Spine • Comparative data of conventiaonl external beam radiation treatment (EBRT)versus CyberKnife Clinical Outcomes for Non-Small Cell Lung • Comparative data of conventiaonl external beam radiation treatment (EBRT)versus CyberKnife Clinical Outcomes for Liver Metastases • Comparative data of conventiaonl external beam radiation treatment (EBRT)versus CyberKnife Clinical Outcomes for Prostate Cancer • Comparative data of conventiaonl external beam radiation treatment (EBRT)versus CyberKnife Clinical Outcomes for Pancreatic Cancer	*Thank youfor your comment.* *All references were forwarded to TAC for consideration in the review process.* *No changes to Key Questions.*
	Summary KQ 2. [*see pages 36 to 37 for full comment*] • Discussion of harms from SBRT, SRS, EBRT and CyberKnife	*Thank you for your comment.* *No changes to Key Questions.*
	"The unique codes CMS created for Robotic Stereotactic Radiosurgery are G0339 and G0340. While the majority of fractionated SRS and SBRT in the United States are performed with the CyberKnife, curiously G0339 and G0340 are not listed on	*Thank you for your comment.* *No changes to Key Questions.*

Reviewer	Comment	Disposition
	the Washington Medicaid Fee Schedule, and the codes for gantry-based SRS and SBRT (G0251 and G0173) are." [*see page 36 for full comment*]	
	Summary KQ3. [*see page 37 for full comment*] • Discussion of Food and Drug Administration clearance for CyberKnife System • Provided summary of Aetna's national SBRT policy	*Thank you for your comment.* *No changes to Key Questions.*
	Summary KQ4. [*see page 38 for full comment and evidence cited*] • Lack of clinical literature which compares the cost of radiation therapies • Three cost-effectiveness studies provided	*Thank you for your comment.* *All references were forwarded to TAC for consideration in the review process.* *No changes to Key Questions.*
	Summary Conclusion [*see page 38 for full comment*] • SRS/SBRT is the standard of care available to cancer patients. SRS/SBRT can treat patients with brain, spine, lung, liver, pancreas, and prostate cancer • Urges Washington State Health Care Authority to add codes G0339 and G0340 as covered benefit for Medicaid patients in the State of Washington	*Thank you for your comment.* *No changes to Key Questions.*
Elekta		
Todd Howard, MBA	• Submitted four articles for consideration [*see pages 40 to 41 for full comment and evidence cited*]	*Thank you for your comment.* *All references were forwarded to TAC for consideration in the review process.* *No changes to Key Questions.*
Eleckta Dossier	Summary KQ1 [*see pages 50 to 52 for full comment and evidence cited*] • Provided conclusions from recent guidelines from the American Society of Therapeutic Radiation Oncology, the American Association of	*Thank you for your comment.* *All references were forwarded to TAC for consideration in the review process.*

Reviewer	Comment	Disposition
	Neurological Sugeons, and the Congress of Neurological Surgeons Summary KQ2 [*see pages 53 to 54 for full comment and evidence cited*] • Discusses the benefits of Gamma Knife and provides supporting references Summary KQ3 [*see pages 55 to 56 for full comment and evidence cited*] • Discusses a proposed grading to provide detailed prognostic information for radiosurgery • Discusses the efficacy and safety of Gamma Knife Summary KQ4 [*see page 57 for full comment and evidence cited*] • Suggests a cost advantage for SRS followed by surveillance in terms of quality adjusted life years	*No changes to Key Questions.*
International RadioSurgery Association (IRSA)		

	Summary KQ1 [*see pages 59 to 61 for full comment*]
	• Discusses patient factors to consider based on IRSA Radiosurgery Guidelines for the conditions of
	  ○ Acoustic neuroma
	  ○ Intracranial arteriovenous malformations (AVM)
	  ○ Metastatic brain tumors
	  ○ Trigeminal neuralgia refractory to medical treatment
	  ○ Pituitary adenomas
		Thank you for your comments. We are aware that, for some tumor types such as acoustic neuroma, SBRT has been compared to treatments other than EBRT (including surgery, observation, chemotherapy, intensity modulated radiation therapy [IMRT]). EBRT may or may not be the optimal or most appropriate comparator in these instances. The scope of this technology assessment report is to evaluate SBRT where radiation therapy is an appropriate treatment choice. The purpose of the report is not to evaluate the most effective treatments for various tumors, but to evaluate whether there is a role for SBRT compared to EBRT. A description of the therapies used for each tumor type will be included in the body of the

Reviewer	Comment	Disposition
		report. *Guidelines were forwarded to TAC for consideration in the review process.* *No changes to Key Questions.*
	Summary KQ2 [*see pages 61 to 62 for full comment*] • Discusses benefits of SBRT over EBRT	*Thank you for your comment.* *Guidelines were forwarded to TAC for consideration in the review process.* *No changes to Key Questions.*
	Summary KQ3 [*see pages 62 to 63 for full comment*] • Discusses harms of EBRT compared to SRS and SBRT • Discusses use of EBRT in pediatric population	*Thank you for your comment.* *Guidelines were forwarded to TAC for consideration in the review process.*
	Summary KQ4 [*see pages 63 to 66 for full comment*] • Provides cost information for SRS, SRS/SBRT, and EBRT	*Thank you for your comment.* *Guidelines were forwarded to TAC for consideration in the review process.* *No changes to Key Questions.*
Nancy Lang		
	"I am a 70 year old woman with ovarian cancer. My first diagnosis was in December 2004 with surgery and complete hysterectomy, followed in January 2005 by chemotherapy, a combination of carboplatin and taxol. My cancer returned in 2007 with a duplication of the previous chemotherapy and, in 2010 another round of chemotherapy with an addition of Avastin. In 2011, after a reaction to the carbo and taxol, I continued on a different treatment option of cisplatin and gemsidibine while waiting for approval for CyberKnife radiosurgery. I selected to go with CyberKnife because a new tumor, detected in a November 2010 PET –CT showed the location in the *periportal*	*Thank you for your comment.* *No changes to Key Questions.*

Reviewer	Comment	Disposition
	region. Surgery in this area is not a good option. After receiving marker fiducials my CyberKnife treatment began the end of February over a period of five treatments. I had neither pain nor any negative reaction during or after my treatment. A November 2011 follow-up PET-CT displayed a recurrence in *aortocaval lymph nodes*, requiring additional treatment. After three medical opinions clearly stating that, because of the location of the recurrence, surgery was not an option and chemo was taking a toll on my body, CyberKnife would be the best treatment. With my health insurance approval we started treatment January 3, 2012 for five days. I walked daily, after each treatment, and continue to do so. I felt nothing during the treatment, maybe one slow day when I felt a little tired but, in general I feel perfectly normal." [*see page 58 for full comment*] With my experience, I can highly vouch for the value of CyberKnife treatment process and recommend it be funded by all health care programs."	
L. Dade Lunsford (University of Pittsburg Physicians, Department of Neurological Surgery)		
	"Stereotactic radiosurgery is an integral part of the field of neurosurgery with collegial interaction with the field of radiation oncology. At our center, more than 11,300 patients have undergone Gamma Knife stereotactic radiosurgery over the last 25 years since we placed the first Leksell Gamma Knife in North America." "Stereotactic radiosurgery is used for approximately 20% of all brain indications for intervention at our center with an increasing role in the management of metastatic cancer, arteriovenous malformations, chronic pain especially related to trigeminal neuralgia, glial neoplasms, and a wide variety of skull-based tumors including pituitary tumors." "In the last 25 years, more than 500 outcome studies have been published related to Gamma Knife radiosurgery, and it is approved for use by all insurance providers. This type of technique has been a radical transformation in the management of patients with a wide variety of otherwise frequently fatal brain	*Thank you for your comment.* *No changes to Key Questions.*

Reviewer	Comment	Disposition
	conditions. Because of its superior technology and minimally invasive nature, patients are often done as an outpatient and can retu+rn to regular activities on the following day. Therefore, quality assessment, comparative outcomes research, and cost effectiveness research have substantiated the role of this technology in a wide variety of indications." [*see page 59 for full comment*]	
Berit L. Madsen, MD, R. Alex His, MD, and Heath R. Foxlee, MD (Peninsula Cancer Center)		
	"We have received copies of the letters that Dr. Todd Barnett and his associates at the Swedish Cancer Institute have written in support of Intensity Modulated Radiotherapy (IMRT) and Stereotactic Radiotherapy (SRT), currently under review by your board. We have reviewed their letters and supportive documents and applaud their work and endorse their recommendations that IMRT and SRT/SBRT are important treatment techniques that benefit cancer patients while being safe and cost effective. IMRT and stereotactic radiotherapy are techniques that have been in common use in most radiation therapy centers for greater than 10 years; it would be impossible to think of not utilizing these advanced techniques for patients with conditions that warrant such treatment. We are hopeful that your review will support the continued utilization of these beneficial treatment techniques." [*see page 60 for full comment*]	*Thank you for your comment.* *No changes to Key Questions.*
Dean G. Mastras, MD and Randy D. Sorum, MD (Tacoma/Valley Radiation Oncology Centers)		
	"These technologies are currently available in many places in the State of Washington and are quickly becoming standard of care for many treatment sites throughout the nation. As clearly stated in the summary, these technologies are more expensive than conventional radiation. The trade off, however, is very significant when it comes to not only improvements in outcomes but they are vastly superior in reduction in side effects and toxicity. We are also able to treat specific tumor locations that we never were able to accomplish in the past with minimal morbidity and harm to the patient. There is no question that radiation can be extremely harmful to living tissue. My 20+ year career can certainly attest to that. When I explain these new modalities to patients, one of the very first	*Thank you for your comment.* *No change to Key Questions.*

Reviewer	Comment	Disposition
	comments I make is that I wish I'd had these technologies available to me during the early days of my career. The number of patients treated with significant radiation morbidity, both short term and long term, in the form of bowel damage, bladder damage, lung damage, soft and bony structure damage as well as even brain damage, could have been reduced and outright avoided if I'd had these technologies available in the past. These newer modalities allow us to target tissues at risk and greatly reduce surrounding tissues that do not need to be radiated. Not only do these technologies allow us to target the cancer and spare the surrounding normal tissue, but they allow us to give even higher doses of radiation to the cancer, thus improving outcomes. Nowhere has this become more evident than in treatment of cancer of the prostate. The concept of increasing the dose of radiation (known as dose escalation) to prostate cancer has been verified in numerous clinical trials. In the past we were unable to deliver high doses of radiation to the prostate because the organ is "sandwiched" between the bowel and the bladder. " "Stereotactic body (SBRT) and stereotactic radiosurgery (SRS) are again technologies that allow us with pin-point accuracy to deliver very toxic doses of radiation therapy to cancers and eliminate surrounding tissue. One only needs to see a patient who is trying to live with radiation damage of the brain from old conventional treatments to realize the significance of these new technologies. We are now able to treat patients non-surgically for aneurysms, tremors, brain metastases and even gliomas. Patients are alive and function today because of these technologies. They certainly can be treated by more conventional means but the price is higher in side effects and long-term complications. I have seen patients harmed by conventional radiation to a much greater extent. " [*see pages 61 to 64 for full comment*]	
James F. Raymond (RadiantCare Radiation Oncology)		
	"We share your concerns pertaining to patient safety, effectiveness, efficiency and the rising cost of contemporary radiation treatment modalities. We have instituted a group designed to address these issues as they relate to the	*Thank you for comments.* *No changes to the Key Questions.*

Reviewer	Comment	Disposition
	treatment of the patients of RadiantCare. SRS and SBRT are both extremely precise treatment modalities which can be delivered with a Linear Accelerator, Gamma Knife, or Cyberknife system. These systems are designed to precisely target tumor regions with millimeter accuracy. These treatments require intense quality assurance, measurements and monitoring during treatment since the entire dose is delivered through 1-5 treatments. This requires a significant amount of medical physicist support to ensure accuracy. We believe that the initial increased cost associated with IMRT, SBRT, and SBRT is outweighed by their long term savings due to lower costs associated with lower risk of side effects and increased clinical outcomes." [*see page 65 for full comment*] • Summary KQ1 – references studies supporting role of SRS and SBRT for various cancers [*see page 65 for full comment*] • Summary KQ2 – Discusses benefits of SRS and SBRT [*see pages 65 to 66 for full comment*] • Summary KQ3 – Discusses SRS and SBRT as beneficial options to treat an array of cancers [*see page 66 for full comment*] • Summary KQ 4 – Discusses aspects of quantifying the cost effectiveness of EBRT and SRS/SBRT [*see page 66 for full comment*]	
Eric Taylor (Evergreen Radiation Oncology)		
	"Stereotactic Radiosurgery has been used for certain brain malignancy situations as well as for some benign diseases. The clinical experience is well and heavily reported in the literature. My main concern for overuse of SRS is in the patient with brain metastases. The National Comprehensive Cancer Network guidelines (nccn.org) are clear that this technique is appropriate for patients with 1-3 brain metastases and with disease reasonably controlled or stable elsewhere...so that the cost of such treatment could be justified in well selected patients.	*Thank you for your comment.*

Reviewer	Comment	Disposition
	Unfortunately, I think that there is OVERUSE of SRS and IMRT for patients with multiple brain metastases whose ultimate outcomes and lives are unfortunately very limited. The use of Stereotactic Body Radiation Therapy (SBRT) or Stereotactic Ablative Radiation Therapy (SABR) are becoming of increasing usefulness and benefit. The Japanese data for early lung cancer treatment with SBRT is excellent and from an outcome perspective is competitive with surgery. There is a current randomized trial sponsored by the American College of Surgeons and the Radiation Therapy Oncology Group comparing SBRT/SABR versus surgery. Depending on the outcomes of this study, this might support increased use of SBRT in the future. Currently, SBRT is the standard of care (National Comprehensive Cancer Network Guidelines at nccn.org) for early lung cancers in the patient that is medically inoperable. If well planned and delivered, patients tolerate this therapy very well with excellent reports from the current literature (Japan, UT Southwestern, Indiana and others)." [*see page 67 for full comment*]	
Tumor Institute Radiation Oncology Group		
	"As experts in the field of Radiation Oncology, we embrace your concerns regarding safety, efficacy, and cost of contemporary radiation modalities. Technologies such as IMRT, SRS, and SBRT have broken new ground in their capability to control cancer and minimize side effects. Our goal is to help educate health providers and healthcare payers, as well as government, business, and other professionals as to the patients for whom use of these newer technologies can mean a world of difference in regard to cancer control and a decreased risk of treatment related side effects. The utility of IMRT, SRS, and SBRT in many circumstances is very specifically dependent on a patient's cancer, their anatomy, the proximity of critical structures, and prior radiation dose delivered. The key aspects that all these modalities have in common is better dose distributions: escalated doses to tumors, lower doses (and lower resultant toxicity) to normal tissue. Using IMRT,	*Thank you for your comment.* *No change to Key Questions.*

Reviewer	Comment	Disposition
	SRS, and SBRT, it is now potentially feasible to deliver safe curative or safe palliative treatment to many patients where treatment was not even an option with conventional external beam radiation therapy. For example, in cases where tumors recur in a previously irradiated field, re-irradiation with IMRT, SRS, or SBRT may deliver a long term cure that was not previously possible. We realize that a circumstance such as this is not one in which a comparative trial could be conducted, for most of these patients simply would not be a candidate for treatment with a conventional external beam radiation therapy approach. We believe that it is imperative to be able to offer these treatments to patients in an expedient time frame when indicated. We remain readily available and encourage an open dialogue on these topics. We have tried our best given the short comment period to address your questions regard SBRT and SRS. Although there are increased costs associated with newer technologies such as IMRT, SRS, and SBRT, their effectiveness and lower risk for side effects demonstrates long term cost savings. As well, the relevant key comparison is often IMRT, SRS, or SBRT in comparison to other different modalities of treatment, such as surgery, or radiofrequency ablation (rather than to conventional external beam irradiation). For example, there was a publication a few months ago comparing the cost effectiveness, quality of life and safety for medically inoperable lung cancer patients. The study compared conventional radiation, SBRT, and radiofrequency ablation. SBRT was by far the most effective and cost effective treatment, even though it may have the highest upfront direct cost (reference: [1] Sher, Wee and Punglia, **Cost-effectiveness analysis of stereotactic body radiotherapy and radiofrequency ablation for medically inoperable, early-stage non-small cell lung cancer**. Journal/Int J Radiat Oncol Biol Phys, 81, e767-74, 2011). Given the extraordinarily short time period for comment, we have done our best to summarize responses to the four key questions of the Washington State Healthcare Authority with regard to SRS, and SBRT in comparison to conventional (conformal) external beam therapy (EBRT). We must emphasize, though, while	

Reviewer	Comment	Disposition
	there are many well done peer reviewed studies from top academic institutions pertinent to IMRT, SRS and SBRT, and in some cases there are head-to-head comparisons which demonstrate the benefits of this technology, the short response timeframe created by your March 6th deadline, which apparently is not negotiable, does not allow adequate time to research. Therefore, we want to be sure the Washington State Healthcare Authority and its staff are advised that we believe the key questions posed for SRS, SBRT and IMRT are extensive and a more complete level of detail is not possible to produce within the time frame allotted." [*see pages 68 to 69 for full comment*]	
	Summary – KQ 1 [*see pages 69 to 77 for full comment and evidence submitted*] • Discusses the use of IMRT and SBRT for the treatment of prostate cancer • Discusses use of SRS/SBRT for the treatment of head and neck cancer • Discusses use of SRS/SBRT for the treatment of central nervous system/spine cancer • Discusses the use of SBRT for the treatment of gastrointestinal/pancreatic cancers • Discusses the use of SBRT for gastrointestinal/liver metastases • Discusses the use of SBRT for gastrointestinal/primary liver cancers • Discusses the use of SBRT for lung cancers • Discusses the effectiveness and safety of SBRT for re-irradiation Summary – KQ2 [*see pages 77 to 78 for full comment and evidence submitted*] • Discusses the safety and harms of SRS and SBRT Summary – KQ3 [*see page 78 for full comment and evidence submitted*] • Refers to KQ1 and KQ2 Summary – KQ4 [*see page 79 for full comment and evidence submitted*]	*Thank you for your comment.* *All references were forwarded to TAC for consideration in the review process.* *No changes to Key Questions.*

Reviewer	Comment	Disposition
	• Discusses the cost and cost-effectiveness of SRS, SBRT, IMRT, and EBRT	
University of Washington Medicine / Seattle Cancer Care Alliance Department of Radiation Oncology and UW Department of Neurological Surgery		
	Summary KQ1. [*see pages 82 to 85 for full comment and evidence cited*] • Provides an overview of the effectiveness of stereotactic radiosurgery • Discusses the benefit of SRS/SBRT for a range of cancers Summary KQ2. [*see page 85 for full comment and evidence cited*] • Discusses the risks of permanent neurological deficit in using SRS/SBRT for a range of cancers Summary KQ3. [*see pages 85 to 86 for full comment and evidence cited*] • Discusses the safety and efficacy concerns for SRS/SBRT Summary KQ4. [*see page 86 for full comment and evidence cited*] • Discusses cost and cost-effectiveness of SRS/SBRT compared with conventional surgery, resection, and EBRT	*Thank you for your comment.* *All references forwared to TAC.* *These studies provide evidence. No changes to Key Questions.*
Us TOO International		
Pamela Barrett	"In response to your recent request to concerned stakeholders to submit comments as part of your upcoming review of stereotactic radiosurgery and stereotactic body radiation therapy (SBRT), we prostate cancer survivors in the Us TOO International Prostate Cancer Education & Support Network encourage the Washington State Health Care Authority add prostate cancer as a diagnosis that is eligible for coverage under its SBRT policy." [*see page 87 for full comment*]	*Thank you for your comment.* *No changes to Key Questions.*
Thomas N. Kirk	"We believe that men who happen to live in Washington state and have Medicare medical coverage should not be denied access to SBRT (stereotactic body radiation therapy) treatment. We feel that it is Medicare's obligation to provide coverage for all medical	*Thank you for your comment.* *The Washington Health Technology Assessment program addresses health care services provided by state government, not Medicare, which is a*

Reviewer	Comment	Disposition
	treatments that have shown to improve the lives of prostate cancer patients. SBRT, a more recent form of radiation therapy, has been used to treat prostate cancer since 2001. Data suggests that this treatment is as effective as conventional treatments such as HDR brachytherapy, alternative external beam radiation techniques, and surgery. Due to the unique nature of prostate cancer, we do not believe there is not a "one size fits all" treatment for this disease. However, it is our opinion that patients should be afforded the opportunity to select a therapy that both he and his health care provider feel will provide the best possible outcomes. This requires that all clinically appropriate treatment options be eligible for coverage under the Medicare program. We request that the Washington State Health Care Authority add prostate cancer as a diagnosis that is eligible for coverage under its SBRT policy. By providing coverage for this treatment, the state of Washington will provide hope to thousands of men and their families who suffer from this disease." [*see page 88 for full comment*]	*federal program.* *No changes to Key Questions.*
Varian Medical Systems		
	Summary KQ1. [*see pages 92 to 93 for full comment and evidence cited*] • Summarized evidence supporting the effectiveness of SRS and SBRT Summary KQ2. [*see page 94 for full comment and evidence cited*] • Summarized evidence supporting the benefits, safety, and efficacy of SRS and SBRT Summary KQ4. [*see pages 95 to 96 for full comment and evidence cited*] • Summarized studies discussing the cost-effectiveness of SRS and SBRT	*Thank you for your comment.* *All references were forwarded to TAC for consideration in the review process.* *No changes to Key Questions.*
Sandra Verneulen (Swedish Radiosurgery Center)		
	Summary – Acoustic Neuroma [*see pages 97 to 99 for full comment and evidence cited*] • Provided a summary of clinical results from Gamma Knife radiosurgery in	*Thank you for your comment.* *All references were forwarded to TAC for*

Reviewer	Comment	Disposition
	relation to tumor growth control, hearing preservation, facial nerve and trigeminal nerve preservation, neurofibromatosis 2, and clinical algorithm for decision making. Summary – Trigeminal Neuralgia [*see pages 99 to 100 for full comment and evidence cited*] • Discusses the efficacy of Gamma Knife stereotactic radiosurgery for trigeminal neuralgia, and provides factors to consider in making a recommendation for Gamma Knife stereotactic radiosurgery. Summary – Pituitary Adenoma [*see pages 100 to 103 for full comment and evidence cited*] • Discusses the applicability of stereotactic radiosurgery for pituitary adenoma and tumor growth control after radiosurgery for this condition • Discusses the function effect of radiosurgery (e.g., growth hormone secreting adenomas (acromegaly), ACTH secreting adenomas, prolactin secreating adenomas), radiation tolerance of functioning pituitary tissue, complications of pituitary radiosurgery, clinical algorithms for decision making, and fractionated radiation theraby (EBRT) Summary – Intra-cranial Ateriovenous Malformations [*see pages 103 to 104 for full comment and evidence cited*] • Discusses the use of stereotactic radiosurgery for patients with unresectable AVMs including the probability of AVM obliteration with radiosurgery, early adverse effects of radiosurgery, late complication after AVM radiosurgery, and factors to be considered in making a recommendation for stereotactic radiosurgery for AVM Summary – Brain Metastases [*see pages 104 to 107 for full comment and evidence cited*] • Discusses the role of radiosurgery for brain metastases including	*consideration in the review process.* *No changes to Key Questions.*

Reviewer	Comment	Disposition
	retrospective studies showing support for SRS, local tumor control, survival, the role of SRS for multiple brain metastases, indications for radiosurgery, and a clinical decision making algorithm that includes tumor size and patient preference. Summary – Meningiomas [*see pages 107 to 108 for full comment and evidence cited*] • Discusses long-term outcomes of meningioma after radiosurgery, the use of radiosurgery for malignant meningioma, the use of radiosurgery with cavernous sinus meningiomas, and early complication of radiosurgery for meningiomas. Summary – SRS Thalamotomy for Tremor [*see page 109 for full comment and evidence cited*] • Discusses radiofrequency and radiosurgical thalamotomy to treat tremors Summary – Gliomas [*see pages 109 to 110 for full comment and evidence cited*] • Discusses the use of EBRT and Gamma Knife for patients with gliomas	
Virginia Mason Medical Center		
	Summary – Stereotactic Radiosurgery / Stereotactic Radiation Therapy [*see pages 111 to 117 for full comment and evidence cited*] • Discusses the evidence for the effectiveness, safety, modes of delivery. of stereotactic radiosurgery • Discusses the use of SRS for specific conditions such as AVMs, acoustic neuromas, meningiomas, brain metastases, nonfunctioning pituitary adenomas, malignant gliomas, and trigeminal neuralgia. • Discusses the effectiveness of stereotactic body radiation therapy • Discusses the uses for SBRT for specific conditions including small peripheral lung cancers, early stage prostate cancer, spine/vertebral body	*Thank you for your comment.* *All references were forwarded to TAC for consideration in the review process.* *No changes to Key Questions*

Reviewer	Comment	Disposition
	tumors, and liver tumors.	

PUBLIC COMMENTS – KEY QUESTIONS

AMERICAN ASSOCIATION OF NEUROLOGICAL SURGEONS
THOMAS A. MARSHALL, *Executive Director*
5550 Meadowbrook Drive
Rolling Meadows, IL 60008
Phone: 888-566-AANS
Fax: 847-378-0600
info@aans.org

President
MITCHEL S. BERGER, MD
San Francisco, California

American Association of Neurological Surgeons

CONGRESS OF NEUROLOGICAL SURGEONS
REGINA SHUPAK, *Acting Executive Director*
10 North Martingale Road, Suite 190
Schaumburg, IL 60173
Phone: 877-517-1CNS
FAX: 847-240-0804
info@1CNS.org

President
CHRISTOPHER E. WOLFLA, MD
Milwaukee, Wisconsin

July 2, 2012

Josh Morse, MPH
Program Director, Health Technology Assessment
Washington State Health Care Authority
P.O. Box 42712
Olympia, WA 98504-2712
E-Mail: Josh.Morse@hca.wa.gov

Subject: Revised Key Questions for Health Technology Assessment of Stereotactic Radiosurgery (SRS) and Stereotactic Body Radiotherapy (SBRT)

Dear Mr. Morse,

The American Association of Neurological Surgeons (AANS), and the Congress of Neurological Surgeons (CNS), would like to thank you and the Washington State Health Care Authority for the opportunity to provide comment on the revised technology assessment questions for the Washington State Health Care Authority Health Technology Clinical Committee consideration of Stereotactic Radiosurgery (SRS) and Stereotactic Body Radiotherapy (SBRT). The AANS and CNS have been actively involved in policy issues surrounding SRS and are eager to work with you to provide appropriate guidance and evidence assessment regarding the efficacy, safety, and cost effectiveness of SRS for selected patients with brain and spine disorders. Neurosurgeons have extensive experience and literature from over 40 years, since a neurosurgeon first introduced SRS care in the United States.

We are concerned that some of the key questions in the *"DRAFT Key Questions and Background Stereotactic Radiation Surgery and Stereotactic Body Radiation Therapy"* are very general and we are eager to provide more specific details in response to the draft technical assessment expected on July 6, 2012.

KQ1: What is the evidence of effectiveness for stereotactic radiation surgery (SRS) and stereotactic body radiation therapy compared to conventional external beam radiation therapy (EBRT) for the following patients:

a. Patients with central nervous system (CNS) tumors;

   AANS/CNS Comment: Stereotactic radiosurgery (SRS) has been shown to offer a high rate of tumor control and an excellent chance of neurological preservation for many patients with select primary central nervous system tumors, vascular malformations, and functional disorders. Levels of evidence range from Class II to Class V (references below).

b. Patients with non-central nervous system cancers?
   AANS/CNS Comment: The same is true for SRS for non-CNS tumors that have spread to the brain. In particular, SRS has been used Class I through Class V evidence for the safe and effective treatment of patients with brain metastases (references below).

WASHINGTON OFFICE
KATIE O. ORRICO, *Director*
725 Fifteenth Street, NW, Suite 500 Washington, DC 20005
Phone: 202-628-2072 Fax: 202-628-5264 E-mail: korrico@neurosurgery.org

KQ2: What are the potential harms of SRS and SBRT compared to conventional external beam radiation therapy (EBRT)? What is the incidence of these harms? Include consideration of progression of treatment in unnecessary or inappropriate ways.

AANS/CNS Comment: SRS and EBRT are forms of ionizing radiation, and share the potential for a similar range of side effects. In appropriately selected patients and with careful delivery of SRS, the incidence of serious and irreversible side effects for most indications is under 5%. When weighed against treatment alternatives for benign and malignant CNS tumors, functional disorders, and vascular malformations, the risks of SRS are typically lower than that of other options and certainly of progression or persistence of the CNS pathology. In particular for brain metastases and skull base tumors, SRS has been shown to offer a better chance of neurological and neurocognitive preservation than external beam radiotherapy (EBRT) or surgical resection for select cohorts of patients (Chang et al., 2009; Tooze et al., 2011; Ivan et al., 2011).

KQ3: What is the evidence that SRS and SBRT have differential efficacy or safety issues in sub populations? Including consideration of:

a. Gender

AANS/CNS Comment: There is no appreciable effect of gender on SRS outcomes (references below).

b. Age

AANS/CNS Comment: Age has been shown to be a factor in survival of brain metastasis patients after SRS. Age is an important factor in RPA, GPA, and disease specific GPA indices for brain metastases patient outcomes after SRS (Sperduto et al.., 2008; Andrews et al., 2004). For nonmalignant pathologies SRS indications, age can be a favorable prognostic factor for SRS outcomes compared to open surgery or EBRT (Regis et al., 2006; Williams et al., 2011; Dewas et al., 2011).

c. Site and type of cancer; and
d. Stage and grade of cancer

AANS/CNS Comment: Parts c. and d. of Key question 3 are more relevant to body SBRT, and are not considered a significant factor in the evidence of CNS disease.

e. Setting, provider characteristics, equipment, quality assurance standards and procedures.

AANS/CNS Comment: This is a difficult question to answer. In general, outcomes with SRS have not been shown to be device specific. However, they are likely related to SRS team experience, neurosurgeon's technique, and volume (Koga et al., 2011; Kondziolka et al., 1999).

KQ4: What is the evidence of cost and cost-effectiveness of SRS and SBRT compared to EBRT?

AANS/CNS Comment: When appropriately indicated, SRS has been found to be cost effective for patients with brain metastases, spinal metastases, and skull base tumors (Haley et al., 2011; Lal et al., 2012; Banerjee et al., 2008; Rutigliano et al., 1995; Park et al., 2011).

Again, thank you for this opportunity to comment and we look forward to the release of the draft report. If you have any questions, please feel free to contact us.

Sincerely,

Joseph Cheng, MD, Chair
AANS/CNS Joint Section Joint Section on Disorders of the Spine and Peripheral Nerves
joseph.cheng@vanderbilt.edu

Staff Contact:
Catherine Jeakle Hill
Senior Manager, Regulatory Affairs
AANS/CNS Washington Office
725 15th Street, NW, Suite 500
Washington, DC 20005
Phone: 202-446-2026
Fax: 202-628-5264
e-mail: chill@neurosurgery.org

References

1. Andrews DW, Scott CB, Sperduto PW, Flanders AE, Gaspar LE, Schell MC, Werner-Wasik M, Demas W, Ryu J, Bahary JP, Souhami L, Rotman M, Mehta MP, Curran WJ Jr. Whole brain radiation therapy with or without stereotactic radiosurgery boost for patients with one to three brain metastases: phase III results of the RTOG 9508 randomized trial. Lancet. 2004 May 22;363(9422):1665-72.
2. Banerjee R, Moriarty JP, Foote RL, Pollock BE. Comparison of the surgical and follow-up costs associated with microsurgical resection and stereotactic radiosurgery for vestibular schwannoma. J Neurosurg. 2008 Jun;108(6):1220-4.
3. Chang EL, Wefel JS, Hess KR, Allen PK, Lang FF, Kornguth DG, Arbuckle RB, Swint JM, Shiu AS, Maor MH, Meyers CA. Neurocognition in patients with brain metastases treated with radiosurgery or radiosurgery plus whole-brain irradiation: a randomized controlled trial. Lancet Oncol. 2009 Nov;10(11):1037-44.
4. Dewas S, Dewas-Vautravers C, Servent V, Mirabel X, Prevost B, Coche B, Castelain B, Nickers P, Lartigau E. Results and special considerations when treating elderly patients with CyberKnife®: a review of 345 cases. Crit Rev Oncol Hematol. 2011 Sep;79(3):308-14.
5. Haley ML, Gerszten PC, Heron DE, Chang YF, Atteberry DS, Burton SA. Efficacy and cost-effectiveness analysis of external beam and stereotactic body radiation therapy in the treatment of spine metastases: a matched-pair analysis. J Neurosurg Spine. 2011 Apr;14(4):537-42.
6. Ivan ME, Sughrue ME, Clark AJ, Kane AJ, Aranda D, Barani IJ, Parsa AT. A meta-analysis of tumor control rates and treatment-related morbidity for patients with glomus jugulare tumors. J Neurosurg. 2011 May;114(5):1299-305.
7. Koga T, Shin M, Maruyama K, Kurita H, Kawamoto S, Saito N. Contribution of technological progress, inter-operator difference and experience of operators in Gamma Knife radiosurgery for arteriovenous malformation. Acta Neurochir (Wien). 2011 Apr;153(4):879-82.
8. Kondziolka D, Levy EI, Niranjan A, Flickinger JC, Lunsford LD. Long-term outcomes after meningioma radiosurgery: physician and patient perspectives. J Neurosurg. 1999 Jul;91(1):44-50.

9. Lal LS, Byfield SD, Chang EL, Franzini L, Miller LA, Arbuckle R, Reasonda L, Feng C, Adamus A, Swint JM. Cost-effectiveness analysis of a randomized study comparing radiosurgery with radiosurgery and whole brain radiation therapy in patients with 1 to 3 brain metastases. Am J Clin Oncol. 2012 Feb;35(1):45-50.
10. Park KJ, Niranjan A, Kondziolka D, Kano H, Castillo P, Matchett JC, Flickinger JC, Lunsford LD. Combining brain diagnosis and therapy in a single strategy: the safety, reliability, and cost implications using same-day versus separate-day stereotactic procedures. Stereotact Funct Neurosurg. 2011;89(6):346-56.
11. Régis J, Metellus P, Hayashi M, Roussel P, Donnet A, Bille-Turc F. Prospective controlled trial of gamma knife surgery for essential trigeminal neuralgia. J Neurosurg. 2006 Jun;104(6):913-24.
12. Rutigliano MJ, Lunsford LD, Kondziolka D, Strauss MJ, Khanna V, Green M. The cost effectiveness of stereotactic radiosurgery versus surgical resection in the treatment of solitary metastatic brain tumors. Neurosurgery. 1995 Sep;37(3):445-53; discussion 453-5.
13. Sperduto PW, Berkey B, Gaspar LE, Mehta M, Curran W. A new prognostic index and comparison to three other indices for patients with brain metastases: an analysis of 1,960 patients in the RTOG database. Int J Radiat Oncol Biol Phys. 2008 Feb 1;70(2):510-4.
14. Tooze A, Hiles CL, Sheehan JP. Neurocognitive Changes in Pituitary Adenoma Patients After Gamma Knife Radiosurgery: A Preliminary Study. World Neurosurg. 2011 Nov 7
15. Williams BJ, Yen CP, Starke RM, Basina B, Nguyen J, Rainey J, Sherman JH, Schlesinger D, Sheehan JP. Gamma Knife surgery for parasellar meningiomas: long-term results including complications, predictive factors, and progression-free survival. J Neurosurg. 2011 Jun;114(6):1571-7.

From: Jason Mckitrick
To: HCA ST Health Tech Assessment Prog
Cc: Andrew Woods; Morse, Josiah (HCA)
Subject: ACRO Comment Letter to Mr. Josh Morse (WSHCA HTA) Regarding Stereotactic Radiation Surgery and Stereotactic Body Radiation Therapy, and Intensity Modulated Radiation Therapy Technology Assessment Key Questions
Date: Tuesday, March 06, 2012 12:26:38 PM
Attachments: Comment Letter to Mr. Josh Morse (WSHCA Health Technology Assessment) 3-6-2012.pdf
Importance: High

Dear Mr. Morse,

Attached please find the comment letter submitted on behalf of the American College of Radiation Oncology for **Stereotactic Radiation Surgery, Stereotactic Body Radiation Therapy, and Intensity Modulated Radiation Therapy Technology Assessment Key Questions**.

Please let me know if you have any questions.

Thank you.
Jason S. McKitrick
Liberty Partners Group
1050 K Street, NW
Suite 315
Washington, D.C. 20001
(202) 442-3754 (Direct)
(703) 203-1455 (Cell)
jmckitrick@libertypartnersgroup.com

ACRO
American College of
RADIATION ONCOLOGY
Integrating Science and Technology into Patient Care
5272 River Road | Suite 630 | Bethesda, MD 20816 | 301.718.6515 | Fax 301.656.0989 | Email info@acro.org

March 6, 2012

Josh Morse, MPH
Program Director
Washington State Health Care Authority
Health Technology Assessment
P.O. Box 42712
Olympia, Washington 98504-2712

Re: Stereotactic Radiation Surgery, Stereotactic Body Radiation Therapy, and Intensity Modulated Radiation Therapy Technology Assessment Key Questions

Dear Mr. Morse:

The American College of Radiation Oncology (ACRO) appreciates the opportunity to offer its comments to the Washington State Health Care Authority (WSHCA) draft Technology Assessment Key Questions on the topics of Stereotactic Radiation Surgery (SRS), Stereotactic Body Radiation Therapy (SBRT), and Intensity Modulated Radiation Therapy (IMRT). ACRO represents radiation oncologists in the socioeconomic and political arenas. With a current membership of approximately 1,000, ACRO is dedicated to fostering radiation oncology education and science; improving patient care services; studying the socioeconomic aspects of the practice of radiation oncology; and encouraging education in radiation oncology.

ACRO received notice of the key questions on February 22, 2012 and we understand the deadline for comments is March 6, 2012. Full and appropriate comments to these questions requires months of preparation. Unfortunately, the short time frame within which to answer these questions does not allow for a direct detailed, and fully documented response.

However, ACRO can provide the following more general comments within the allotted time frame:

- The issues surrounding choices of radiation-emitting modalities, (e.g. IMRT) are usually based on physical (physics) data and empirical observations, rather than randomized controlled clinical trials. The US Food and Drug Administration does not require such Level I data for device approval, and once devices are approved and marketed, there is little ability to complete those trials. Proposals to payers to assist in implementing trials, as with *Coverage with Evidence Development*, have been shunned, and patients (and IRBs) will rarely if ever accept randomization to trials where the only presumed differences are related to morbidity.

- As a delivery system widely available since 1998 (when the CPT© codes and RVUs were established), IMRT has been shown in every and innumerable instances measured, to reduce morbidity to the adjacent organs at risk in proximity to target tumor volumes. In instances where this morbidity-reduction has been used to permit an increase in radiation dose to tumors (e.g. prostate, head/neck, central nervous system, liver, etc.), a concomitant increase in local control has also been demonstrated. Regrettably, in radiation oncology, unlike drug development, since long-term control or cure is often the determinant end-point, years may be required to define the parameters, so physical data and morbidity reduction MUST be used as surrogates. Randomized device trials also require a large installed base of the devices, which is also impractical. Alternatively, drug studies may provide actionable (albeit often non-clinically relevant) information in weeks to months, at minimal cost, since the primary end-points are more often simply measurement of some surrogate tumor marker or interval free from progression..

- There is clear and increasing evidence that in certain circumstances, SBRT and SRS may be equivalent and/or preferable to conventional fractionated and protracted radiation. SBRT and SRS, unlike IMRT, relate to "biology" and not "technology," in that they merely represent the delivery of high-dose, short-course radiation (5 or fewer treatments, rather than daily, protracted, lower-dose, longer-course therapies). Evidence mounts that numerous sites, including brain, spinal cord, liver, and lung, as well as other emerging indications, are appropriately treated by SRS (for central nervous system) and SBRT (for non-central nervous system).

We understand that the American Society for Radiation Oncology (ASTRO) has included its own model coverage policies on SRS, SBRT and IMRT for your review that outline specific technology of each treatment, clinical indications, coding considerations and references. ACRO supports your review of these materials and their conclusions. We also are aware that physicians with the Swedish Medical Center are submitting information regarding studies that have been performed relating to SRS, SBRT and IMRT. We would encourage the committee to review these in detail.

We appreciate your consideration of our comments and look forward to reviewing the WSHCA's draft report. Should you have any questions, please contact Jason McKitrick, ACRO Economics Committee consultant, at (202) 442-3754.

Sincerely,



Sheila Rege, MD, FASTRO, FACRO
Chair, Economics Committee
American College of Radiation Oncology
5272 River Road
Suite 630
Bethesda, Maryland 20816

From: Marsha Kaufman
To: HCA ST Health Tech Assessment Prog
Cc: Patton, Gregory A (Gregory.Patton@USOncology.com); Michael Dzeda; Thomas Eichler, M.D.
(thomas.eichler@hcahealthcare.com); Joel Cherlow, M.D., Ph.D. (jcherlow@memorialcare.org); Najeeb
Mohideen; Brian Kavanagh, M.D. (brian.kavanagh@uchsc.edu); Daneen Grooms; Crystal Carter
Subject: ASTRO comment letter - SRS, SBRT and IMRT Key Questions
Date: Monday, March 05, 2012 9:43:14 AM
Attachments: SRS-SBRT-IMRT KeyQCommentLtr FINAL3-5-12.pdf
SRSModelPolicyFINAL 7-25-11.pdf
SBRT2010 FINAL 11-17-10.pdf
ASTRO IMRT Model FINAL 05.09.07-with disclaimer.pdf

Good afternoon Mr. Morse. Please find attached the American Society for Radiation Oncology's (ASTRO) comment letter on the key questions related to the technologies of Stereotactic Radiation Surgery (SRS), Stereotactic Body Radiation Therapy (SBRT) and Intensity Modulated RadiationTherapy (IMRT). As indicated in our letter, attached are copies of the ASTRO Model Policies on SRS, SBRT and IMRT.

Thank you for your consideration and please do not hesitate to contact me should you have any questions.

Regards,
Marsha Kaufman
~~~
~~~

ASTRO

TARGETING CANCER CARE

March 5, 2012

Josh Morse, MPH
Program Director
Washington State Health Care Authority
Health Technology Assessment
P.O. Box 42712
Olympia, WA 98504-2712

BY ELECTRONIC SUBMISSION to shtap@hca.wa.gov

Re: Stereotactic Radiation Surgery and Stereotactic Body Radiation Therapy, and Intensity Modulated Radiation Therapy Technology Assessment Key Questions

Dear Mr. Morse:

The American Society for Radiation Oncology (ASTRO), the largest radiation oncology society in the world representing more than 10,000 members who specialize in treating patients with radiation therapies, appreciates the opportunity to comment on the Washington State Health Care Authority draft Technology Assessment Key Questions on the topics of Stereotactic Radiosurgery (SRS) and Stereotactic Body Radiation Therapy (SBRT), and Intensity Modulated Radiation Therapy (IMRT). ASTRO received notice of the Key Questions on February 22, 2012 and we understand the deadline for comments is March 6, 2012. The Key Questions posed for SRS, SBRT and IMRT are extensive and ask for a level of detail that we cannot produce within the time frame allotted. The information requested for all three technologies, specifically comparisons to external beam radiation therapy (benefits and harms), and differential efficacy or safety issues in subpopulations including consideration of gender, age, site and type of cancer, stage and grade of cancer and setting, provider characteristics, equipment, quality assurance standards and procedures, constitutes a full research study that would take many months to produce. While ASTRO believes these technologies offer clear benefits to many of the cancer patients our members treat, we would require significantly more time to adequately address the important issues raised in the Key Questions.

ASTRO plans on reviewing the draft report that will be produced as a result of the public comment period and we look forward to reviewing this report in early July. We have noted that the Health Technology Clinical Committee that will be reviewing the technology assessment reports and making coverage decisions does not include a radiation oncologist and we strongly recommend that a radiation oncologist be added to this committee.

In anticipation of the more detailed comments that we will submit in response to the draft report, we offer a general observation relating to the fundamental basis of some of our positions about IMRT in particular. During the past two decades, an abundant number of clinical studies have characterized the relationship between the dose given to various normal tissues using 3D EBRT

AMERICAN SOCIETY FOR RADIATION ONCOLOGY
8280 WILLOW OAKS CORPORATE DRIVE • SUITE 500 • FAIRFAX, VA 22031 • 800.962.7876 • 703.502.1550 • FAX: 703.502.7852
www.astro.org • www.rtanswers.org

ASTRO Washington Health Care Authority Technology Assessment Letter
Page 2
March 5, 2012

and the risk of toxicity to those tissues. There are recognized dose thresholds known to relate to the risk of toxicity for bowel, bladder, spinal cord, and other important organs. Whereas IMRT offers the capacity to avoid exceeding those recognized thresholds for toxicity, it is considered an appropriate standard for numerous indications as a result of this property. The field of radiation oncology has not considered it ethical or resource-efficient to conduct head-to-head comparisons of 3D EBRT vs. IMRT in all settings where a clear improvement in a surrogate measure of toxicity risk is easily demonstrated.

We have included ASTRO's model coverage policies on SRS, SBRT and IMRT for your review that outline the specific technology of each treatment, clinical indications, coding considerations and references.

We appreciate your consideration of this material and look forward to the draft report. Should you have any questions please contact Marsha Kaufman, Director of Health Policy, at 703-839-7374 or marshak@astro.org.

Sincerely,

Gregory Patton, MD
Chair, Regulatory Committee

Michael Dzeda, MD
Vice Chair, Regulatory Committee

Enclosure: ASTRO SRS Model Policy
ASTRO SBRT Model Policy
ASTRO IMRT Model Policy

cc: Thomas Eichler, MD
Joel Cherlow, MD, PhD
Najeeb Mohideen, MD
Brian Kavanagh, MD, MPH

From: jrberry719@aol.com
To: HCA ST Health Tech Assessment Prog; JRBerry719@aol.com
Subject: Prostate Cancer SRS/SBRT patient information
Date: Saturday, March 03, 2012 5:28:09 PM
Attachments: Cyberknife testimony (Autosaved).docx

My husband is "down under" traveling for a month, so he asked me to share our story with his journey through Prostate Cancer. I will join him next week. We believe it is important for anyone that is making decisions regarding treatment to hear the journey of "real folks" who have had treatment.

If there is any other information needed, I can be texted at 206 793 3200 or will be back in the country 4/3.

Thanks for your kind attention.

Jeanne R. Berry

March, 2012

To Whom It May Concern,

As the Mayor of a town in Washington State for 8 years, I know the importance of our government getting information from the public about decisions that are being faced. I hope to share my journey to let you know why SRS/SBRT needs to be supported by my government. Usually comments from the end users (no pun intended) are important for decision makers.

Last fall, my husband of 37 years needed to have ankle replacement surgery. During his presurgery checkup, he was given a complete physical review. At 68 years of age, he was in excellent health, and has been very active in his retirement of five years, though he had an orthopedic challenge.

The physical performed found his PSA abnormal, so he was referred to his Urologist, who immediately performed a biopsy. We soon got some difficult news ,my husband had Prostate Cancer, his Gleeson score was six, yet was scheduled for the ankle replacement surgery the very next week. We learned that his cancer was slow growing, so while his ankle was healing for 5 months, we turned our energies turned to understanding all we could about Prostate cancer.

For 62 years, I was a WA resident, now retired and living in central Oregon , so being far from major medical support was a challenge. We researched the entire West Coast, for information about Prostate Cancer treatments. Our myriad layers of concern and confusion were significant, but information about cancer treatments was essential.

There is very little that frighten me more that “your husband has cancer”, followed by the words “right now all we can do is watchful waiting”. For the next few months healing from ankle replacement, my highly educated scientist husband began a research inquiry process that was second to none. The side effects he studied about Prostate Cancer treatments involving surgery, proton therapy, cryogenic therapy, and external beam, and IMRT were clearly going to limit the life style that we had shared. We could not find any data on SRS/SBRT on the internet. Bear in mind, husband is a man who had snowboarded one million vertical miles in 70 trips to the mountains the previous winter. Incontinence, rectal bleeding, lack of sexual function were certainly not in his retirement plan. We are folks in charge of our health, and take all precautions to enjoy a long and healthy retirement. My knowledge of “Man Land” increased exponentially.

As his ankle healed, my husband continued his research. We flew to Seattle and interviewed the physicians at Swedish Hospital, we interviewed in depth with the team at Loma Linda in CA, and other oncologists and urologist and Oncologists at U of WA hospital. We talked with Urologists in Portland, at Stanford, and went to myriad websites worldwide.

Then, a friend of his mentioned that he had completed treatment with Cyberknife (or SRS/SBRT) for Prostate Cancer in Seattle. My husband poured over all the studies and research on Cyberknife (SRS/SBRT), and found the five days of treatment to be compelling, and so much more humane. Also, the accuracy this form of treatment was so clearly evident with all the data and literature, and the ability

to correct the appropriate direction of radiation at the cancer in real time seemed much more appropriate than other methods that may miss the area needed to get rid of cancer. If we had gone to CA for their protocol at Loma Linda (proton therapy), we would have had to move to California, and two months living in another state is challenging to a fixed income, so we ruled out Loma Linda. Our primary oncologist walked us through the entire process, and is maintaining health checkups in central Oregon.

We decided to undertake the 5 day, one hour treatments with the most positive outcomes and that was at Swedish Hospital in Seattle. Finally, we had clear direction, and renewed hope that his cancer might be eliminated.

Our trip to Seattle, in late January 2011, for the Cyberknife SRS/SBRT treatment, was exactly as outlined by the Swedish Oncology team. My husband went through the process with **no** unexpected side effects from the Prostate Cancer treatment, though he had a short time (10 day) challenge of urinary flow, which did not affect his daily activities, post procedure. He experienced no sexual challenges, or rectal problems. In a short time, he was on the golf course and at the gym working out, doing spin classes and weight lifting 10 times a week. In the past year, his PSA is back down to a low level, and he has had absolutely no complications.

We have been so impressed with the SRS/SBRT treatment process, that we invited his Oncologis to come to Central Oregon to speak about the research to interested people . Thinking that a half dozen folks would appear, we were surprised to have 100 attend on a Thursday night with only word of mouth advertising. The men and women were deeply interested in the Cyberknife SRS/SBRT therapy. Attending this seminar were many physicians, health care professional s and just normal folks trying to understand treatment options for Prostate Cancer, which are complex and highly confusing. Prostate cancer is on the minds of so many folks we know, and my husband is asked weekly about his treatment process.

In my mind, limiting access to Cyberknife SRS/SBRT due to government intervention is terribly short sighted, and would be very economically bad. Why should anyone be afforded less than the best therapy? My husband inquired about how much each therapy would cost, and Cyberknife SRS/SBRT was the cheapest, least invasive and quickest process, so that is what we chose this treatment. If an arbitrary decision to take away this absolutely positive procedure was enacted, we still would have had the SRS/SBRT treatment that we underwent. The benefits are excellent, the outcome positive. To us, all other choices were archaic and outdated in comparison. After supporting our government with both of us working and paying into the Medicare system for five decades, it would have been criminal to be denied access to appropriate treatment. To have our government fund much more expensive machinery and process is exactly the wrong direction for the leadership of Medicare to follow, especially in a 10 state area, where it has been supported by Medicare funding previously. My analogy would be “I have a smart phone that makes life work very well for me…why should I accept the “BRICK” as a phone because a government agency made an arbitrary administrative decision”? We need the support of Medicare for prostate cancer. Thank you for your kind attention, Jeanne R. Berry

From: Carlson, Thomas MD
To: HCA ST Health Tech Assessment Prog
Subject: Public Comment for: Stereotactic Radiation Surgery and Stereotactic Body Radiation Therapy
Date: Monday, March 05, 2012 11:22:53 AM

Members of the Health Technology Committee,

I appreciate the work you do in recognizing the need to evaluate new technologies and the implementation of these technologies in the health care sector.
I am concerned with respect to the path we have been going down regarding the complexity of reimbursement evaluation. We seem to be reimbursing physicians based on the tools they are using to accomplish a task as opposed to the task itself. In the case of IMRT, Stereotactic Radiosurgery (in the brain or body) or brachytherapy, we are reimbursing based on the tool. Do we reimburse a surgeon for using one scalpel blade over another? No. The surgeon chooses what's most appropriate for the situation and is paid for the job. I believe a tremendous amount of waste could be removed from the system if a case rate reimbursement model was initiated.

Thomas Carlson, MD
Department of Radiation Oncology
Wenatchee Valley Medical Center

This e-mail message, including any attachments, is for the sole use of the intended recipient(s) and may contain confidential or privileged information. Any unauthorized review, use, disclosure or distribution is prohibited. If you are not the intended recipient, please contact the sender by reply e-mail and destroy the message.

SUBJECT: Comments regarding SRS and SBRT
FROM: John.Rieke@multicare.org
TO: shtap@hca.wa.gov
CC: John.Rieke@multicare.org
SENT: Mon 05 Mar 2012 22:30:54 PST
EXPIRES: Fri 04 May 2012 22:30:54 PDT

I am pleased to offer these comments regarding SBRT and SRS per your request. A letter is attached. Please feelfree to call with questions anytime; my office phone is 253-403-4994, and my cell phone is 206-920-3469.

I was asked to review the material you received from Dr. Barnett of TIROG in Seattle regarding IMRT. I support the submittal completely. I think it represents mainstream thinking of radiation oncologists across the state.

I understand there will be a chance to discuss your report due out later this year, at a meeting September 21, 2012. Please add me to relevant mailing list. I have been asked to represent the ASTRO, our national radiation oncology/biology/physics professional society in your proceedings.

Best wishes,

John W. Rieke, MD, FACR
Medical Director
MultiCare Regional Cancer Center
Tacoma, WA

MULTICARE'S SHARED VALUES | Respect | Integrity | Stewardship | Excellence | Collaboration | Kindness

Mailgate1.multicare.org made the following annotations

NOTICE: This e-mail and the attachments hereto, if any, may contain privileged and/or confidential information. It is intended only for use by the named addressee(s). If you are not the intended recipient of this e-mail, you are hereby notified that any examination, distribution or copying of this e-mail and the attachments hereto, if any, is strictly prohibited. If you have received this transmission in error, please immediately notify the sender by email or telephone and permanently delete this e-mail and the attachments hereto, if any, and destroy any printout thereof. MultiCare Health System, Tacoma, WA 98415 (253) 403-1000.

Board of Director Member Centers

Georgetown University Hospital

Stanford Hospital and Clinics

CyberKnife Center of Miami

The START Center for Cancer Care

CyberKnife Centers of San Diego

Community Regional Medical Center

MultiCare Regional Cancer Center

CyberKnife Centers of Tampa Bay

CyberKnife Center of South Florida, Stuart

US Radiosurgery

Member Centers

Advocate Christ Medical Center

Baylor Healthcare System

Center for Advanced Radiotherapy and CyberKnife Radiosurgery

CyberKnife Center of Chicago

CyberKnife Center of South Florida, Wellington

CyberKnife Center of Texas

J.D. and Lorraine Nicewonder Cancer Center

Oklahoma CyberKnife

Philadelphia CyberKnife

Reno CyberKnife

The CyberKnife Service of BroMenn Healthcare at The Community Cancer Center

Waukesha Memorial Hospital

Coastal CyberKnife and Radiation Oncology

Colorado CyberKnife

CyberKnife of California, Vista

Mitchell Cancer Institute

Southwest Radiation Oncology

University Hospitals Case Medical Center

Franklin Square Hospital Center

Corporate Members

Accuray Incorporated

Alliance Radiosurgery

Architection

CYBERKNIFE®
CKC
COALITION

March 6, 2012

The CyberKnife© Coalition (CKC) writes in response to the call for public comments on the Washington State Health Care Authority, HTA Program, "Stereotactic Radiation Surgery and Stereotactic Body Radiation Therapy" Health Technology Assessment.

About the CyberKnife Coalition

Formed in 2003 and incorporated in 2005, the CKC is a non-profit association of hospitals and freestanding centers across the United States committed to improving patient access to image-guided robotic stereotactic radiosurgery as a treatment option for cancer patients. In addition to the numerous community hospitals and clinics that belong to the CKC, our membership also includes major academic institutions and premiere cancer centers such as Stanford Hospital and Clinics, Georgetown University Medical Center, Baylor Healthcare System, and University Hospitals-Case Medical Center. All of our members offer image-guided robotic stereotactic radiosurgery to treat malignant and benign tumors and other select disorders with high dose, precisely targeted radiation.

Since 2003, the CKC has supported efforts to collect and develop data demonstrating the therapeutic, quality of life, and economic benefits of CyberKnife treatments and has worked collaboratively with payers to ensure appropriate patient access. Over 100,000 patients worldwide have been treated with CyberKnife since it received approval in 1996 in Japan and in 1999 from the United States Food and Drug Administration (FDA).

Background information:

For more than 30 years, traditional radiosurgery (e.g. Gamma Knife) has been used primarily to destroy brain tumors. While the Gamma Knife is an extremely effective neurosurgery device, it is limited in its clinical application to only treat intracranial and upper spinal lesions. This limitation is due to its inability to track for motion, which necessitated application of a rigid head frame screwed into the patient's skull for immobilization.

The CyberKnife Robotic Radiosurgery System built on the principles of Gamma Knife radiosurgery and was developed to extend radiosurgical treatments to lesions and tumors anywhere in the body. When used to treat intracranial and upper spinal lesions, the CyberKnife and Gamma Knife are similar in that they deliver non-coplanar treatment – meaning they are able to deliver beams from multiple angles to converge or "cross fire" on tumors and ablate them. Both are excellent tools for delivering single fraction radiosurgical treatments. However, unlike the Gamma Knife which is only able to deliver treatment in a single session, or "fraction", to tumors inside the skull or upper spine, the CyberKnife is able to deliver treatment over multiple sessions and can treat tumors throughout the body. This makes the CyberKnife a more useful device in terms of clinical application and utility.

info@ckcoalition.org

Whether used for intracranial or extracranial radiosurgery, the CyberKnife differs from other linear accelerators in that it is the only **robotic** radiosurgery system in existence today. The use of the word "robotic" in "image-guided robotic stereotactic radiosurgery" refers to a non-gantry based[3] autonomous device that has the ability to sense its own environment, evaluate it, and take independent action based on the results of its analysis. The CyberKnife does this by combining a compact linear accelerator, mounted on a robotic arm, with a high speed computer to process *continuous* X-ray images and then uses that information to *continuously* respond to changes in tumor and patient movement by correcting its position and then delivering the radiation to the new target location. Due to its robotic mobility and real-time image guidance capabilities, the CyberKnife System is able ensure the safe and extremely accurate delivery of hundreds of radiation beams, delivered from as many as 1,600 unique angles. In other words, the treatment is multi-dimensionally delivered from any point in space based on information it obtains on an ongoing basis. All of these characteristics result in precise delivery of radiation with little exposure to healthy surrounding tissue.

Treatment with CyberKnife is non-invasive, does not require anesthesia, and, unlike other forms of external beam radiation treatment, is a potentially curative treatment option for operable and inoperable patients alike. Due to its pinpoint treatment accuracy, CyberKnife can safely deliver extremely high doses of radiation to the tumor, facilitating a significantly shorter course of treatment than other forms of radiation treatment, while sparing surrounding healthy tissue. For cancer patients who cannot be cured and for whom prolonged courses of radiation treatment are not feasible or practical, the CyberKnife may be used to improve local control rates and quality of life.

In contrast, *non-robotic*, gantry-based systems (e.g. C-arm systems) can be used to deliver radiosurgical doses, but can only deliver radiation along a single plane. This is due to their fixed position that allows the linear accelerator to only be tilted left or right on a fixed pivot. If image-guidance is used, it is used to guide patient set-up but is not generally done during treatment. If it is used during treatment (e.g. through the use of beacons) a therapist has to stop treatment as the targeted area moves away from the radiation beam and reposition the patient, which is an inefficient approach compared to robotic radiosurgery. For patients whose tumors move widely, a therapist might program a larger threshold for movement (e.g. tumor moving from 2 mm to 4 cm) to limit the number of times the treatment must be stopped to reposition the patient (otherwise the treatment would be very prolonged). This results in less accurate delivery of the radiation to the target and increases the exposure to healthy surrounding tissue and critical structures.

From a patient perspective, the CyberKnife provides an option for treatment that is significantly shorter (≤ 5 treatments compared to 20-45 treatments depending on the indication), thus allowing patients to spend more time with family, with less interruption on work schedules, and resume their normal daily lives as quickly as possible.

Key questions

KQ1: What is the evidence of effectiveness for stereotactic radiation surgery (SRS) and stereotactic body radiation therapy compared to conventional external beam radiation therapy (EBRT) for the following patients:

a. Patients with central nervous system (CNS) tumors?

[3] CMS Robotic Definition: Transmittal 1139 of the CMS Manual System Pub 100-04 Medicare Claims Processing (12/22/2006)

b. Patients with non-central nervous system cancers?

a. CyberKnife is commonly used to treat patients diagnosed with well demarcated central nervous system (CNS) tumors, generally 5 cm or less in volume – in both the brain and in the spine. Examples of the types of tumors appropriate for CyberKnife radiosurgery include primary central nervous system malignancies, primary and secondary tumors involving the brain or spine parenchyma, meninges/dura, meningiomas, pituitary adenomas, pineal cytomas, cranial arteriovenous malformations, hemangiomas, and movement disorders (e.g. essential tremor) that are refractory to conventional therapy, including trigeminal neuralgia. CyberKnife is also extremely well suited to treat tumors that require "fractionated treatment" (dividing the dose into two or more treatment sessions) such as those located near the optic chasm or inner ear which benefit from a more gentle approach than what can be delivered via the highly destructive single session SRS of the Gamma Knife. A fractionated approach, using the CyberKnife to treat acoustic neuromas and tumors around the optic chasm, is extremely important for the preservation of hearing and sight. Clinical data have demonstrated a substantial benefit to patients using this approach.[4]

External beam radiation therapy (EBRT) is appropriate for the treatment of different patient population including patients with widespread disease and ill defined tumors with microscopic extension. Such as patients are not candidates for SRS and are typically treated with whole brain irradiation. Therefore it is not appropriate to compare SRS with EBRT for most indications as the patient populations are different. As we have pointed out, because CyberKnife and EBRT are used to treat different types of brain tumors, it is difficult to produce a true "apples to apples" comparison for intracranial tumors. For extracranial, spinal tumors, however, data do exist since prior the advent of CyberKnife, radiosurgery was not physically possible in this patient population due to limitations of the rigid frame that was affixed to patient's skulls for Gamma Knife radiosurgery.

The table below shows comparative data of CyberKnife SRS for spinal tumors vs. EBRT. As the table illustrates, significant clinical benefit is achieved with CyberKnife radiosurgery for all three measures of local control, acute toxicity, and survival.

According to Martin et al (2010)[5], conventional EBRT is used in the management of spinal metastases, for local control, palliation of pain, and treatment of spinal cord compression. However, the EBRT prescribed doses are limited by radiation tolerance of the spinal cord and spinal nerves. The steep dose falloff seen with CyberKnife SRS allows the delivery of a higher, more effective cell killing dose to the tumor, while staying within cord tolerance. Compared to EBRT, CyberKnife treatment results in significant improvements in long-term tumor control, acute toxicity, and survival (noted in table below). CyberKnife is also an excellent tool for the management of debilitating spinal pain.

4 Sources:
Bianciotto C, Shields CL, Lally SE, et al. CyberKnife radiosurgery for the treatment of intraocular and periocular lymphoma. Arch Ophthalmol 2010;128(12):1561-1567.
Zorlu F, Selek U, Kiratli. Initial results of fractionated CyberKnife radiosurgery for uveal melanoma. J Neuro Oncol 2009;94:111-117.
Adler JR, Gibbs IC, Puataweepong P, et al. Visual field preservation after multisession CyberKnife radiosurgery for perioptic lesions. Neurosurgery 2008;62:733-743.
5 Martin A & Gaya A. Stereotactic body radiotherapy: a review. Clin Oncol 2010;22(3):157-172.

Gerszten PC, Burton SA, Ozhasoglu C, et al. Radiosurgery for spinal metastases: clinical experience in 500 cases from a single institution. Spine 2007;32:193-199. **Comparison of Conventional EBRT vs. CyberKnife Clinical Outcomes for Spine**[6]		
Conventional EBRT		***CyberKnife***
Local control	65%	92-100%
Acute toxicity	56%	39%
2-year survival	17%	56%
Long-term pain relief	N/A	86%

b. While the CyberKnife has been used interchangeably by many neurosurgeons and radiation oncologists for years to perform SRS on intracranial tumors, it is the unique motion management, tracking, and real-time adjustment capabilities that gave rise to the adoption of CyberKnife radiosurgery in 2001 for the treatment of extracranial tumors beyond those in the spine. This is because CyberKnife was, and still remains, the only technology that can compensate for motion (e.g., breathing, digestion, patient movement, peristalsis, etc.) and adjust the beam during treatment, always following the target. It is no accident that for many clinical indications (e.g. prostate) the CyberKnife is used virtually exclusively, as it can deliver high doses of radiation (SBRT) and avoid extremely sensitive tissues and organs, (e.g. rectum, and bladder) reducing toxicity and improving outcomes. Below we will highlight the evidence of CyberKnife SBRT compared to conventional EBRT for extracranial tumors.

Non-small cell lung cancer

SBRT is well accepted for the treatment of non-small cell lung cancer (NSCLC), which biologically has been shown to respond better to hypofractionated treatment (e.g. larger doses in fewer fractions) than conventionally fractionated therapy (EBRT). Because CyberKnife SBRT can deliver hundreds of radiation beams while continuously tracking and compensating for respiratory motion (up to 4 cm), it is able to safely deliver ablative doses to regions of the lung located next to critical organs including the spinal cord, left ventricle, esophagus, main bronchus, trachea, and aorta. Conventional EBRT has been used for inoperable tumors, in patients who refuse surgery, or in patients (due to comorbid conditions) are not surgical candidates. However, the total dose is limited by lung tolerance for peripheral tumors, and mediastinal tolerance for central tumors[7]. SBRT has improved local control and survival rates for these patients compared to conventional EBRT. CyberKnife provides clinicians with an enhanced ability to deliver highly conformal treatments and dose escalate, to achieve maximum cell killing effect in the tumor while avoiding critical structures. The ability of the CyberKnife to track and adjust for motion during treatment allows clinicians to safely and effectively treat extremely sick patients with many comborid conditions such as emphysema, and COPD who may have difficulty holding their breath during treatment, which is required for all other devices. The table below highlights the improved clinical outcomes of CyberKnife SBRT compared to conventional EBRT for non-small cell lung cancer.

6 Sources:
Gagnon GJ, Nasr NM, Liao JJ, et al. Treatment of Spinal Tumors Using CyberKnife Fractionated Stereotactic Radiosurgery: Pain and Quality-of-Life Assessment after Treatment in 200 Patients. Neurosurg 2009;64(2)1-10.
Sahgal A, Ames C, Chou D, et al. Stereotactic body radiotherapy is effective salvage therapy for patients with prior radiation of spinal metastases. Int J Radiat Oncol Biol Phys 2009;74:723-731.
Gerszten PC, Burton SA, Ozhasoglu C, et al. Radiosurgery for spinal metastases: clinical experience in 500 cases from a single institution. Spine 2007;32:193-199.

7 Martin A & Gaya A. Stereotactic body radiotherapy: a review. Clin Oncol 2010;22(3):157-172.

Comparison of Conventional EBRT vs. CyberKnife Clinical Outcomes for Non-Small Cell Lung[8]		
	Conventional EBRT	***SBRT***
5-year local control	<50%	73-92%
5-year survival	10-30%	63-72%
Late toxicity ≥ grade 3	17%	5-9%

Liver Cancer

Radiation dosing to healthy liver tissue for the treatment of liver cancer can cause radiation induced liver disease (RILD). Unfortunately, the treatment options for RILD are limited, and in severe cases, liver failure and death can occur. CyberKnife SBRT is widely used for patients who are not surgical candidates or cannot be treated with other methods. Given the shortened life expectancy of patients with metastatic liver cancer, CyberKnife SBRT offers a more patient friendly option – CyberKnife SBRT is 3-5 treatments versus 20-30 treatments for conventional EBRT. CyberKnife SBRT provides patients with liver metastases an option that nearly doubles survival time, drastically decreases toxicity, and greatly improves quality of life. The shorter treatment time of CyberKnife SBRT for these incredibly sick patients allows them to avoid weeks of travel back and forth to the hospital (required for conventional treatment), and avoid additional financial hardship (e.g. lost wages, gas, and sometimes lodging expenses). For the Medicaid population, in particular, with limited means, these are not insignificant issues. The reduced treatment time may also have a positive impact on treatment compliance.

Comparison of Conventional EBRT vs. CyberKnife Clinical Outcomes for Liver Metastases[9]		
	Conventional EBRT	***CyberKnife***
Median survival	11-15 months	10-25 months
Late toxicity ≥ grade 3	30%	0-4%

[8] Sources:
van der Voort van Zyp NC, Prevost JB, van der Holt B, et al. Quality of life after stereotactic radiotherapy for stage I non-small-cell lung cancer. Int J Radiat Oncol Biol Phys 2010;77:31-37.
Collins BT, Vahdat S, Erickson K, et al. Radical cyberknife radiosurgery with tumor tracking: an effective treatment for inoperable small peripheral stage I non-small cell lung cancer. J Hematol Oncol 2009;2:1.
Brown WT, Wu X, Fayad F, et al. Application of robotic stereotactic radiotherapy to peripheral stage I non-small cell lung cancer with curative intent. Clin Oncol (R Coll Radiol) 2009;21:623-631.
Fakiris AJ, McGarry RC, et al. Stereotactic Body Radiation Therapy for Early-Stage Non-Small-Cell Lung Carcinoma: Four-Year Results of a Prospective Phase II Study. Int J Radiat Oncol Biol Phys 2009;75(3):677-682.
Onishi H, Shirato H, Nagata Y, et al. Stereotactic Body Radiotherapy (SBRT) for Operable Stage I Non-Small Cell Lung Cancer: Can SBRT be Comparable to Surgery? Int J Radiat Oncol Biol Phys 2010.
[9] Sources:
Stintzing S, Hoffmann RT, Heinemann V, et al. Radiosurgery of Liver Tumors: Value of Robotic Radiosurgical Device to Treat Liver Tumors. Ann Surg Oncol 2010;17:2877-2883.
Rusthoven KE, Kavanagh BD, Cardenes H, et al. Multi-institutional phase I/II trial of stereotactic body radiation therapy for liver metastases. J Clin Oncol 2009;27:1572-1578
Tse RV, Hawkins M, Lockwood G, et al. Phase I study of individualized stereotactic body radiotherapy for hepatocellular carcinoma and intrahepatic cholangiocarcinoma. J Clin Oncol 2008;26:657-664.
Wulf J, Guckenberger M, Haedinger U, et al. Stereotactic Radiotherapy of Primary Liver Cancer and Hepatic Metastases. Acta Oncologica 2006;45:838-847.
Wulf J, Hadinger U, Oppitz U, et al. Stereotactic Radiotherapy of Targets in the Lung and Liver. Strahlenther Onkol 2001;177:645-655.
Herfarth KK, Debus J, Lohr F, et al. Stereotactic Single-Dose Radiation Therapy of Liver Tumors: Results of a Phase I/II Trial. J Clin Onc 2001;19(1):164-170.
Dawood O, Mahadevan A, Goodman K. Stereotactic Body Radiation Therapy for Liver Metastases. Eur J Cancer 2009;45(17)2947-2959.

2-year survival	18-47%	32-62%

Prostate

It is important to note that SBRT to treat prostate cancer is not a novel concept. Researchers in the United Kingdom first began to experiment with hypofractionation techniques to treat prostate cancer in the 1980's. The best current explanation of the effect of radiation on cancerous tumors is derived from a linear quadratic model (α/β ratio), which calculates biologically effective dose using number of fractions, and dose per fraction. This model shows that slow growing tumor cells, such as those in the prostate, are more sensitive to higher doses of radiation given in a smaller number of fractions.

The radiobiology of prostate cancer, which shows improved outcomes from high doses per fraction, has been demonstrated by practitioners of high dose rate (HDR) brachytherapy, for which there are comparable data, in terms of long-term follow-up. Trials with HDR prostate brachytherapy have shown excellent biochemical disease free survival, with low levels of toxicity. In clinical practice, SBRT is frequently performed to treat prostate cancer in patients who would otherwise be treated with HDR brachytherapy. Unfortunately, HDR brachytherapy is a technically challenging and highly invasive procedure, which requires general anesthesia and an inpatient hospital stay, adding to patient discomfort and inconvenience.

In 2000, the first prostate cancer patients in the United States were treated with SBRT. Since that time, just under 10,000 patients worldwide have received SBRT to treat their prostate cancer, with the vast majority of these patients being treated (approx 8,000) with the CyberKnife. The rapid adoption of SBRT stems from the fact that prostate cancer is biologically distinct from most other cancers. Researchers at Stanford University (Xie et al 2008) noted that intrafractional organ motion (up to 1 cm) of the prostate has long been recognized as one of the major limiting factors of prostate dose escalation in conformal radiation therapy. The same publication notes the importance of real-time image guidance and motion-compensation techniques that are employed by the CyberKnife robotic system to deliver extremely precise hypofractionated prostate radiation treatment. Given the magnitude and random nature of prostate motion, as well as recent technical advancements in various related fields, real-time monitoring of prostate position to compensate for the motion is critical to ensure adequate dose coverage of the target while maintaining adequate sparing of the adjacent structures. A UCSF study (Jabbari et al., 2011) noted the following about CyberKnife SBRT, *"…the prostate gland's intrafractional motion and minimal PTV expansions required for safe HDR brachytherapy-like dosimetry may preclude the use of linac-based systems for prostate SBRT without a real-time target tracking and beam-correction system to account for intra-fraction motion."*

The table below highlights the improved clinical outcomes of CyberKnife SBRT compared to conventional EBRT for prostate cancer. It is important to note that the vast majority of prostate SBRT is being performed with the CyberKnife because it can track for the random motion of the prostate and adjust the beam in real-time based this motion, which is critically important when delivering dose to the area around the rectum and bladder, to reduce complications such as incontinence, ED, and rectal bleeding. Since the vast majority of SBRT is performed utilizing the CyberKnife, the majority (> 90%) of the SBRT clinical literature available is based on results from the CyberKnife. The table below highlights the improved clinical outcomes of SBRT compared to conventional EBRT.

Comparison of Conventional EBRT vs. CyberKnife Clinical Outcomes for Prostate Cancer[8][10]		
	Conventional EBRT	***SBRT***
Late toxicity	4-6%	0-2%
Biochemical disease free survival	84% (5-year)	93% (5-year)

Pancreas

For those patients who are no longer surgical candidates, radiation therapy in addition to chemotherapy presents the best treatment option. Conventional EBRT along with chemotherapy results in high rates of local failure for patients diagnosed with pancreatic cancer[11]. Conventional EBRT requires significantly longer treatment times, which can take a substantial amount of time from pancreatic patients with limited life expectancy. In addition, the toxicity and side effects from conventional EBRT are significant. A Beth Israel Deaconess Medical Center study (Mahadevan et al. 2010) noted the following about the importance of abbreviated treatment (vs. EBRT) using the CyberKnife SBRT for the treatment of pancreatic cancer, *"Hypofractionated SBRT can be delivered safely and quickly to potentially benefit patients with locally advanced unresectable pancreatic cancer. Our results have shown that three-fraction SBRT, given on 3 consecutive days, can be performed safely with minimal side effects, allowing rapid initiation of chemotherapy. The toxicity and outcomes appeared comparable to, or more favorable than, those of conventional chemoradiotherapy."*[12]

In addition, a University of Pittsburgh study indicated the following about the shorter course of treatment with SBRT versus conventional radiation therapy, *"…SBRT was completed in 1 to 2 days compared with typical 4 or more weeks required to complete external beam radiotherapy, which serves to further expedite chemotherapy in these patients. An additional benefit of SBRT is pain relief, which was achieved in 81.3% of those who presented with pain prior to SBRT."*[13]

The following table below notes the significantly improved clinical outcomes of CyberKnife SBRT +/- chemotherapy compared to conventional EBRT +/- chemotherapy.

---

[10] Sources:
Engineer R, Bhutani R, Mahantshetty U, et al. From 2-dimensional to three-dimensional conformal radiotherapy in prostate cancer: an Indian experience. Ind J Cancer 2010;47(3):332-338.
Kupelian P, Kuban D, Thames H, et al. Improved Biochemical Relapse-Free Survival with increased External Radiation Doses in Patients with Localized Prostate Cancer: The Combined Experience of Nine Institutions Treated in 1994 and 1994. Int J Radiat Oncol Biol Phys 2005;61(2):415-419.
Zietman AL, DeSilvio ML, Slater JD, et al. Comparison of Conventional-Dose vs. High-Dose Conformal Radiation Therapy in Clinically Localized Adenocarcinoma of the Prostate: A Randomized Clinical Trial. JAMA 2005;294(10):1233-1239.
Freeman DE, King CR. Stereotactic body radiotherapy for low-risk prostate cancer: five-year outcomes. Radiat Oncol 2010;6:3. King CR, Brooks JD, Gill H, et al. Long-term outcomes from a prospective trial of stereotactic body radiotherapy for low-risk prostate cancer. Int J Radiat Oncol Biol Phys 2012;82(2):877-882.
Friedland JL, Freeman DE, Masterson-McGary ME, et al. Stereotactic body radiotherapy: an emerging treatment approach for localized prostate cancer. Technol Cancer Res Treat 2009;8:387-392.
Katz AJ, Santoro M, Ashley R, et al. Stereotactic body radiotherapy for organ-confined prostate cancer. BMC Urol 2010;10:1.

[11] Martin A & Gaya A. Stereotactic body radiotherapy: a review. Clin Oncol 2010;22(3):157-172.

[12] Mahadevan A, Jain S, Goldstein M, et al. Stereotactic Body Radiotherapy and Gemcitabine for Locally Advanced Pancreatic Cancer. Int J Rad Oncol Biol Phys 2010;78:735-742.

[13] Rwigema JM, Parikh SD, Heron DE, et al. Stereotactic Body Radiotherapy in the Treatment of Advanced Adenocarcinoma of the Pancreas. Amer J Clin Oncol 2011;34:63-69.

Comparison of Conventional EBRT vs. CyberKnife Clinical Outcomes for Pancreatic Cancer[14]		
	***Conventional EBRT* +/- chemotherapy**	***CyberKnife SBRT* +/- chemotherapy**
Treatment times	6 weeks	< 1 week
Median overall survival	5.3-11.4 months	8-18.6 months
Local progression free survival	42-62%	91.7%

KQ2: What are the potential harms of SRS and SBRT compared to conventional external beam radiation therapy (EBRT)? What is the incidence of these harms? Include consideration of progression of treatment in unnecessary or inappropriate ways.

The tables in section KQ1 provide details of the significantly reduced toxicity levels of treatment with SRS/SBRT compared to conventional EBRT.

SRS and SBRT treatments deliver much higher doses of radiation in far fewer treatments compared to EBRT (although the overall biological equivalent dose per treatment is similar). Higher doses per treatment can potentially harm patients, necessitating a treatment plan with steep dose falloff and the ability to track and adjust for motion. The CyberKnife's robotically enhanced ability to deliver beams from over 1600 unique beam angles achieves the dose falloff and tighter treatment margins, by tracking and compensating for movement throughout the treatment. This is accomplished by moving to and with the patient, and tracking and adjusting for movement and tumor deformation during beam on. EBRT systems image before but not during "beam on", therefore clinician must attempt to compensate for movement by controlling the patient movement instead of adjusting dose delivery with the natural patient movement. One way clinicians using non-robotic, EBRT systems attempt to compensate for movement is by a procedure called respiratory gating. For gating to work properly a) the patient's respiratory cycle must be periodic and maintained during treatment, b) the movement of the target must be related to the respiratory cycle, and c) the gating window is set sufficiently large to minimize overall treatment time. Even if all these requirements are met, contouring should still account for the tumor residual motion, setup uncertainty, and deviation from the expected respiratory cycle during treatment. These requirements result in a significantly larger treatment margin, increasing the chance of irradiating healthy tissue and critical structures. In other treatment areas where movement is random, the only solution for EBRT systems is to increase the margin irradiating the entire area of movement the tumor may travel. The CyberKnife's robotic delivery, which moves beams to and with the patient during treatment, significantly reduces irradiation of healthy tissue and organs at risk.

Coding

The unique codes CMS created for Robotic Stereotactic Radiosurgery are G0339 and G0340. While the majority of fractionated SRS and SBRT in the United States are performed with the CyberKnife, curiously

[14] Sources:
Mahadevan A, Jain S, Goldstein M, et al. Stereotactic body radiotherapy and gemcitabine for locally advanced pancreatic cancer. Int J Radiat Oncol Biol Phys 2010;78:735-742.
Didolkar MS, Coleman CW, Brenner MJ, et al. Image-guided stereotactic radiosurgery for locally advanced pancreatic adenocarcinoma results of first 85 patients. J Gastrointest Surg 2010;14:1547-1559.

G0339 and G0340 are not listed on the Washington Medicaid Fee Schedule, and the codes for gantry-based SRS and SBRT (G0251 and G0173) are. Below we provide information on SRS and SBRT codes, which have been in effect since January of 2003. G0339 and G0340 are well accepted and recognized codes by Medicare and private payers alike. CMS offers the following direction when coding claims for robotic and non-robotic/gantry-based systems:

Transmittal 1139 of the CMS Manual System Pub 100-04 Medicare Claims Processing (12/22/2006), defines SRS and the associated coding this way: *"There are two basic methods in which SRS can be delivered to patients, linear accelerator-based treatment and multi-source photon-based treatment (often referred to as Cobalt 60). Advances in technology have further distinguished linear accelerator-based SRS therapy into two types: gantry-based systems and image-guided robotic SRS systems. These two types of linear accelerator-based SRS therapies may be delivered in a complete session or in a fractionated course of therapy up to a maximum of five sessions."*

Linear Accelerator-Based Robotic Image-Guided SRS	
Planning	Use existing CPT codes
Delivery	G0339 (Complete course of therapy in one session or first session of fractionated treatment) G0340 (Second through fifth sessions, maximum five sessions per course of treatment)

Linear Accelerator-Based Non-Robotic/Gantry Image-Guided SRS	
Planning	Use existing CPT codes
Delivery	G0173 (Complete course of treatment in one session) G0251 (All lesions, maximum 5 session per course of treatment)

KQ3: What is the evidence that SRS and SBRT have differential efficacy or safety issues in sub populations? Including consideration of: a) gender b) age c) site and type of cancer d) stage and grade of cancer e) setting, provider characteristics, equipment, quality assurance standards and procedures

SRS/SBRT are used to treat a wide variety of patients and demographics.

The CyberKnife received FDA clearance to *provide treatment planning and image-guided stereotactic radiosurgery and precision radiotherapy for lesions, tumors and conditions of the brain, base of skull and cervico-thoracic spine (CTS), head and neck in 1999 (FDA 510(k) # K984563).* In 2001, the CyberKnife received FDA clearance *to provide treatment planning and image-guided stereotactic radiosurgery and precision radiotherapy for lesions, tumors and conditions anywhere in the body when radiation treatment is indicated (FDA 510(k) # K011024).* Unlike frame-based radiosurgery systems, which are generally limited to treating brain tumors, CyberKnife radiosurgery is being used to treat to tumors throughout the entire body.

Aetna's national SRBT policy which has been in place since 2008 (most recent update 1/26/2012) states the following: *"Stereotactic body radiation therapy (SBRT) with a gamma knife, Cyberknife, or linear*

accelerator (LINAC) is considered medically necessary for localized malignant conditions within the body where highly precise application of high dose radiotherapy is required…", allowing the physician and patient to determine the correct treatment option for the patient.

SRS/SBRT treatment can be delivered in the hospital and physician office setting by well qualified and trained physicians. The multi-specialty treatment team should include, Radiation Oncologists, Physicists, Radiation Therapists, additional Physician Specialists (depending on the treatment area), and support staff. All staff should be trained on the SBRT system being used.

KQ4: What is the evidence of cost and cost-effectiveness of SRS and SBRT compared to EBRT?

Unfortunately, there is a lack of clinical literature which compares the cost of radiation therapies across the board. However, the data that have been published demonstrate a significant cost effectiveness advantage of SBRT over 3D conformal radiation, which we believe supports its use for the other indications for which clinical outcomes are shown by the literature to be improved using SBRT over 3D conformal radiation. The table provided as an appendix, provides information about the three clinical publications that note the cost differential between SBRT and conventional EBRT for medically inoperable non-small cell lung cancer and pancreatic cancer.

Conclusion

As outlined above, SRS/SBRT has become a standard of care and a clinical option that is available to cancer patients throughout the United States. SRS/SBRT can treat patients with brain, spine, lung, liver, pancreas, and prostate cancer (and other lesions with a documented necessity to treat using a high dose per fraction of radiation). Given the positive SRS/SBRT clinical outcomes compared to conventional EBRT, we urge the Washington State Health Care Authority to add G0339 and G0340 as a covered benefit for Medicaid patients in the state of Washington.

The CKC thanks the Washington State Health Care Authority for this opportunity to provide comments regarding CyberKnife SRS/SBRT. Our member institutions, including those in Washington State, would be delighted to meet with you in person to answer any further questions or concerns. In addition, please feel free to contact us at the numbers below if we can be of any assistance as your organization continues to evaluate this topic.

Sincerely,

Linda F. Winger, MSc, FACHE
President, CyberKnife Coalition Vice President, Washington Region Oncology Services MedStar Health
3800 Reservoir Road, NW
Washington, DC 20007-2197
202-412-3191
Linda.F.Winger@medstar.net

John W. Rieke, MD, FACR
Board of Directors, CyberKnife Coalition
Medical Director, MultiCare Regional Cancer Center
1003 South 5th Street
Tacoma, Washington 98405
253-403-4994
John.Rieke@Multicare.org

Publication	Comparators	Summary
Lanni TB, Grills IS, Kestin LL, et al. **Stereotactic radiotherapy reduces treatment cost while improving overall survival and local control over standard fractionated radiation therapy for medically inoperable non-small cell lung cancer.** Amer J Clin Oncol 2011;34(5)494-498.	• SBRT • 3D-CRT	• 3D-CRT: n=39; SBRT: n=44 • Median follow-up: 36 months • SBRT was significantly less expensive ($13,639 EBRT vs. $10,616 SBRT, P < 0.01) based on 2010 hospital-based Medicare reimbursement (technical + professional) • Superior 36-month overall survival using SBRT, 71% vs. 42% for EBRT (P<0.05) • SBRT reduced local failure by nearly 3 times compared with EBRT (12% vs. 34%, P = 0.10)
Sher DJ, Wee JO, Punglia RS. **Cost-effectiveness analysis of stereotactic body radiotherapy and radiofrequency ablation for medically inoperable early-stage non-small cell lung cancer.** Int J Rad Oncol Biol Phys 2011;81(5):e767-774.	• SBRT • 3D-CRT	• Study developed a Markov model for 65-year old men with medically inoperable NSCLC • Incremental cost-effectiveness ratio (ICER) for SBRT over 3D-CRT was $6,000/QALY • Model predicted 3-year local recurrence, regional recurrence, and distant metastasis rates: SBRT – 10.5%, 9%, 9%; 3D-CRT – 34%,7%,7%; "In comparison to 3D-CRT, SBRT was the most cost-effective treatment for medically inoperable NSCLC…" • "On the basis of efficacy and cost, SBRT should be the primary treatment for this disease."
Murphy JD, Chang DT, Abelson J, et al. **Cost-effectiveness of modern radiotherapy techniques in locally advanced pancreatic cancer**. Cancer 2012;118(4):1119-1129.	• Gemcitabine alone • Gemcitabine plus conventional radiotherapy • Gemcitabine plus intensity-modulated radiotherapy (IMRT) • Gemcitabine with SBRT	• SBRT increased life expectancy by 0.20 quality-adjusted life years (QALY) at an increased cost of $13,700 compared with gemcitabine along • SBRT was more effective and less costly than conventional radiotherapy and IMRT • Current results indicate that IMRT in locally advanced pancreatic cancer exceeds what society considers cost-effective • In contrast, combining gemcitabine with SBRT increased clinical effectiveness beyond that of gemcitabine alone at a cost potentially acceptable by today's

Publication	Comparators	Summary
		standards

From: Howard, Todd
To: HCA ST Health Tech Assessment Prog
Cc: Gilmore-Lawless, Catherine C; Howard, Todd
Subject: Public Comment for: Stereotactic Radiation Surgery and Stereotactic Body Radiation Therapy
Date: Friday, March 02, 2012 12:26:27 PM
Attachments: Washington State Health Care Authority Dossier V 1.0 3.2.2012.pdf
Addendum D - Apparatus Dependent Brain Mets.pdf
Addendum A - ASTRO Brain mets guideline.pdf
Addendum B - Neuro Guidelines.pdf
Addendum C - Saghaletal Meta-Analysis.pdf
Importance: High

To whom it may concern:
Elekta, the manufacturer of the Leksell Gamma Knife® and a comprehensive array of oncology solutions including linear accelerators, treatment planning and electronic medical records software, sincerely appreciates the opportunity provided by the Washington State Health Care Authority to comment on the topic of *Stereotactic Radiation Surgery and Stereotactic Body Radiation Therapy*. We hope you find the facts in this document to be beneficial to your assessment. Additionally, we would be more than willing to meet in person with you as a follow-up or coordinate a meeting with one of the Gamma Knife centers in the State of Washington to address any additional questions or data needs that you may have during this process.

Best regards,

Todd Howard

Todd Howard, MBA
Manager, Business Development
Elekta, Inc.
4775 Peachtree Industrial Blvd.
Suite 300, Bldg. 300
Norcross, GA 30092
(O) 770-670-2321
(M) 404-513-6569

Please consider the environment before printing this e-mail. The contents of this e-mail message (including any attachments) are confidential to and are intended to be conveyed for the use of the recipient to whom it is addressed only. If you receive this transmission in error, please notify the sender of this immediately and delete the

message from your system. Any distribution, reproduction or use of this message by someone other than recipient is not authorized and may be unlawful.

Note: The following articles were attached to this email as PDFs

Linskey, M.E., Andrews, D.W., Asher, A.L., Burri, S.H., Kondziolka, D., Robinson, P.D., Ammirati, M., Cobbs, C.S., Gaspar, L.E., Loeffler, J.S., McDermott, M., Mehta, M.T., Mikkelsen, T., Olson, J.J., Paleologos, N.A., Patchell, R.A., Ryken, T.C., & Kalkanis, S.N. (2010). The role of stereotactic radiosurgery in the management of patients with newly diagnosed brain metastases: A systematic review and evidence-based clinical practice guideline. *Journal of Neurooncology, 96*, 45-68.

Ma, L., Petti, P., Wang, B., Descovich, M., Chuang, C., Barani, I.J., Kunwar, S., Shrieve, D.C., Sahgal, A., & Larson, D.A. (2011). Apparatus dependence of normal brain tissue dose in stereotactic radiosurgery for multiple brain metastases. *Journal of Neurosurgery, 114*(6), 1580-4..

Tsao, M.N., Rades, D., Wirth, A., Lo, S.S., Danielson, B.L., Gaspar, L.E., Sperduto, P.W., Vogelbaum, M.A., Radawski, J.D., Wang, J.Z., Gillin, M.T., Mohideen, N., Hahn, C.A., & Chang, E.L. (2012). Radiotherapeutic and surgical management for newly diagnosed brain metastasis(es): An American Society for Radiation Oncology evidence-based guideline. *Practical Radiation Oncology.* [Article in Press].

Tsao, M.N., Xu, W., & Sahgal, A. (2011). A meta-analysis evaluating stereotactic radiosurgery, whole-brain radiotherapy, or both for patients presenting with a limited number of brain metastases. *Cancer.* [ePub ahead of print]

ELEKTA

Leksell Gamma Knife®

Comments on Stereotactic Radiation Surgery
For: Washington State Health Care Authority

Prepared by: *Catherine Gilmore-Lawless, Vice President, Clinical Intelligence*
Todd Howard, Director of Business Development
Elekta, Inc.
Date: *March 2, 2012*

Table of Contents

INTRODUCTION 3
KEY QUESTION #1 – WASHINGTON STATE HEALTH CARE AUTHORITY 9
KEY QUESTION #2 – WASHINGTON STATE HEALTH CARE AUTHORITY 12
KEY QUESTION #3 – WASHINGTON STATE HEALTH CARE AUTHORITY 14
KEY QUESTION #4 – WASHINGTON STATE HEALTH CARE AUTHORITY 16
REFERENCE LIST: THE GAMMA KNIFE AND THE TREATMENT OF METASTATIC BRAIN TUMORS (1989-2/2012) 17
ADDENDUM A – ASTRO BRAIN METS GUIDELINES 37
ADDENDUM B – NEURO GUIDELINES 38
ADDENDUM C – TSAO, M., W. XU, AND A. SAHGAL, A META-ANALYSIS EVALUATING STEREOTACTIC RADIOSURGERY, WHOLE-BRAIN RADIOTHERAPY, OR BOTH FOR PATIENTS PRESENTING WITH A LIMITED NUMBER OF BRAIN METASTASES. CANCER, 2011. 39
ADDENDUM D – APPARATUS DEPENDENCE OF NORMAL BRAIN TISSUE DOSE IN 40
STEREOTACTIC RADIOSURGERY FOR MULTIPLE BRAIN METASTASES. 40
ADDENDUM E – EXCERPT FROM REGENCE BCBS MEDICAL POLICY ON STEREOTACTIC RADIOSURGERY 41

Introduction

Elekta, the manufacturer of the Leksell Gamma Knife® and a comprehensive array of oncology solutions including linear accelerators, treatment planning and electronic medical records software, sincerely appreciates the opportunity provided by the Washington State Health Care Authority to comment on the topic of *Stereotactic Radiation Surgery and Stereotactic Body Radiation Therapy*. We hope you find the facts in this document to be beneficial to your assessment. Additionally, we would be more than willing to meet in person with you as a follow-up or coordinate a meeting with one of the Gamma Knife centers in the State of Washington to address any additional questions or data needs that you may have during this process.

Stereotactic Radiosurgery

Elekta was founded in 1972 by the late Lars Leksell, Professor of Neurosurgery at the Karolinska Institute in Stockholm, Sweden. His pioneering work led to the development of the technique: Stereotactic Radiosurgery which he defined as the "delivery of a single, high dose of irradiation to a small and critically located intra-cranial volume through the intact skull." The technique differs markedly from conventional radiation therapy (RT), which involves exposing large areas of tissue to relatively broad fields of radiation over a number of sessions. Originally used to treat just "inoperable" brain tumors and vascular malformations, the technique of stereotactic radiosurgery has become an indispensable alternative and adjunct to conventional techniques such as surgery (craniotomy) or conventional radiation therapy for a wide array of intracranial indications. Patients benefit from this fast, painless treatment, usually conducted in an outpatient setting without the need for general anesthesia, inpatient hospitalization or even convalescence. The benefits of this non-invasive approach include high clinical efficacy, low mortality and morbidity, high patient satisfaction and cost effectiveness.

The Gamma Knife

The Leksell Gamma Knife® was developed specifically to perform stereotactic radiosurgery of the brain. Recognizing the enormous need for accuracy and precision, given neuroanatomy and the potential toxicity of high doses of radiation, the Gamma Knife was designed to be as accurate and precise as possible; its hallmark design principle is that the target (isocenter) and sources of radiation are in a fixed relationship during treatment. With no moving parts during treatment, the Gamma Knife is guaranteed to deliver radiation with sub-millimetric accuracy. Its hemispheric source array and dose distributions allow for extremely conformal and selective treatments, resulting in very high clinical efficacy and minimal morbidity.

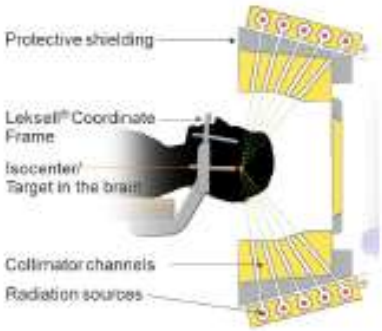

Unlike other linear accelerator-based technologies such as CyberKnife or Tomotherapy which are used most frequently for stereotactic body radiation therapy (SBRT), the Gamma Knife is dedicated to, and used exclusively for, the treatment of brain disorders.

With more than 440 Leksell Gamma Knife® systems, Elekta has the largest installed base of dedicated *intracranial* stereotactic radiosurgery systems in the world, including 128 units in North America, four (4) of which are located in Washington State at:

- Harborview, University of Washington, Seattle
- Spokane Gamma Knife Center, Spokane
- Swedish Hospital, Seattle
- South Sound Gamma Knife at St. Joseph, Tacoma

These centers serve the State of Washington but also treat patients from surrounding geographies including Idaho, Montana, Alaska and Canada.

Indications Overview

According to the Leksell Gamma Knife Society[1], over 156,000 patients have been treated in the U.S. since the first Gamma Knife was installed in August, 1987 with approximately 11,000 patients receiving Gamma Knife surgery each year. The corresponding global numbers are 610,000 and 60,000, respectively.

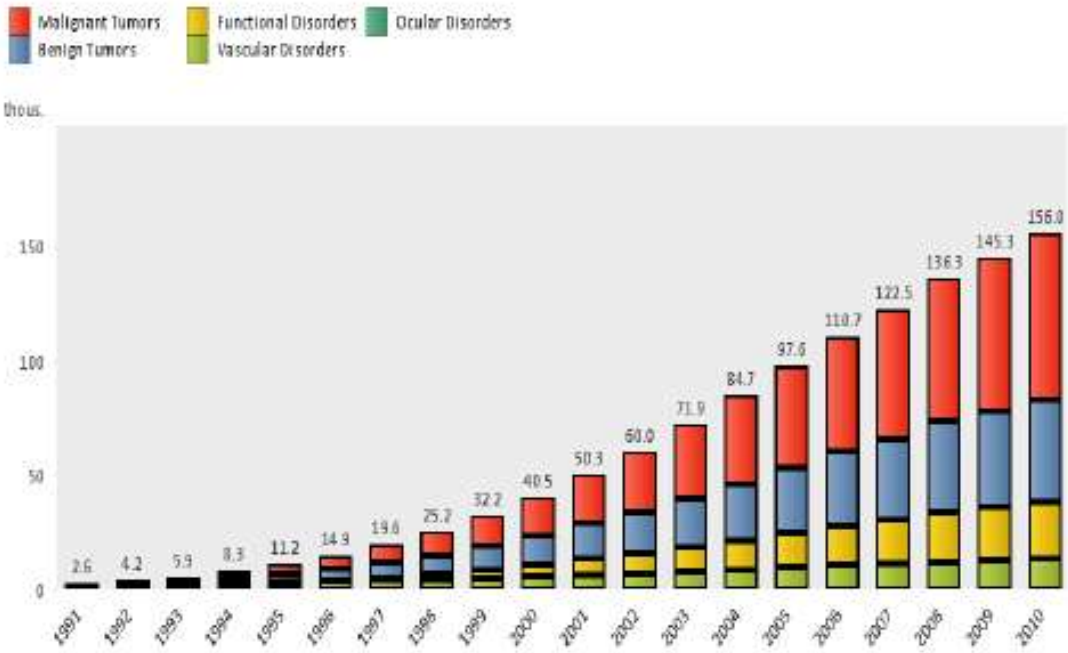

PATIENTS TREATED WITH THE GAMMA KNIFE IN THE U.S. 1897-2010

[1] The International Leksell Gamma Knife® Society was formed in 1989 to further validate and expand the role of Gamma Knife surgery in the treatment of intracranial disorders and foster a commitment to the highest standards of research and technical achievement while stimulating multi-center trials and cross-site collaboration. The Society conducts an annual survey of all Gamma Knife sites to track the total treatment volume, clinical trends and regional differences. Not all sites report.

The Gamma Knife is used for neoplastic and vascular anomalies of the brain and upper cervical spine (usually to C2). It has also been used for the treatment of facial pain and movement disorders such as essential tremor. The ICD-9 codes currently applicable to Gamma Knife surgery are as follows:

Gamma Knife Relevant Disease Indications	
ICD-9 Code	**Disease**
191.0-191.9	Malignant neoplasm of brain
192.0	Malignant neoplasm of Cranial Nerves
192.1	Cerebral Meninges
192.3	Spinal Meninges
194.3-194.4	Malignant Neoplasm (pituitary/pineal)
198.3-198.4	Metastatic neoplasm to brain/meninges
225.0-225.2	Benign Neoplasms-brain/nerve/meninges
227.3-4, 237.0	Pituitary/craniopharyngeal neoplasm
237.0-1	Neoplasms of uncertain behavior
227.6	Glomus jugulare
237.3	Glomus neoplasm
747.81	AVM of cerebral vessels
350.1	Trigeminal Neuralgia
332.1	Essential Tremor

The Gamma Knife case mix has evolved over time. Originally, vascular malformations and benign brain tumors were the most common indications. Today, as indicated in the chart below, malignant tumors (red bars), specifically metastases, are the most common indication treated, followed by trigeminal neuralgia.

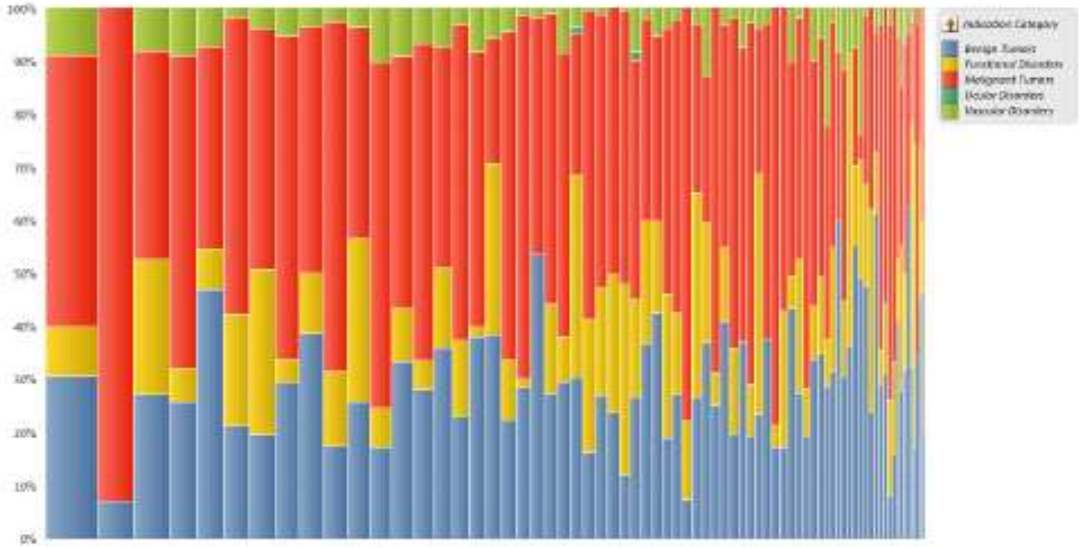

2010 CASE MIX BY U.S. SITE[1]

Over 60,000 metastatic brain tumor patients have been treated with the Gamma Knife in the U.S. Additionally, over 10,000 primary malignant tumor patients have been treated, usually in a recurrent setting.

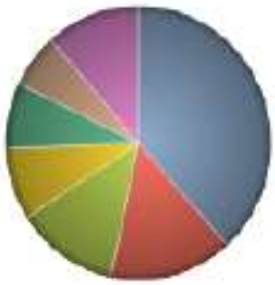

Indication	
Metastatic Tumor	59,797
Trigeminal Neuralgia	23,485
Meningioma	19,553
Vestibular Schwannoma	13,168
AVM	12,199
Malignant Glial Tumor (grade III a...	9,937
Others	17,871

Further detail of the types of malignant brain conditions treated over time with the Gamma Knife is illustrated in the chart below:

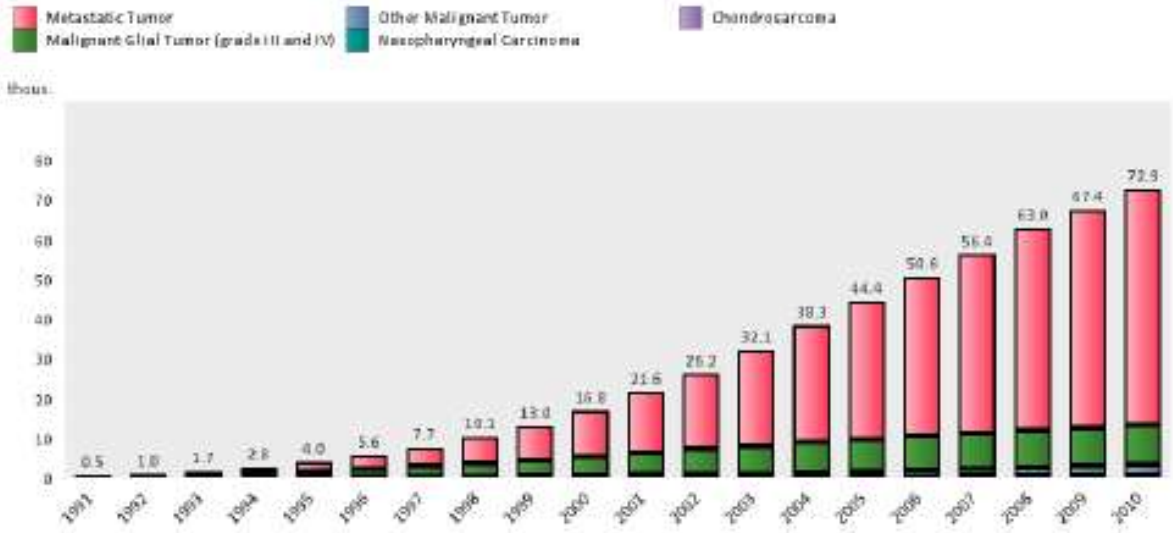

MALIGNANT TUMORS TREATED WITH THE GAMMA KNIFE IN THE U.S.[1]

Clinical Evidence Overview

Because the Gamma Knife was designed and is dedicated for the brain, Gamma Knife centers tend to be located in neuroscience and oncologic centers of excellence or centers with a major focus on cranial conditions. Gamma Knife sites tend to be recipients of a larger number of referrals both from physicians and patients themselves and the average case volume is typically three times that of centers using other technology for radiosurgery, allowing centers to build significant expertise. Robust clinical activity, a relatively homogenous treatment technique (even globally) and a strong interest and commitment to scientific excellence have resulted in a large number of presentations and publications. The Gamma Knife has an impressive and unparalleled scientific track record with over 3,000 peer-reviewed articles. No other radiosurgery technology approaches the Gamma Knife in terms of clinical documentation for brain radiosurgery as indicated in the following chart which reflects the number of (single session) stereotactic radiosurgery papers reporting series of 30 patients or more.

RADIOSURGERY PAPERS REPORTING MORE THAN 30 PATIENTS THROUGH FEBRUARY 2012

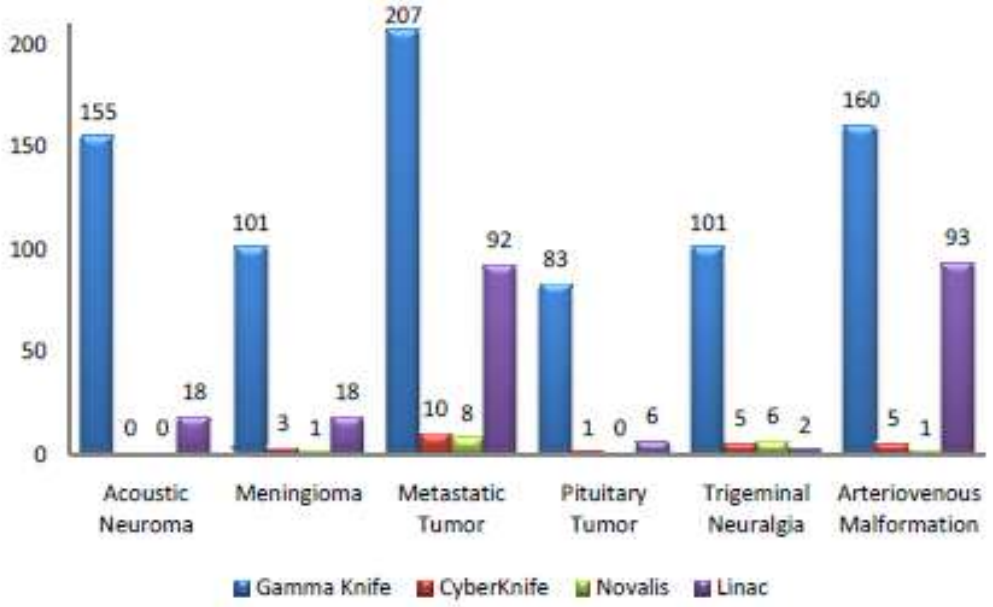

Source: Elekta Clinical Database (using PubMed)

Elekta maintains a comprehensive database of articles and would be happy to provide references upon request. A Reference List of articles concerning the use of the Gamma Knife in the treatment of metastatic and primary malignant tumors may be found in the Addendum.

The remainder of this document will address the following topics and specific questions as outlined in the Health Care Authority assessment on "Stereotactic Radiation Surgery and Stereotactic Body Radiation Therapy."

- (KQ1) – What is the evidence of effectiveness for stereotactic radiation surgery (SRS) and stereotactic body radiation therapy compared to conventional external beam radiation therapy (EBRT) for the following patients:
  - Patients with central nervous system (CNS) tumors
  - Patients with non-central nervous system cancers?
- (KQ2) - What are the potential harms of SRS and SBRT compared to conventional external beam radiation therapy (EBRT)? What is the incidence of these harms? Include consideration of progression of treatments in unnecessary or inappropriate ways.
- (KQ3) – What is the evidence that SRS and SBRT have differential efficacy or safety issues in sub populations? Including consideration of:
  - Gender
  - Age
  - Site and type of cancer
  - Stage and grade of cancer
  - Setting, provider characteristics, equipment, quality assurance standards and procedures.
- (KQ4) – What is the evidence of cost and cost-effectiveness of SRS and SBRT compared to EBRT?

Key Question #1 – Washington State Health Care Authority

What is the evidence of effectiveness for stereotactic radiation surgery (SRS) and stereotactic body radiation therapy compared to conventional external beam radiation therapy (EBRT) for the following patients:

- *Patients with central nervous system (CNS) tumors*
- *Patients with non-central nervous system cancers?*

In responding to Key Question #1, we will limit our comments to central nervous system (CNS) tumors only as the Gamma Knife is only used for intracranial conditions. We will also limit our comments to malignant disease only. Please let us know if you would like additional commentary on benign disease.

Brain metastases are the most common intracranial solid tumor. The incidence is increasing because of advances in diagnostic imaging and ubiquitous screening, an aging population and longer survival due to effective targeted systemic therapies. The current purpose of brain metastasis management is no longer restricted to palliation; goals include extended survival, and importantly preservation of quality of life. To meet these requirements, SRS and in particular, the Gamma Knife, has become a very important tool in the management of these patients. With the increased utilization of SRS, significant effort has been put forth by clinicians, and researchers to identify the ideal treatment paradigm; these efforts are aligned with the questions appropriately posed by the Washington State Health Care Authority.

Two sets of guidelines have been recently released by the professional associations of radiation oncologists and neurosurgeons and are provided in the Addendum to this comment. The most recent guidelines from the American Society of Therapeutic Radiation Oncology (ASTRO) were released in early February, 2012 and are currently in press. They conducted an extensive review of the available evidence to address a number of important metastatic brain tumor issues including two areas germane to the WSHA Key Question #1, namely:

- "is there a survival or brain control difference in patients treated with WBRT and radiosurgery boost versus WBRT alone?
- is there a difference in survival, brain control or neurocognitive outcomes in patients treated with radiosurgery alone versus WBRT and radiosurgery?"

They found that "In selected patients with single brain metastasis, **radiosurgery or surgery has been found to improve survival and locally treated metastasis control (compared with WBRT alone).**" ASTRO additionally provided the following guidelines for patients with good prognosis (expected to live longer than three months):

- "For single metastasis less than 3 to 4 cm, radiosurgery alone or WBRT and radiosurgery or WBRT and surgery (all based on level 1 evidence) should be considered. Another alternative is surgery and radiosurgery or radiation boost to the resection cavity (level 3).

- For single brain metastasis (less than 3 to 4 cm) that is not resectable or incompletely resected, WBRT and radiosurgery, or radiosurgery alone should be considered (level 1).
- For patients with multiple brain metastases (all less than 3 to 4 cm), radiosurgery alone, WBRT and radiosurgery, or WBRT alone should be considered, based on level 1 evidence. Safe resection of a brain metastasis or metastases causing significant mass effect and postoperative WBRT may also be considered (level 3)."

These more recent guidelines are essentially congruent with the earlier guidelines published by the American Association of Neurological Surgeons and the Congress of Neurological Surgeons in the December 2009 issue of the *Journal of Clinical Oncology*. In specifically addressing the role of SRS and EBRT, they concluded:

SRS plus WBRT vs. WBRT alone
Level 1 Single-dose SRS along with WBRT leads to significantly longer patient survival compared with WBRT alone for patients with single metastatic brain tumors who have a KPS ≥70.

Level 2 Single-dose SRS along with WBRT is superior in terms of local tumor control and maintaining functional status when compared to WBRT alone for patients with 1–4 metastatic brain tumors who have a KPS≥70.

Level 3 Single-dose SRS along with WBRT may lead to significantly longer patient survival than WBRT alone for patients with 2–3 metastatic brain tumors.

Level 4 There is class III evidence demonstrating that single-dose SRS along with WBRT is superior to WBRT alone for improving patient survival for patients with single or multiple brain metastases and a KPS < 70.

SRS plus WBRT vs. SRS alone
Level 2 Single-dose SRS alone may provide an equivalent survival advantage for patients with brain metastases compared with WBRT? single-dose SRS. There is conflicting class I and II evidence regarding the risk of both local and distant recurrence when SRS is used in isolation and class I evidence demonstrates a lower risk of distant recurrence with WBRT; thus, regular careful surveillance is warranted for patients treated with SRS alone in order to provide early identification of local and distant recurrences so that salvage therapy can be initiated at the soonest possible time.

Surgical Resection plus WBRT vs. SRS ± WBRT
Level 2 Surgical resection plus WBRT, vs. SRS plus WBRT, both represent effective treatment strategies, resulting in relatively equal survival rates. SRS has not been assessed from an evidence-based standpoint for larger lesions (> 3 cm) or for those causing significant mass effect (>1 cm midline shift). Level 3: Underpowered class I evidence along with the preponderance of conflicting class II evidence suggests that SRS alone may provide equivalent functional and survival outcomes compared with resection + WBRT for patients with single brain metastases, so long as ready detection of distant site failure and salvage SRS are possible.

SRS alone vs. WBRT alone

Level 3 While both single-dose SRS and WBRT are effective for treating patients with brain metastases, single dose SRS alone appears to be superior to WBRT alone for patients with up to three metastatic brain tumors in terms of patient survival advantage

Key Question #2 – Washington State Health Care Authority

What are the potential harms of SRS and SBRT compared to conventional external beam radiation therapy (EBRT)? What is the incidence of these harms? Include consideration of progression of treatments in unnecessary or inappropriate ways.

It is Elekta's opinion that the Gamma Knife provides significant clinical advantages over EBRT for the treatment of brain metastases, rather than the reverse. The addition of SRS to EBRT extends survival. The addition of EBRT to SRS has been found to produce neurocognitive decline. A paper In Lancet by Eric Chang of MD Anderson *(Chang, E.L., et al., Neurocognition in patients with brain metastases treated with radiosurgery or radiosurgery plus whole-brain irradiation: a randomised controlled trial. Lancet Oncol, 2009. 10(11): p. 1037-44)* reported on a randomized controlled trial which was actually stopped early as it was apparent that patients treated with "SRS plus WBRT were at a greater risk of a significant decline in learning and memory function by 4 months compared with the group that received SRS alone." Dr. Chang concluded that in the case of newly diagnosed brain metastases, "Initial treatment with a combination of SRS and close clinical monitoring is recommended as the preferred treatment strategy to better preserve learning and memory in patients".

A recent metaanalysis conducted by Tsao et al *(Tsao, M., W. Xu, and A. Sahgal, A meta-analysis evaluating stereotactic radiosurgery, whole-brain radiotherapy, or both for patients presenting with a limited number of brain metastases. Cancer, 2011.)* concluded "for selected patients with up to 4 brain metastases eligible for SRS, our meta-analysis concludes no OS benefit for WBRT plus SRS boost compared with SRS alone despite significant gains in both local and distant brain tumor control with WBRT. SRS alone may allow patients to optimally retain their neurocognitive function, experience fewer serious late side effects, and are not at adverse risk with respect to maintaining performance status. Therefore, we conclude that SRS alone with frequent magnetic resonance imaging (MRI)-based follow-ups in order to salvage recurrent brain metastases before symptomatic manifestations, should be routinely offered to selected patients as a treatment option to consider.

Other research which discusses the relative benefit of omitting whole brain radiation due to its morbidity includes:

- *Rush, S.E., R. E.; Morsi, A.; Mehta, N.; Spriet, J.; Narayana, A.; Donahue, B.; Parker, E. C.; Golfinos, J. G., Incidence, timing, and treatment of new brain metastases after Gamma Knife surgery for limited brain disease: the case for reducing the use of whole-brain radiation therapy. Journal of Neurosurgery, 2011. 115(1): p. 37-48.*
-
- Serizawa, T.Y., M.; Sato, Y.; Higuchi, Y.; Nagano, O.; Kawabe, T.; Matsuda, S.; Ono, J.; Saeki, N.; Hatano, M.; Hirai, T., *Gamma Knife surgery as sole treatment for multiple brain metastases: 2-center retrospective review of 1508 cases meeting the inclusion criteria of the JLGK0901 multi-institutional prospective study.* Journal of Neurosurgery, 2010. 113 Suppl: p. 48-52.
-
- *Sneed, P.K.L., K. R.; Forstner, J. M.; McDermott, M. W.; Chang, S.; Park, E.; Gutin, P. H.; Phillips, T. L.; Wara, W. M.; Larson, D. A., Radiosurgery for brain metastases: is*

whole brain radiotherapy necessary? International Journal of Radiation Oncology Biology Physics, 1999. 43(3): p. 549-58.

The judicious use of SRS alone followed by close surveillance, reserving EBRT for salvage treatment or leptomeningeal disease is a paradigm followed by an increasing number of Gamma Knife sites.

Key Question #3 – Washington State Health Care Authority

What is the evidence that SRS and SBRT have differential efficacy or safety issues in sub populations? Including consideration of:

- *Gender*
- *Age*
- *Site and type of cancer*
- *Stage and grade of cancer*
- *Setting, provider characteristics, equipment, quality assurance standards and procedures.*

There has been increasing focus on developing a more tailored approach to using radiosurgery based on the patients' specific characteristics including genetic subtype. The most extensive work of this kind has been undertaken under the leadership of Dr. Paul Sperduto. His recent article on this subject (*Sperduto, P.W.K., N.; Roberge, D.; Xu, Z.; Shanley, R.; Luo, X.; Sneed, P. K.; Chao, S. T.; Weil, R. J.; Suh, J.; Bhatt, A.; Jensen, A. W.; Brown, P. D.; Shih, H. A.; Kirkpatrick, J.; Gaspar, L. E.; Fiveash, J. B.; Chiang, V.; Knisely, J. P.; Sperduto, C. M.; Lin, N.; Mehta, M., Summary Report on the Graded Prognostic Assessment: An Accurate and Facile Diagnosis-Specific Tool to Estimate Survival for Patients With Brain Metastases. Journal of Clinical Oncology, 2011*) details a sophisticated grading scheme to provide detailed prognostic information. Through analysis of over 3,000 cases from multiple institutions, it was concluded that prognosis varies by histology. The report found that "for lung cancer, prognostic factors were Karnofsky performance score, age, presence of extracranial metastases, and number of brain metastases" while "For melanoma and renal cell cancer, prognostic factors were Karnofsky performance score and the number of brain metastases. For breast cancer, prognostic factors were tumor subtype, Karnofsky performance score, and age. For GI cancer, the only prognostic factor was the Karnofsky performance score."

With regard to 'differential efficacy and safety of equipment', Elekta believes that the Gamma Knife is superior to other forms of delivering stereotactic radiosurgery. As described previously, the Gamma Knife has been designed specifically for the purpose of brain radiosurgery. Its long term accuracy is guaranteed by the manufacturer. It provides more conformal treatment than other devices with lower dose to normal brain and to the body. In support of this statement, is the article: *Ma, L.P., P.; Wang, B.; Descovich, M.; Chuang, C.; Barani, I. J.; Kunwar, S.; Shrieve, D. C.; Sahgal, A.; Larson, D. A., Apparatus dependence of normal brain tissue dose in stereotactic radiosurgery for multiple brain metastases. Journal of Neurosurgery, 2011.* ***114****(6): p. 1580-4* which assesses the relative differences of equipment (CyberKnife, Novalis and Gamma Knife) in the treatment of metastatic tumors specifically, and concludes that "The dose delivered to normal brain is strongly dependent on the radiosurgery platform", with the dose to normal brain typically 2-3 times lower for the Gamma Knife when compared to other equipment. This difference is illustrated in the following dose distribution profiles for 3, 6, 9 and 12 metastatic targets.

ELEKTA

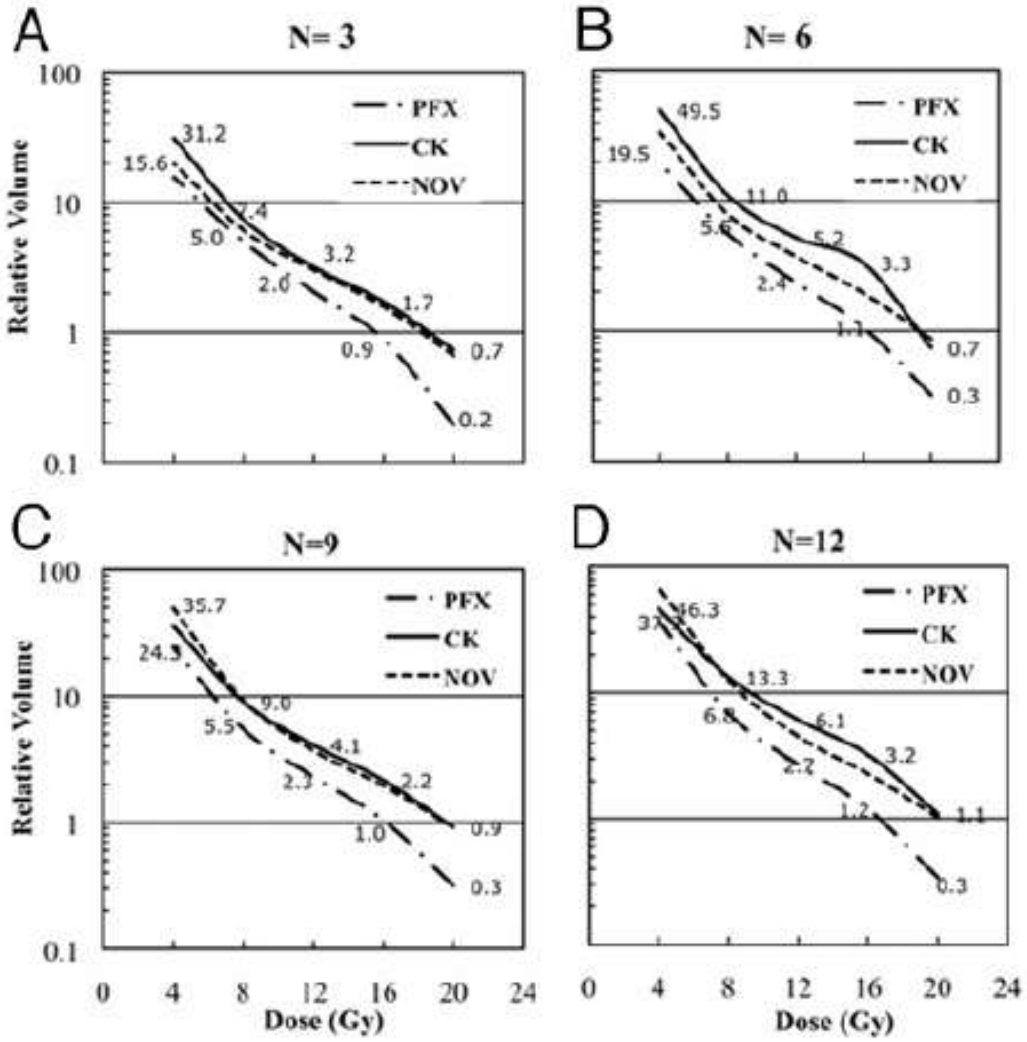

Fig. 4. Apparatus dependence of normal brain isodose volumes for multitarget treatment plans with 3 (**A**), 6 (**B**), 9 (**C**), and 12 (**D**) targets. The numbers on the curves are the normalized total target volumes for Perfexion and CyberKnife for 4, 8, 12, 16, and 20 Gy, respectively.

Ma, L.P., P.; Wang, B.; Descovich, M.; Chuang, C.; Barani, I. J.; Kunwar, S.; Shrieve, D. C.; Sahgal, A.; Larson, D. A., Apparatus dependence of normal brain tissue dose in stereotactic radiosurgery for multiple brain metastases. Journal of Neurosurgery, 2011. ***114****(6): p. 1580-4*

As described previously, the evidence base for the Gamma Knife far exceeds that for other equipment including the CyberKnife, Novalis, Tomotherapy and generic linear accelerator both with respect to number of patients treated and peer-reviewed publications.

Key Question #4 – Washington State Health Care Authority

What is the evidence of cost and cost-effectiveness of SRS and SBRT compared to EBRT?

Elekta contends that because of enhanced quality of life resulting from less whole brain radiation, the quality adjusted life years provide a cost advantage for SRS followed by surveillance.

There are a number of papers which have compared the cost effectiveness of SRS and EBRT to EBRT alone. They include:

- *Lal, L.S., et al., Cost-effectiveness Analysis of a Randomized Study Comparing Radiosurgery With Radiosurgery and Whole Brain Radiation Therapy in Patients With 1 to 3 Brain Metastases. American Journal of Clinical Oncology, 2011.*

- *Lal, L.S., et al., Economic impact of stereotactic radiosurgery for malignant intracranial brain tumors. Expert Rev Pharmacoecon Outcomes Res, 2011.* ***11****(2): p. 195-204.*

The papers conclude that " Compared with other interventions in the $50,000 to $100,000/QALY cost-effectiveness range, the application of SRS and observation, with subsequent neurosurgical management of recurrences, is shown to be a reasonable treatment modality for brain metastases."

One paper: *Lee, W.Y., et al., Outcomes and cost-effectiveness of gamma knife radiosurgery and whole brain radiotherapy for multiple metastatic brain tumors. J Clin Neurosci, 2009.* ***16****(5): p. 630-4* specifically addressed the issue of multiple brain metastases and concluded that for 2-5 tumors "GKRS results in a better post-treatment KPS score, QALY, and higher cost-effectiveness than WBRT for treating multiple metastatic brain tumors."

International RadioSurgery Association
P.O. Box 5186
2960 Green Street, Suite #100
Harrisburg, PA 17110
T 717.260.9808
F 717.260.9809

June 25, 2012

RE: WA Health Technology Assessment SRS and SBRT

To whom it may concern:

IRSA (International RadioSurgery Association) appreciates the opportunity to provide comments on the assessment of Stereotactic Radiosurgery (SRS) and Stereotactic Body Radiation Therapy (SBRT). IRSA has operated since 1995 as an association which represents, among others, the gamma and linear accelerator stereotactic radiosurgery unit's installation base. Installations of this type are primarily hospital based and specialize in treating both brain tumors and brain disorders. The Association's mission is to provide education and guidance on radiosurgery to governments, regulatory agencies, insurers, patients and referring physicians. This is accomplished through providing practice guidelines, position statements, general literature, and comments on issues affecting operations or patient safety.

Until the late 2000s, Stereotactic Radiosurgery, by definition, was a single surgical procedure that takes advantage of an energy source that can be focused through tissue without incising it. Since then, 'short' fractions of generally five (5) or less utilizing high level technology (CyberKnife,® BrainLab, Novalis® and others) have commonly been accepted as part of the SRS definition. Radiosurgery may be gamma or linear accelerator based. Radiosurgery occurs in lieu of or as an adjunct to open skull surgery and is normally limited to intracranial locations. A multi-disciplinary team normally makes the decision whether to offer SRS. The team usually consists of a neurosurgeon, a radiation oncologist and a physicist.

IRSA's comments will be directed at SRS (defined as one-session or short fractions) and CNS tumors (intracranial lesions and disorders) at this time. We have no information or comments on SBRT or non-CNS tumors.

KQ1:
Stereotactic Radiosurgery has over 2,500 scientific articles supporting its use with CNS tumors and disorders over the use of external beam radiation therapy (EBRT), which in general may result in up to 30 fractions of radiation targeted over healthy brain tissue. These articles attest to significant outcomes when SRS is compared to EBRT for CNS tumors and disorders. We direct your attention to the selection of *evidence based* Radiosurgery Guidelines which are a part of this document. Each evidence based guideline was drafted and reviewed by a panel of committee members that consisted of both physicians who provide SRS and those who do not provide SRS. Each committee was composed of multidisciplinary specialties including neurosurgeons, radiation oncologists, physicists, and other medical specialties where appropriate (neurologists, endocrinologists and neurotologists, among others). We have included the patient related criteria to be considered when deciding whether SRS is appropriate and an algorithm for each diagnosis.

Acoustic Neuroma (Research References—110):
Patient factors to consider:

- Age and symptoms
- Tumor anatomy (intracanalicular)
- Brain stem compression and/or hydrocephalus
- Hearing status
- Current neurological status
- Medical condition
- Presence or absence of Neurofibromatosis 2
- Presence or absence of prior procedures
- Concern and risk tolerance for hearing, facial and trigeminal nerve function

The associated clinical algorithm suggests *microsurgery (open skull surgery), SRS and observation* dependent on the patient and his/her associated criteria. You will note that EBRT is not an option in this algorithm because EBRT would not be appropriate for the diagnosis.

Intracranial Arteriovenous Malformations (AVM) (Research References—84):
Patient factors to consider:

- Patient's medical condition
- Previous bleed(s)
- Prior procedures
- Volume of AVM
- Location of AVM
- Presenting symptoms

The associated clinical algorithm suggests *microsurgery (open skull surgery), embolization and SRS* dependent on the patient and his/her associated criteria. You will note that EBRT is not an option in this algorithm because EBRT would not be appropriate for the diagnosis.

Metastatic Brain Tumors (Research References—135):
Patient factors to consider:

- Patient's age and symptoms
- Status of systemic disease
- Patient's current neurological status
- Patient's medical condition and functioning level
- Presence or absence of other organ metastases
- History of prior whole brain radiation therapy (WBRT)
- History of prior brain procedures
- Patient's concern and risk tolerance for neuro-cognitive functions

The associated clinical algorithms suggest *biopsy, microsurgery (open skull surgery), SRS and EBRT (singly or in combination). EBRT in this algorithm is defined as WBRT or XRT. Whether to utilize SRS or EBRT radiation is highly dependent on the patient and his/her associated criteria.* EBRT may be utilized to momentarily delay the formation of new CNS metastases, but will not provide quality of life or extended survival for the patient.

Trigeminal Neuralgia Refractory to Medical Treatment (Research References—62):
Patient factors to consider:

- Patient's age
- Patient's medical condition
- Presence or absence of multiple sclerosis
- Presence or absence of vascular contact and/or compression on thin section MRI

- Presence or absence of prior procedure
- The type of prior procedure and its response
- Severity of pain and how long the patient can reasonably wait for pain relief

The associated clinical algorithm suggests *retro-mastoid craniotomy, microvascular decompression, percutaneous retrogasserian rhizotomy (by glycerol, radiofrequency or balloon compression) and/or SRS* dependent on the patient and his/her associated criteria. These procedures are for patients in which medications have not provided relief. EBRT is not appropriate to treat the diagnosis of Trigeminal Neuralgia and is not supported by research.

Pituitary Adenomas (Research References—70):
Patient factors to consider:

- Patient's age
- Hormonal status of the adenoma (secretory or non-secretory)
- Presenting symptoms and neurological status (vision) of the patient
- Patient's medical condition (comorbidities)
- Previous tumor resection (via trans-sphenoidal approach or craniotomy) history
- Prior radiation exposure
- Volume of the tumor
- Proximity to the optic apparatus
- Response to medical management

The associated clinical algorithm suggests *open skull surgery, adrenalectomy, dopamine agonists, octreotide, GH receptor antagonists, other medical interventions, and SRS* dependent on the patient and his/her associated criteria. When the patient is unsuitable for both surgery and SRS, then EBRT (preferably IMRT which is more focused) may be an option.

We encourage this technology board to review the complete and full narrative guideline for each indication which can be found at http://irsa.org/guidelines.html and on the National Guideline Clearinghouse website (NGC.gov). In this response to the questions we have only included parts of each guideline that were specifically addressed in the key questions. IRSA is currently updating all guidelines and preparing new ones for Essential Tremor, Meningiomas, and Gliomas. We are proud to state that many insurers utilize our guidelines in their coverage policies for their covered lives.

KQ2:
Unlike EBRT, SRS restricts the radiation of healthy tissue by restricting the targeting of the radiation to the tumor bed with negligible overlap to healthy tissue. Therefore by definition, EBRT is more harmful than SRS.

SRS and SBRT have been shown in research to provide the following positive effects over EBRT:

- Better local tumor control
- Extended survival
- Stable and improved functioning score (Karnofsky)
- Fewer complications
- Better quality of life
- Immediate return to work
- Easier procedure times by weeks
- Less burden on family to provide access and travel for EBRT versus a one session procedure
- Less staff and resource utilization by hospitals (1–5 procedures versus 30 procedures)
- No issues with fatigue, nausea or other effects of EBRT
- EBRT may result in more progression of disease or be simply inappropriate for CNS indications
- EBRT has been shown to rarely result in new tumors and reduce intellect where children are concerned

- There is also evidence that EBRT may cause permanent 'brain fog' in CNS patients, thus lowering their survival quality of life
- EBRT within the brain will only work to limit the progression of existing 'seeding' of tumors to the brain or spine. Within a few months after EBRT treatment, new tumors can appear from seeding of the systemic cancer. At that time, EBRT can usually not be repeated and SRS and SBRT are the only procedures available to the patient.

KQ3:
Please review our guidelines and answers to KQ1. Patient criteria for utilization of SRS are clearly provided. Except with CNS metastases or malignant tumors, EBRT may be totally inappropriate for benign brain tumors and CNS disorders. In children, EBRT can result in permanent intellectual issues. It should be noted that EBRT can be utilized only once with CNS tumors. Since SRS does not spread radiation throughout the brain and is focused, it can be utilized more than one time and after EBRT has failed.

The CNS system can be damaged by EBRT. Acute and subacute transient symptoms may develop early but progressive, permanent, often disabling nervous system damage may not appear for months to years. The total radiation dose, size of the fractions, duration of therapy, and volume of [healthy brain] nervous tissue irradiated influence the likelihood of injury. Considerable variation in individual susceptibility complicates the effort to predict safe radiation doses.

Acute reactions occur during or immediately after radiation. They are normally caused by swelling and can be easily controlled with medications. Delayed or late reactions are normally permanent and can be progressive. They can vary from mild to severe and may include decreased intellect, memory impairment, confusion, personality changes and more. All symptoms would be dependent on the amount of healthy tissue targeted with radiation.

Oncogenesis, the development of another tumor caused by radiation treatment to the brain, is now a recognized, although rare, possible long-term side effect of EBRT to the brain.

EBRT may target wide areas of the brain resulting in more neurotoxicity. Significant neurotoxicity has been reported with the use of EBRT. Acute effects include hair loss (alopecia), nausea, vomiting, lethargy, otitis media and severe cerebral edema. Though some of these effects can be transient, dermatitis, alopecia, and otitis media can persist for months after irradiation. Chronic effects are even more serious, and these include atrophy, leukoencephalopathy, radiation necrosis, neurological deterioration and dementia.

Reports of development of severe radiation induced dementia have varied between 11% in one-year survivors to 50% in those surviving two years. The time involved in this therapeutic intervention frequently is two to six weeks, in itself a burden to many patients.

We now know that new tumors may again 'seed' to the brain within a few months of having completed whole brain radiation. Thus the treatment may only help for one point in time. Unlike radiosurgery or conformal radiotherapy, there is a limit to how much whole brain radiation therapy a person may have. This is usually 6000 gray.

EBRT is the most damaging of all types of radiation treatments and causes the most severe side effects in the long run to patients. In the past, patients who were candidates for whole brain radiation were selected because they were thought to have limited survival times of less than 1–2 years and other technology did not exist. Patients in good survival status (more than 18 months) may need to question the use of EBRT as a first line of defense when one-session radiosurgery or multi-session stereotactic radiotherapy can be repeated for original tumors or used for additional tumors with little or no side effects from radiation to

healthy tissues. Major studies and research have shown that the benefits of radiosurgery and stereotactic radiotherapy are more effective than EBRT, without the side effects.

KQ4A: Costs
IRSA surveyed its member hospitals regarding the CPT codes they use for SRS, SBRT and EBRT. We have provided the information for each of these procedures. In our analysis we used the codes which more than 50% of members reported using for a service. While there was some variation, we noted that differences would not have changed the overall ranking and results. We applied Medicare reimbursement amounts to each CPT code, so that the services for SRS, SBRT, and EBRT would be comparable. Medicare determines what it deems to be costs by utilizing the Hospital Medicare Cost Report to determine a rate that approaches cost. With this method there are no differences in the cost results of the analysis, whether the procedure is intracranial or a body treatment. We found the following results for a complete course of treatment for each method and have provided the detailed analysis for your review:

SRS Intracranial Only Technical Costs, 1 Session Cobalt Gamma Knife®	$ 9,385
SRS/SBRT Image Guided Robotic Technical Costs, 1 Session Linac	$ 9,269
SRS/SBRT Image Guided Robotic Technical Costs, 5 Fractions Linac	$19,456
EBRT 10 Sessions Technical Costs (Becoming more Common)	$11,533
EBRT 15 Sessions Technical Costs (Most Common)	$14,103
EBRT 30 Sessions Technical Costs (Not as Common)	$21,603

We submit to the Technology Assessment group that the costs above are only the facility/technical costs and do not include professional costs. EBRT would have the highest professional costs over the one or five sessions SRS/SBRT when the resources of the physicians for EBRT (which is given over days and weeks) are added to the facility costs above.

KQ4B: Cost Effectiveness
Our association believes it is clear that SRS/SBRT is less costly than EBRT both in monetary figures and in damage to the patient. SRS and SBRT have been shown in research to provide the following positive effects over EBRT:

- Better local tumor control
- Extended survival time
- Stable and improved functioning score (Karnofsky)
- Fewer complications
- Better quality of life
- Minimal cognitive impairment
- Immediate return to work
- Shorter procedure times by weeks
- Less burden on family to provide access to and travel for a one session procedure versus EBRT
- Less staff and resource utilization by hospitals (1–5 procedures versus 30 procedures)
- No issues with fatigue, nausea or other effects of EBRT
- EBRT may result in more progression of disease or be simply inappropriate for CNS indications
- EBRT has been shown to rarely result in new tumors and reduce intellect in children
- There is also evidence that EBRT may cause permanent 'brain fog' in CNS patients, thus lowering their survival quality of life
- EBRT within the brain will only work to limit the progression of existing 'seeding' of tumors to the brain or spine. Within a few months after EBRT treatment, new tumors can appear from seeding of the systemic cancer. At that time, EBRT can usually not be repeated and SRS and SBRT (which can be utilized several times because of the sparing of healthy tissue) are the only procedures available to the patient.

SRS Intracranial/Technical Costs for 1 Session Delivery [Cobalt]

Gamma Knife® RadioSurgery

Note: Does not include Professional Fees

Medicare reimbursement is used as a comparator to costs. Medicare does not seek to reward treatments but to reimburse for the costs of the procedure. (Source: Member Centers 20+)

Total Medicare Reimbursement for one session Cobalt (Gamma Knife®)

	No. Times	MC Rate	Total
77295	1	$955	$955
77334	3	200	600
77470	1	395	395
77300	1	107	107
77370	1	107	107
77371	1	107	7221

TOTAL for One Session Cobalt ***$9,385***

The Hospital's Specific Wage Base is added to the above number.

SRS Intracranial Procedure Facility Costs for One Session & Five Sessions

Image Guided Robotic RadioSurgery -- Linac

CyberKnife®, Novalis®, Rapid Arc®, Synergy® and others

Note: Does not include Professional Fees

Each provider treats each patient on a case by case basis and the following may vary. Medicare reimbursement is used as a comparator to costs. Medicare does not seek to reward treatments but to reimburse for most of the cost. (Source: Survey of 15 member sites,)

		Times			
Pre Treatment Simulation for EBRT					
77401	CT for placment of fields	1	955	$955	
77290	Complex Simulation	1	264	264	
77334	Immobilizaton frame/body fixatio	4	200	800	
77333	Bite Block Custom	2	200	400	
77470	Special TX Procedure	1	395	395	
Pre Treatment review of above films and software					
77295	3-D Planning	1	955	955	
77301	Inverse Planning	1	955	955	
77370	Physics Consult	1	107	107	
First Session Day					
77290	Verify Day of Treatment	1	264	264	
77334	Beam Modification Devices Verfie	4	200	800	
G0339	Treatment Delivery Single Fraction	1	3374	3374	
	TOTAL for One Session				***$9,269***
2nd through 5th Session Day					
G0340	Robotic Delivery 2-5 day	4	2520	10080	
77336	On-going Physics	1	107	107	
	Total for 2nd through 5th Fractions				**$10,187**
	TOTAL for 5 Fractions				***$19,456***

The Hospital's Specific Wage Base is added into the above number.

EBRT Facility/Technical Costs Treatments

Note: Does not include Professional Fees

Each provider treats each patient on a case by case basis and the following may vary. While EBRT may be done over 30 treatments, there is growing information that 15 treatments to 30 gy is becoming the norm. Therefore we have utilized a 15 day treatment. Medicare reimbursement is used as a comparator to costs. Medicare does not seek to reward treatments but to reimburse for most of the cost. (Source: Survey of 12 member sites,)

Pre Treatment Simulation for EBRT

77401	CT for placment of fields	Multiple
77290	Complex Simulation	
77334	Immobilizaton frame/body fixation	Multiple
77333	Bite Block Custom	Multiple
77470	Special TX Procedure	

Pre Treatment review of above films and software

77295	3-D Planning	
77300	Dose Calculations	Multiple
77370	Physics Consult	

First Treatment Day through last Treatment Day		**15 days**
77290	Verify Day of Treatment	Weekly and Pre Tx
77334	Beam Modification Devices Verfied daily	Daily
77336	On-going Physics Billed weekly	Weekly
77305-315	Teletherapy Isodose Plans	Daily
77401-77416	Treatment Delivery by complexity and voltage	Daily

Total Medicare Reimbursement assuming 15 days of EBRT:

	No. Times	MC Rate	Total
77295	1	$955	$955
77290	5	264	1320
77334	16	200	3200
77310	16	107	1712
77333	4	200	800
77401	3	99	297
77470	1	395	395
77300	8	107	856
77370	1	107	107
77336	3	107	321
77305-315	15	107	1605
77408*	15	169	2535

TOTAL for 15 Sessions EBRT	***$14,103***	***EBRT 15 Sessions***
TOTAL for 10 Sessions EBRT	***$11,533***	***EBRT 10 Sessions***
Estimated TOTAL for 30 Sessions	***$21,603***	***EBRT 30 Sessions***

The Hospital's Specific Wage Base is added into the above number.

* 77408 Treatment Delivery: Intermediate – 2 separate treatment areas. Three or more ports to each area, multiple non-complex devices For 6-10 MeV machines.

Summary:
As documented by the evidence based guidelines IRSA developed for intracranial diagnoses, SRS, SBRT and EBRT **all** have a place in the treatment of these formidable diseases and conditions. Only by assessing the patient's condition, functioning level, prior procedures, location of the offending tumor or disorder, can an assessment be made as to what procedure(s) and when are best for the patient. As we have tried to note here, there are disease processes where EBRT is clearly not a choice and SRS and SBRT are. We should not forget that patients also have the right to choose and decide what is best for themselves and their quality of life, as well as their survival time. We would like to stress, there is little difference from our analysis of these techniques for intracranial diagnoses and for body diagnoses.

While all can benefit from SRS and SBRT, it is of great concern to our Association that the elderly and the working poor have the opportunity to avail themselves of one or few session SRS and SBRT procedures. These two groups have much to gain from these procedures.

We hope this information will be useful to you in the assessment of SRS, SBRT and EBRT. We would be pleased to ask one of our Board members that works in the State of Washington to speak to your panel if it would be beneficial. Please take the time to obtain our full guidelines which contain formerly written narratives of the evidenced based research supporting our algorithm(s) in the guidelines.

Yours Sincerely,

Rebecca L Emerick/e-sign

Rebecca L. Emerick, MS, MBA, CPA
IRSA – International RadioSurgery Association
Executive Director
P.O. Box 5186
Harrisburg, PA 17110
+717-260-9813

Partial Guideline Attachments

Radiosurgery[1] Practice Guideline Initiative

DISEASE/CONDITION: *Vestibular Schwannoma (acoustic neuroma)*

Radiosurgery[1] Practice Guideline Report # 4-06

GROUP COMPOSITION:

This radiosurgery guidelines group is comprised of neurosurgeons, neurotologists, and radiation oncologists.

Names of Group Members: L. Dade Lunsford, M.D., Neurosurgeon, Chair; Ajay Niranjan, M.B.B.S., M.Ch., Neurosurgeon; Georg Norén, M.D., Neurosurgeon; Jay Loeffler, M.D., Radiation Oncologist; Alain de Lotbinière, M.D., Neurosurgeon; Jordan Grabel, M.D., Neurosurgeon; Douglas Kondziolka, M.D., Neurosurgeon; Jean Régis, M.D., Neurosurgeon; Pierre-Hughes Roche, M.D., Neurosurgeon; Robert Smee, M.D., Radiation Oncologist; Neurosurgeon; Burton Speiser, M.D., Radiation Oncologist; Mark Alden, M.D., Radiation Oncologist; Sandra Vermeulen, M.D., Radiation Oncologist; William F. Regine, M.D., Radiation Oncologist; Barry Hirsch, M.D., Neurotologist; Tonya K. Ledbetter, M.S., M.F.S., Editor; Rebecca L. Emerick, M.S., M.B.A., C.P.A., ex officio.

NUMBER OF REFERENCES: 110

Clinical Algorithm

A number of patient related factors are considered in making a recommendation. These factors include:

- Patient desires
- Tumor size and anatomy
- Current impairment
- Patient's decision after informed consent

Preoperative Hearing Level

Opinions vary considerably about what constitutes useful hearing. The 50/50 rule is frequently quoted. The rule suggests that individuals with a pure-tone average greater than 50 dB and speech discrimination less than 50% do not have useful hearing.

Tumor Anatomy

Radiosurgery can be performed for intracanalicular tumors and small to medium size tumors without brainstem compression and without signs of hydrocephalus. If hydrocephalus is present in old or infirm patients, a shunting procedure should be considered in addition to radiosurgery. There is no broadly accepted classification of tumor volumes. In addition to tumor diameter, Koos classification[46] is useful because it takes into account the mass effect of the tumor on the brainstem. Koos IV tumors (large tumors with brain shift) with a main diameter less than 3 cm should be offered microsurgery as first management. For intracanalicular tumors, hearing level may influence the decision.[7] Some authors believe that for tumors with a predominant cystic component microsurgery may be more suitable.

Patient Preference

Patients' preference is also considered in selecting a management approach. Some patients prefer tumor removal rather than tumor stabilization. Some patients are willing to sacrifice good hearing if doing so even slightly enhances the possibility of complete tumor removal. For these patients tumor resection is an obvious choice. Many patients prefer effective non-invasive management techniques like radiosurgery. Some patients insist on hearing conservation even when the treating physician is quite convinced that the patient's preoperative hearing is non-serviceable.

Neurofibromatosis 2
Considerations in NF2 patients may be different and additional parameters such as contralateral hearing, previous treatment, lip reading acquisition and additional tumors should be taken into account.

Management Algorithm for Acoustic Tumors

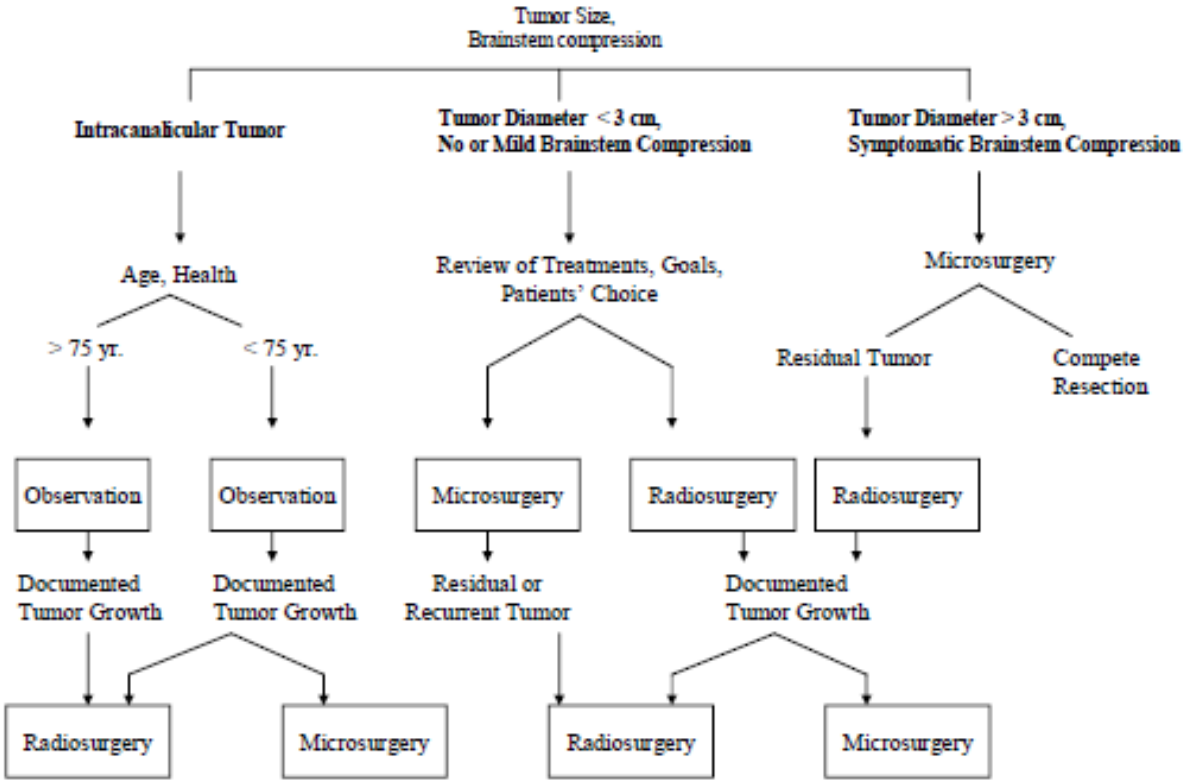

Go to www. IRSA.org/guidelines for a full copy of the guideline and references

[1] Radiosurgery is defined as one session or short fractions of 5 or less.

DISEASE/CONDITION: *Intracranial Arteriovenous Malformations (AVM)*
Radiosurgery[1] Practice Guideline Report #2-03

COMPOSITION OF GROUP THAT AUTHORED THE GUIDELINE

The radiosurgery guidelines group is comprised of neurosurgeons, radiation oncologists and physicists. Community representatives did not participate in the development of this guideline.

Committee Members: L. Dade Lunsford, M.D., Neurosurgeon, Chair; Douglas Kondziolka, M.D., Neurosurgeon; Ajay Niranjan, M.B.B.S., M.Ch., Neurosurgeon; Christer Lindquist, M.D., Neurosurgeon; Jay Loeffler, M.D., Radiation Oncologist; Michael McDermott, M.D., Neurosurgeon; Michael Sisti, M.D., Neurosurgeon; John C. Flickinger, M.D., Radiation Oncologist; Ann Maitz, M.S., Medical Physicist; Michael Horowitz, M.D., Neurosurgeon and Interventional Radiologist; Tonya K. Ledbetter, M.S., M.F.S., Editor; Rebecca L. Emerick, M.S., M.B.A., C.P.A., ex officio.

References: 84

Clinical Algorithm

A number of factors are considered in making a recommendation. These factors include:

- Patient's age
- Patient's medical condition
- Previous bleed
- Prior procedures
- Volume of AVM
- Location of AVM
- Presenting symptoms

Intracranial Arteriovenous Malformation Management Algorithm

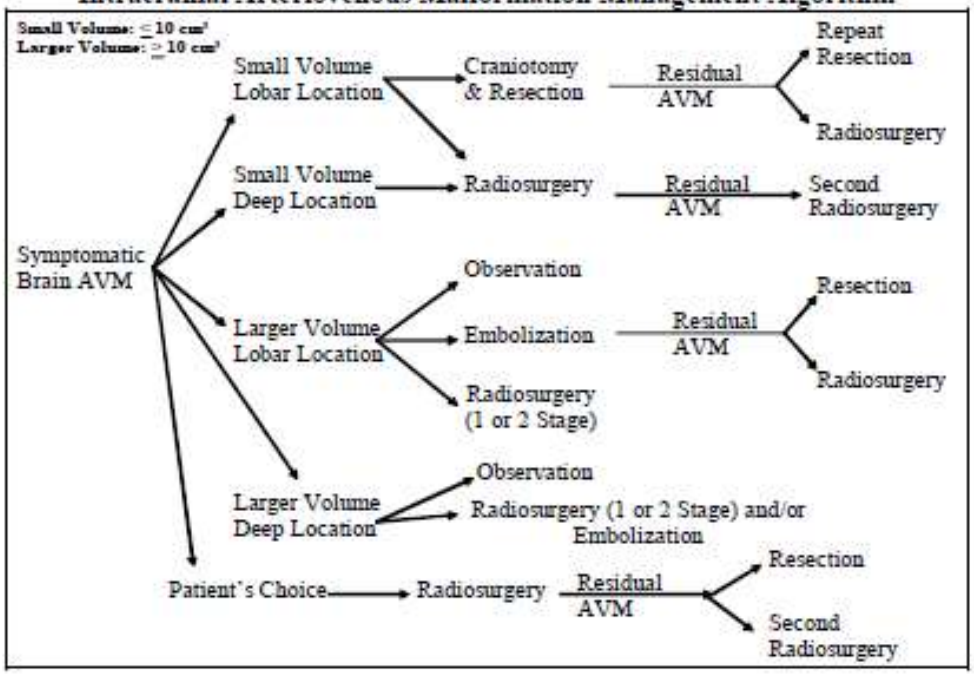

Go to www. IRSA.org/guidelines for a full copy of the guideline and references

[1] Radiosurgery is defined as one session or short fractions of 5 or less.

DISEASE/CONDITION: *Metastatic Brain Tumors*

Radiosurgery[1] Practice Guideline Report # 5-08

Group Composition

The radiosurgery guidelines group is comprised of neurosurgeons, neuro-oncologists, radiation and medical oncologists and physicists. Community representatives did not participate in the development of this guideline.

Names of Group Members: Ajay Niranjan, M.B.B.S., M.Ch., Neurosurgeon, Chair; L. Dade Lunsford, M.D., Neurosurgeon; Richard L. Weiner, M.D., Neurosurgeon; Gail L. Rosseau, M.D., Neurosurgeon; Gene H. Barnett, M.D., F.A.C.S., Neurosurgeon; Massaki Yamamoto, M.D. Neurosurgeon; Lawrence S. Chin, M.D., F.A.C.S., Neurosurgeon; Paul J. Miller, M.D., Radiation Oncologist; Andrew E. Sloan, M.D., Neurosurgeon; Burton L. Speiser, M.D., Radiation Oncologist; Sandra S. Vermeulen, M.D., Radiation Oncologist; Harish Thakrar, M.D., Radiation Oncologist; Frank Lieberman, M.D., Neuro-Oncologist; David Schiff, M.D., Neuro-Oncologist; Sammie R. Coy, Ph.D., Medical Physicist; Tonya K. Ledbetter, M.S., M.F.S., Editor; Rebecca L. Emerick, M.S., M.B.A., C.P.A., ex officio.

References: 135

Clinical Algorithm

Several factors are considered in making a recommendation. These factors include:

- Patient's age
- Patient's symptoms
- Status of systemic disease
- Patient's current neurological status
- Patient's medical condition
- Presence or absence of other organ metastases
- History of prior WBRT
- History of prior brain procedures
- Patient's concern and risk tolerance for neuro-cognitive functions
- Patient's wishes

Tumor Size

Radiosurgery can be performed for tumors up to 4 cm in maximum diameter. However, tumor volume, dose and location are more important variables.

Patient Preference

Patients' preferences are also considered in selecting a management approach.

A broad outline of brain metastases diagnostic work-up and management algorithms for single tumor, limited brain disease (2–4 tumors) and multiple metastases are shown. However, the final recommendation is usually influenced by the recommending surgeon's, radiation oncologist's and neuro-oncologist's experiences along with patient preference.

Metastatic Brain Tumors Continued

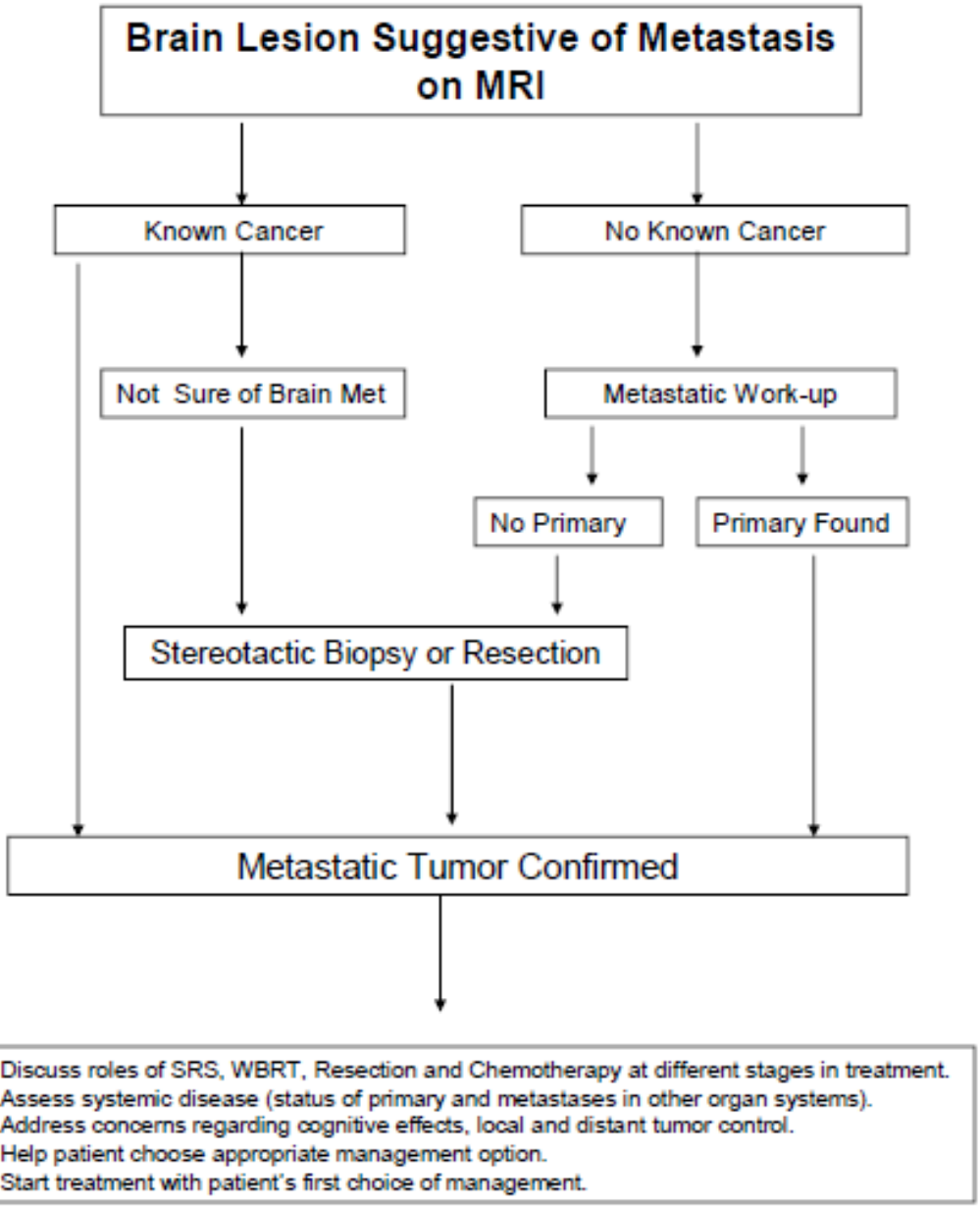

Metastatic Brain Tumors Continued

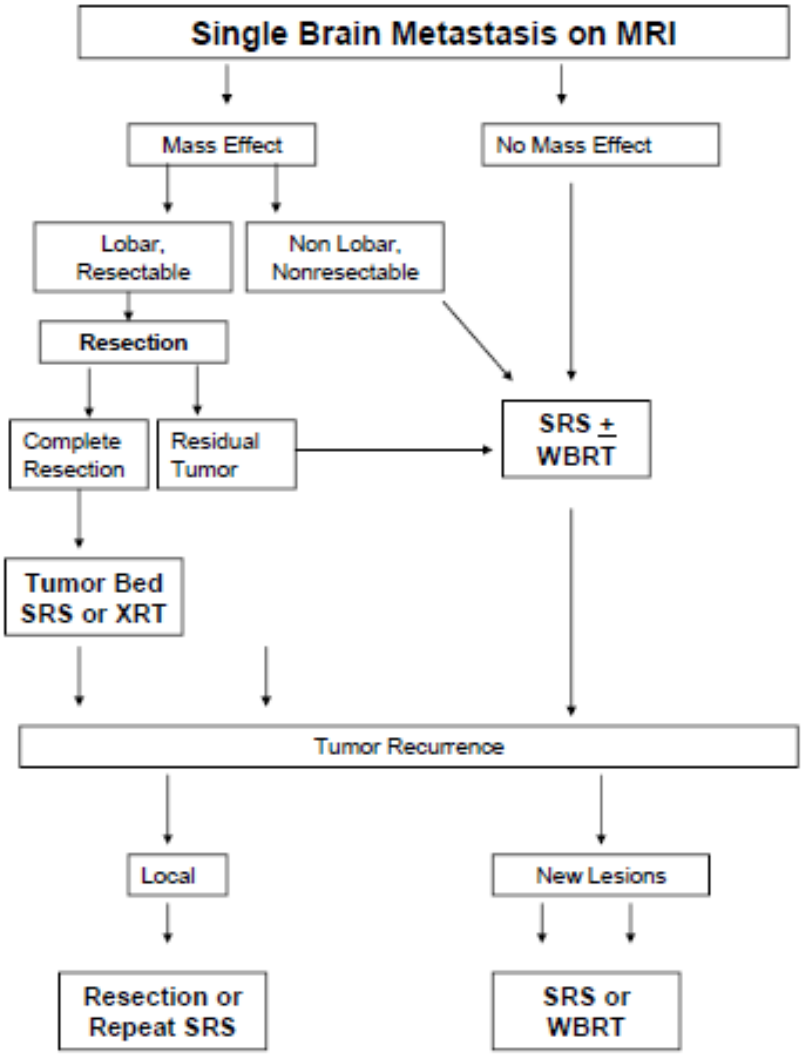

Metastatic Brain Tumors Continued

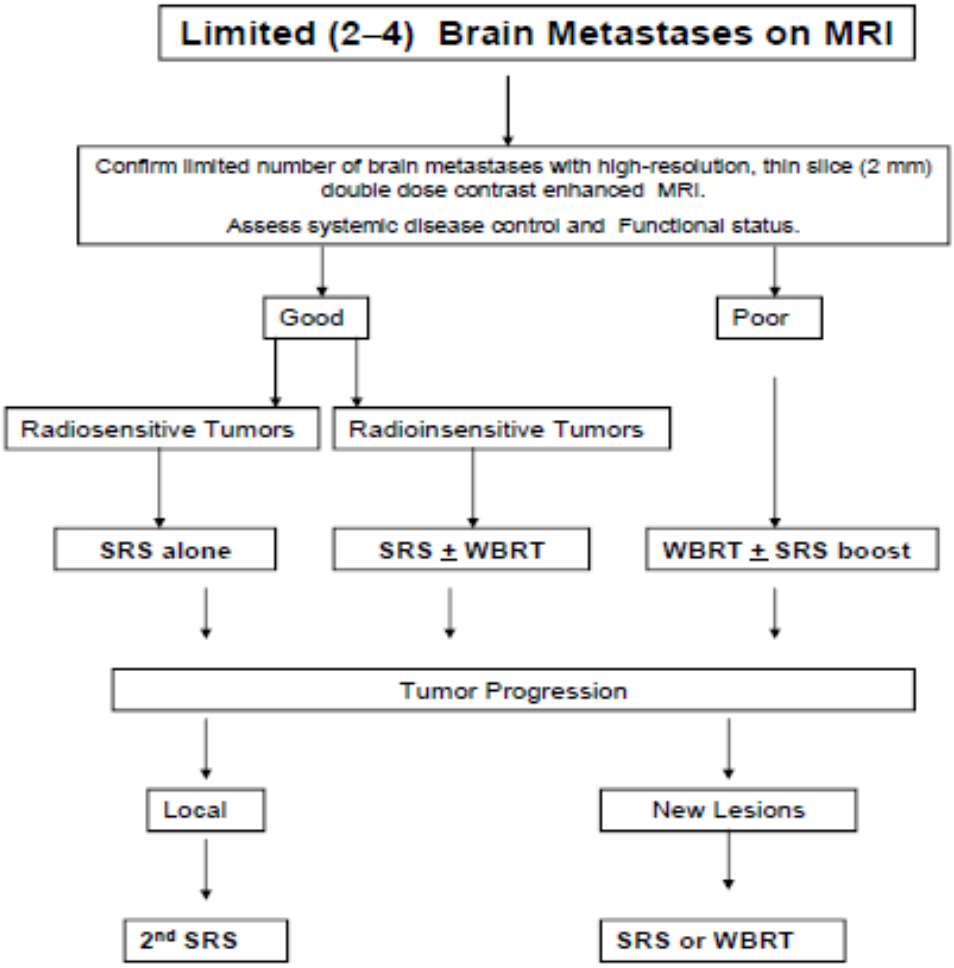

Metastatic Brain Tumors Continued

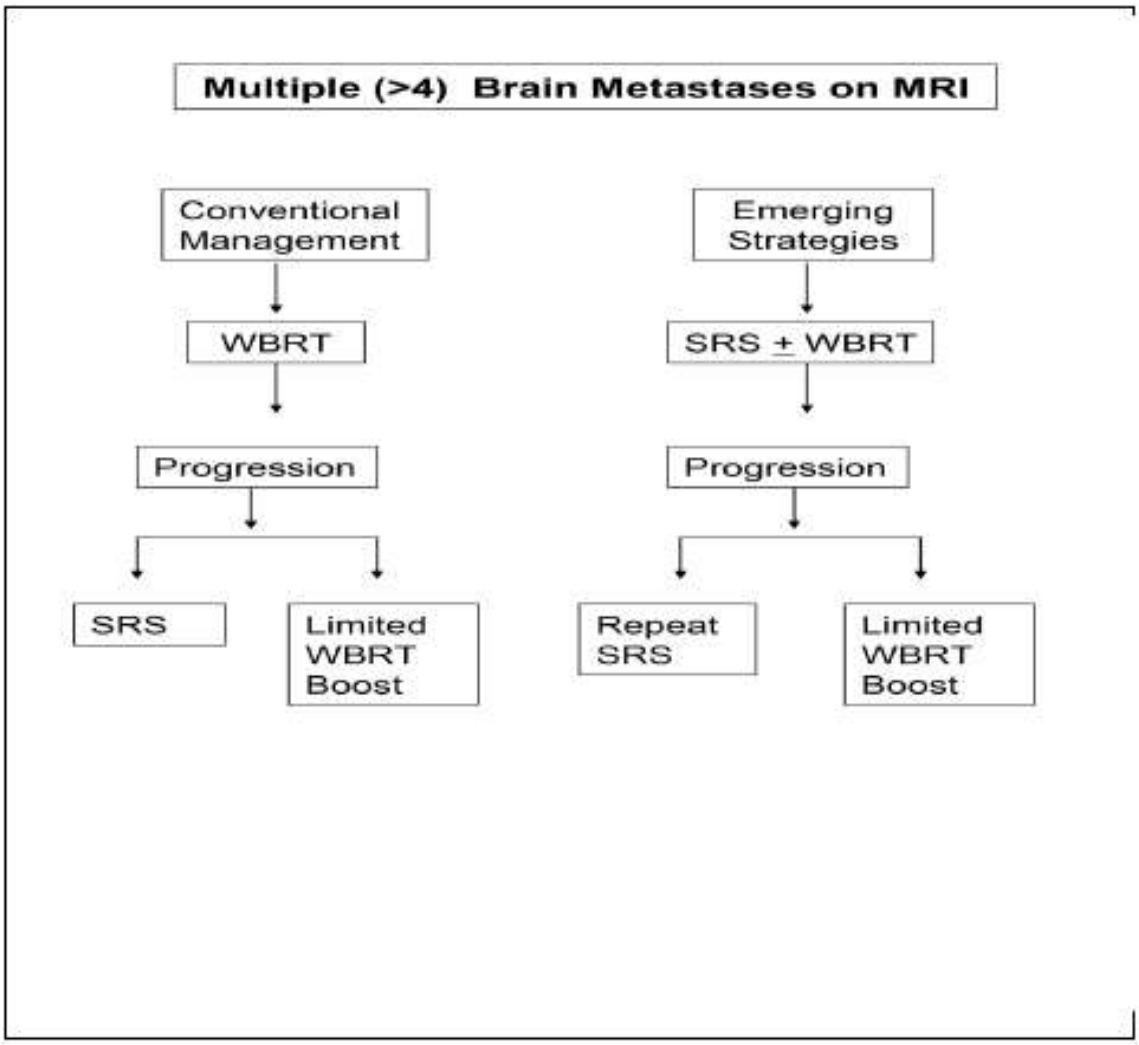

Go to www. IRSA.org/guidelines for a full copy of the guideline and references

[1] Radiosurgery is defined as one session or short fractions of 5 or less.
[2] WBRT is defined as external beam radiation therapy in up to 30 fractions.

DISEASE/CONDITION: Intractable Typical Trigeminal Neuralgia who have failed Medical Management

Radiosurgery[1] Practice Guideline Report #1-03

Group Composition:
The radiosurgery guidelines group is comprised of neurosurgeons, radiation oncologists and physicists. Community representatives did not participate in the development of this guideline but will in future updates.

Names of group members: Drs. L. Dade Lunsford, M.D., Neurosurgeon, Chair; Ajay Niranjan, M.B.B.S., M.Ch., Neurosurgeon; Ron Young, M.D., Neurosurgeon; Ronald Brisman, M.D., Neurosurgeon; David Cunningham, M.D., Neurosurgeon; Christer Lindquist, M.D., Neurosurgeon; David Newell, M.D., Neurosurgeon; John C. Flickinger, M.D., Radiation Oncologist; Ann Maitz, M.S., Medical Physicist; Rebecca L. Emerick, M.S., M.B.A., C.P.A., "ex officio."

References: 62

CLINICAL ALGORITHM(S):

A number of factors are considered in making a recommendation. These factors include:

- Patient's age
- Patient's medical condition
- Presence or absence of multiple sclerosis
- Presence or absence of vascular contact and/or compression on thin section MRI
- Presence or absence of prior procedures
- The type of prior procedure and its response
- Severity of pain and how long the patient can reasonably wait for pain relief
- Patient's concern and risk tolerance for dysesthesias, recurrence, or complications from surgery

A broad outline of management algorithm is shown below, however, the final recommendation is usually influenced by the recommending neurosurgeon's experience.

Intractable Typical Trigeminal Neuralgia Continued

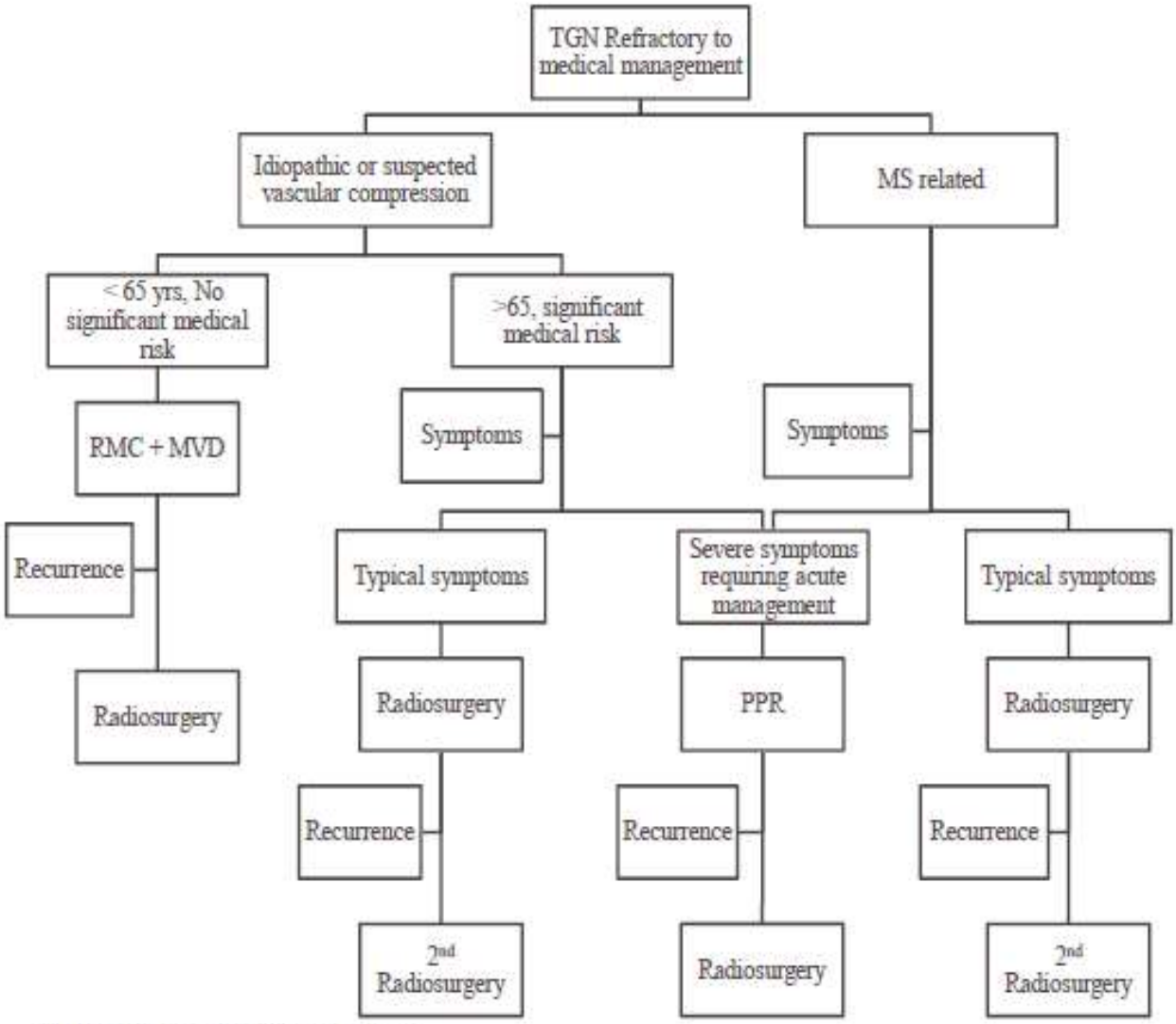

RMC = Retro-Mastoid Craniotomy,
MVD = Microvascular decompression,
PRR = Percutaneous Retrogassarian Rhizotomy (Glycerol / Radiofrequency / Balloon compression)

Go to www. IRSA.org/guidelines for a full copy of the guideline and references

Radiosurgery/SRS = Defined as one session, short fractions are not supported by research at this time.

DISEASE/CONDITION: *Pituitary Adenomas*

Radiosurgery[1] Practice Guideline Report #3-04

Group Composition

The Radiosurgery Guidelines Committee is comprised of neurological surgeons, radiation oncologists, physicians, endocrinologists and medical physicists.

Names of Group Members: L. Dade Lunsford, M.D., Neurosurgeon, Chair; Ajay Niranjan, M.B.B.S., M.Ch., Neurosurgeon; Tatsuya Kobayashi, M.D., Ph.D., Neurosurgeon; Mark Linskey, M.D., Neurosurgeon; Thomas Witt, M.D., Neurosurgeon; Alex Landolt, M.D., Neurosurgeon; Roman Liscak, M.D., Neurosurgeon; Edward R. Laws Jr., M.D., Neurosurgeon; Mary Lee Vance, M.D., Endocrinologist; John Buatti, M.D., Radiation Oncologist; Jonathan Knisely, M.D., Radiation Oncologist; Paul Sperduto, M.D., Radiation Oncologist; Sammie Coy, Ph.D., Medical Physicist; Tonya K. Ledbetter, M.S., M.F.S., Editor; Rebecca L. Emerick, M.S., M.B.A., C.P.A., ex officio.

References: 70

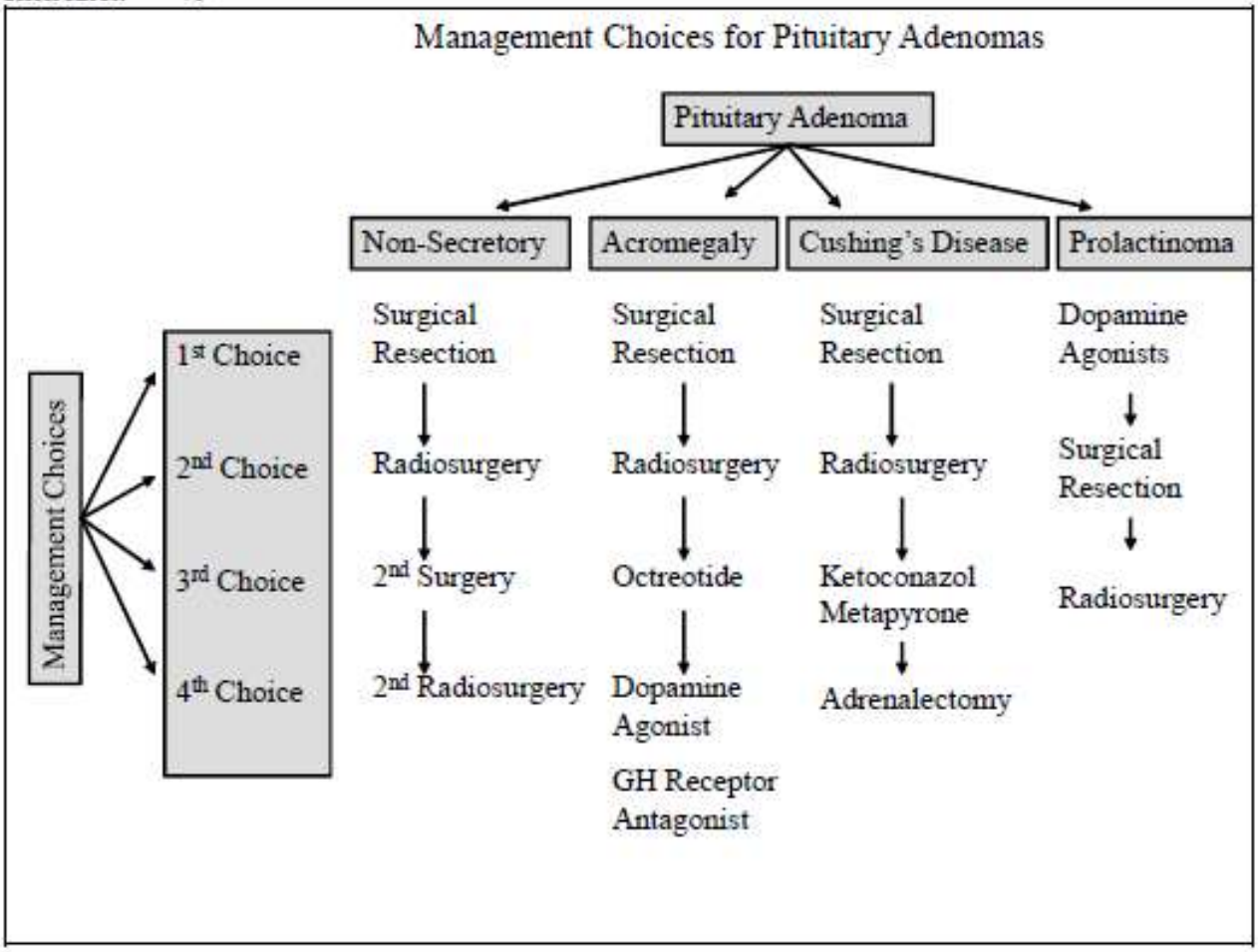

Pituitary Adenomas Continued

Management considerations

A number of factors are considered in making a recommendation regarding management of Pituitary Adenomas. These factors include:

- Patient's age
- Hormonal status of the adenoma (secretory or non-secretory)
- Presenting symptoms and neurological status (vision) of the patient
- Patient's medical condition (comorbidities)
- Previous tumor resection (via trans-sphenoidal approach or craniotomy) history
- Prior radiation exposure
- Volume of the tumor
- Proximity to the optic apparatus
- Response to medical management

Pituitary Adenoma Management Algorithm

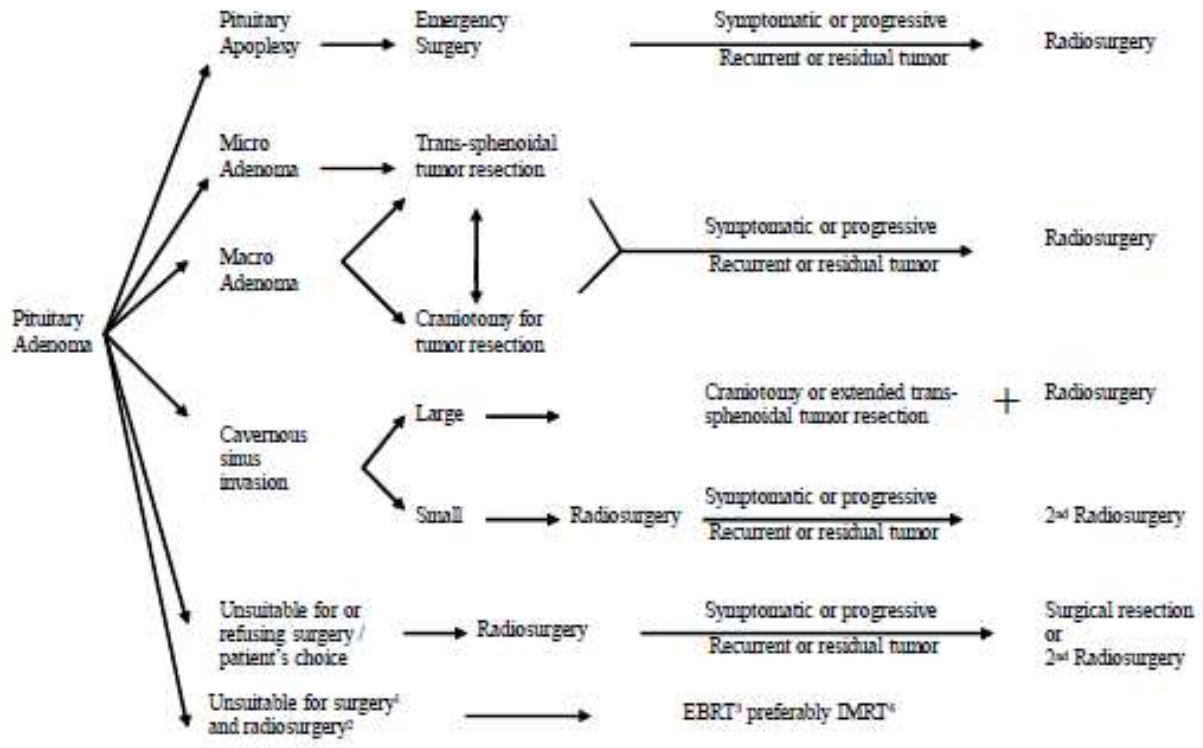

[1] High risk for general anesthesia, [2] Tumor too large, [3] External Beam Radiation Therapy, [4] Intensity Modulated Radiation Therapy

Radiosurgery/SRS = Defined as one session. Short fractions are not supported by research at this time.

Go to www. IRSA.org/guidelines for a complete copy of the guideline, which includes a discussion of the research and a listing of all references

From: Nancy Lang

To: HCA ST Health Tech Assessment Prog
Cc: cbonetti@accuray.com
Subject: CyberKnife radiosurgery safety and funding comments
Date: Friday, March 02, 2012 4:45:40 PM

2 March 2012

I am a 70 year old woman with ovarian cancer. My first diagnosis was in December 2004 with surgery and complete hysterectomy, followed in January 2005 by chemotherapy, a combination of carboplatin and taxol. My cancer returned in 2007 with a duplication of the previous chemotherapy and, in 2010 another round of chemotherapy with an addition of Avastin.

In 2011, after a reaction to the carbo and taxol, I continued on a different treatment option of cisplatin and gemsidibine while waiting for approval for CyberKnife radiosurgery. I selected to go with CyberKnife because a new tumor, detected in a November 2010 PET –CT showed the location in the *periportal region*. Surgery in this area is not a good option.

After receiving marker fiducials my CyberKnife treatment began the end of February over a period of five treatments. I had neither pain nor any negative reaction during or after my treatment.

A November 2011 follow-up PET-CT displayed a recurrence in *aortocaval lymph nodes*, requiring additional treatment. After three medical opinions clearly stating that, because of the location of the recurrence, surgery was not an option and chemo was taking a toll on my body, CyberKnife would be the best treatment.

With my health insurance approval we started treatment January 3, 2012 for five days. I walked daily, after each treatment, and continue to do so. I felt nothing during the treatment, maybe one slow day when I felt a little tired but, in general I feel perfectly normal.

With my experience, I can highly vouch for the value of CyberKnife treatment process and recommend it be funded by all health care programs.
Sincerely,

Nancy Lang
808 Golf Course Road
Port Angeles, WA 98362
(360) 452-4348
nancyplang@yahoo.com

UPMC | University of Pittsburgh Medical Center

University of Pittsburgh Physicians
Department of Neurological Surgery

February 26, 2012

School of Medicine

L. Dade Lunsford, MD, FACS
Lars Leksell Professor
University of Pittsburgh

Residency Director

Director
Center for Image-Guided Neurosurgery

UPMC Presbyterian
Suite B-400
200 Lothrop Street
Pittsburgh, PA 15213-2582
412-647-6781
Fax: 412-647-6483

Washington State Healthcare Authority
Health Technology Assessment
Email: shtap@hca.wa.gov

RE: Stereotactic Radiosurgery

Dear Sirs:

It gives me pleasure to be able to comment directly upon the current evaluation under your auspices related to stereotactic radiosurgery. I serve as chair of the Technology Assessment Committee for UPMC (a 9 billion dollar integrated delivery system in Western Pennsylvania), chair of the Medical Advisory Board of the International Radiosurgery Association (IRA) and chair of the North American Gamma Knife Consortium. As an individual, I have spent a large part of my academic career in the field of minimally invasive surgery. I would like to provide the following data:

1. Stereotactic radiosurgery is an integral part of the field of neurosurgery with collegial interaction with the field of radiation oncology. At our center, more than 11,300 patients have undergone Gamma Knife stereotactic radiosurgery over the last 25 years since we placed the first Leksell Gamma Knife in North America.

2. Stereotactic radiosurgery is used for approximately 20% of all brain indications for intervention at our center with an increasing role in the management of metastatic cancer, arteriovenous malformations, chronic pain especially related to trigeminal neuralgia, glial neoplasms, and a wide variety of skull-based tumors including pituitary tumors.

3. In the last 25 years, more than 5000 outcome studies have been published related to Gamma Knife radiosurgery, and it is approved for use by all insurance providers. This type of technique has been a radical transformation in the management of patients with a wide variety of otherwise frequently fatal brain conditions. Because of its superior technology and minimally invasive nature, patients are often done as an outpatient and can return to regular activities on the following day. Therefore, quality assessment, comparative outcomes research, and cost effectiveness research have substantiated the role of this technology in a wide variety of indications.

I hope this information will be useful to you in the assessment of this technology which has resulted in radical improvements in healthcare delivery across the world.

Yours sincerely,

L. Dade Lunsford, M.D.

LDL/jt #155162

19917 Seventh Avenue, Suite 100
Poulsbo, WA 98370
(360) 697-8000
www.peninsulacancercenter.com

3/5/12

Mr. Josh Morse, MPH, Program Director and the
Health Technology Assessment Program Board & Staff
Washington State Health Care Authority
P.O. Box 42712
Olympia, Washington 98504-2712

Dear Mr. Morse and Members of the Board and Staff:

We have received copies of the letters that Dr. Todd Barnett and his associates at the Swedish Cancer Institute have written in support of Intensity Modulated Radiotherapy (IMRT) and Stereotactic Radiotherapy (SRT), currently under review by your board. We have reviewed their letters and supportive documents and applaud their work and endorse their recommendations that IMRT and SRT/SBRT are important treatment techniques that benefit cancer patients while being safe and cost effective. IMRT and stereotactic radiotherapy are techniques that have been in common use in most radiation therapy centers for greater than 10 years; it would be impossible to think of not utilizing these advanced techniques for patients with conditions that warrant such treatment. We are hopeful that your review will support the continued utilization of these beneficial treatment techniques.

Please do not hesitate to contact us for more information or questions.

Respectfully,

Berit L. Madsen, MD, FACR
Clinic Director
R. Alex Hsi, MD
Heath R. Foxlee, MD

From: Zemanek, Julie
To: HCA ST Health Tech Assessment Prog
Cc: Willis, Brett; "James.Dingels@swedish.org"
Subject: HTA Program Response
Date: Monday, March 05, 2012 2:56:14 PM
Attachments: 2012 0305 DGM RDS Letter to State.docx
120304 Vermeulen Letter to the State CNS Tumors 2-29-12.doc
2012 03 MPH Supporting Doc IMRT.docx

Thank you for allowing Tacoma/Valley Radiation Oncology Centers the opportunity to provide responses to Key Questions, which are attached.

Should you have any questions, please feel free to contact me.

Julie J. Zemanek | Practice Manager
253.627.6172 (main) | 253.779.6328 (direct) | 253.627.5967 (fax)
Jackson Hall Medical Center

CONFIDENTIALITY NOTICE: This e-mail, including attachments, is intended solely for the entity or individual to whom it was addressed and may contain information that is confidential, legally privileged and protected from disclosure. Any unauthorized review, use, disclosure or distribution is prohibited. If you are not the intended recipient, please delete this message and notify the Privacy Official @ 253.627.6172. Thank you.

March 5, 2012

Mr. Josh Morse, MPH, Program Director
Health Technology Assessment Program Board & Staff
Washington State Health Care Authority
PO Box 42712
Olympia, WA 98504-2712

Dear Mr. Morse, Members of the Board and Staff:

I am writing this letter as part of a public response to the state regarding the healthcare technology program (HTA) policies that are currently being drafted.

I am a radiation oncologist who is in a large multicenter practice that covers most of the south sound. We are free standing and independent cancer centers. We are very familiar with the technologies of Intensity Modulated Radiation Therapy (IMRT), stereotactic radiosurgery (SRS) and stereotactic body radiotherapy (SBRT) that the healthcare technology program is now looking at. I can speak from a position of complete familiarity with these treatment modalities.

These technologies are currently available in many places in the State of Washington and are quickly becoming standard of care for many treatment sites throughout the nation. As clearly stated in the summary, these technologies are more expensive than conventional radiation. The trade off, however, is very significant when it comes to not only improvements in outcomes but they are vastly superior in reduction in side effects and toxicity. We are also able to treat specific tumor locations that we never were able to accomplish in the past with minimal morbidity and harm to the patient. There is no question that radiation can be extremely harmful to living tissue. My 20+ year career can certainly attest to that. When I explain these new modalities to patients, one of the very first comments I make is that I wish I'd had these technologies available to me during the early days of my career. The number of patients treated with significant radiation morbidity, both short term and long term, in the form of bowel damage, bladder damage, lung damage, soft and bony structure damage as well as even brain damage, could have been reduced and outright avoided if I'd had these technologies available in the past. These newer modalities allow us to target tissues at risk and greatly reduce surrounding tissues that do not need to be radiated. Not only do these technologies

allow us to target the cancer and spare the surrounding normal tissue, but they allow us to give even higher doses of radiation to the cancer, thus improving outcomes. Nowhere has this become more evident than in treatment of cancer of the prostate. The concept of increasing the dose of radiation (known as dose escalation) to prostate cancer has been verified in numerous clinical trials. In the past we were unable to deliver high doses of radiation to the prostate because the organ is "sandwiched" between the bowel and the bladder.

The use of IMRT actually allows us to bend the radiation around these crucial structures, therefore allowing us not only to spare these normal tissues but allowing us to give more radiation to the prostate, thus improving the outcomes in the long term and ultimately curing the patient of his cancer. IMRT has become standard of care for most tumor sites.

I sit down on a day to day basis and explain the treatment course to a patient which is often combined with very extensive chemotherapy. I am now able, with confidence, to say to patients that they will make it through treatment with greatly minimized side effects that we have seen in the past. Above all, as stated in the Hippocratic Oath, is to "do no harm." All cancer therapy walks a fine line between trying to eradicate the patient's malignancy without destroying normal tissue. IMRT and other related technologies have allowed us to increase the "therapeutic window" to accomplish that goal, increasing radiation and decreasing side effects. Until the so-called "Magic Bullet" is invented for cancer therapy, this is one of the most significant breakthroughs in radiation therapy in the 20th century. To simply say that we can treat cancers using standard therapy brings us back to the 1980s, a time when we only dreamed about having the ability to eradicate tumors without eradicating the patient in the process.

Stereotactic body (SBRT) and stereotactic radiosurgery (SRS) are again technologies that allow us with pin-point accuracy to deliver very toxic doses of radiation therapy to cancers and eliminate surrounding tissue. One only needs to see a patient who is trying to live with radiation damage of the brain from old conventional treatments to realize the significance of these new technologies. We are now able to treat patients non-surgically for aneurysms, tremors, brain metastases and even gliomas. Patients are alive and function today because of these technologies. They certainly can be treated by more conventional means but the price is higher in side effects and long-term complications. I have seen patients harmed by conventional radiation to a much greater extent.

I have another patient whom I am currently treating as I write this letter. She is not a surgical candidate. She has a large metastasis to her liver. She is unable to go through a big procedure. There is no other means of treating this metastasis. Her options are either to fight her disease or simply let nature take its course. If faced with that situation, I would do the same thing and fight for my survival. IMRT and stereotactic body radiosurgery offer the chance of fighting cancer. I cannot pass judgment on whether or not these treatments are useful unless faced with that same situation.

It is very difficult from this letter or from reading the literature to pass judgment on any of this unless you come in and experience it for yourself.

I welcome anyone involved in reviewing this information to please visit our center. I would be more than happy to sit down for as long as needed to explain the differences between conventional radiation therapy and modern technologies of Intensity Modulated Radiation Therapy and the others listed above. I can show you examples and even have you talk to patients. We can search the literature together and find you examples of their utility. I would be more than happy to sit on any review committee and assist anyone in the field currently, gathering data and researching the information. I am available any time you should require.

Our free-standing cancer center's goal is to give the best possible treatment to our patients. Our mission statement is precisely that. Utilizing these technologies allows us to accomplish that mission statement. There is no question that these modern technologies are expensive. As a free-standing center, we can keep our costs to a minimum.

Sincerely,

Dean G. Mastras, MD Randy D. Sorum, MD

President

RadiantCare

Joseph R. Hardman, MD
James F. Raymond, MD
Haleigh A. Warnes, MD
Gregory W. Allen, MD, PhD

March 5, 2012

Mr. Josh Morse, MPH, Program Director and the Health Technology Assessment
Program Board and Staff
Washington State Health Care Authority
P.O. Box 42712
Olympia, Washington, 98504-2712

Dear Mr. Morse and Members of the Board and Staff:

Thank you for allowing us to comment on the Key Questions that where raised pertaining to Stereotactic Radiosurgery (SRS) and Stereotactic Body Radiation Therapy (SBRT). I will be speaking for all members of RadiantCare Radiation Oncology in the following correspondence. Due to the short time frame allowed to comment we have chosen to collaborate with the Tumor Institute Radiation Oncology Group (TIROG) in our response.

We share your concerns pertaining to patient safety, effectiveness, efficiency and the rising cost of contemporary radiation treatment modalities. We have instituted a group designated to address these issues as they relate to the treatment of the patients of RadiantCare.

SRS and SBRT are both extremely precise treatment modalities which can be delivered with a Linear Accelerator, Gamma Knife or Cyberknife system. These systems are designed to precisely target tumor regions with millimeter accuracy. These treatments require intense quality assurance, measurements and monitoring during treatment since the entire dose is delivered through 1-5 treatments. This requires a significant amount of medical physicist support to ensure accuracy.

We believe that the initial increased cost associated with IMRT, SRS and SBRT is outweighed by their long term savings due to lower costs associated with lower risk of side effects and increased clinical outcomes.

KQ1; What is the effectiveness for SRS and SBRT compared to conventional external beam radiation therapy (EBRT) for patients with cancer by site and type of cancer.

There is extensive documentation in the literature to support the role of SRS and SBRT. There are studies showing support for CNS/spine, prostate, head and neck, gastrointestinal, liver, pancreas, and lung cancers to name a few. These studies include primary, metastatic, boost and previous irradiated areas. If you would like us to provide you with an extensive list of the citations please let us know.

KQ2: What are the potential harms of SRS/SBRT compared to conventional external beam radiation therapy (EBRT)? What is the incidence of these harms? Include consideration of progression of treatment in unnecessary or inappropriate ways.

Highly conformalized treatment is needed when treating an area that has been previously irradiated. Tissue that has been previously treated is less tolerant to radiation and the normal tissues must be minimized to reduce unnecessary side effects. The rapid dose fall of SRS or SBRT is a perfect option in this setting. The exhaustive patient positioning, planning and delivery process are required to ensure that the procedure is done correctly.

KQ3: What is the evidence that SRS/SBRT has differential efficacy or safety issues in subpopulations? Including consideration of:

a. Gender
b. Age
c. Site and type of cancer
d. Stage and grade of cancer
e. Setting, provider characteristics, equipment, quality assurance standards, and procedures.

SRS/SBRT is capable of treating a vast array of cancers in a variety of locations, for both genders and all ages. These modalities are utilized in freestanding centers and hospitals which allows access to patients everywhere. In some instances, one of these two treatments may be the only options available to the patient due to the tumor location and circumstances. Advanced quality assurance standards and measurements are published to perform SRS/SBRT.

KQ4: What is the evidence of cost and cost-effectiveness of SRS/SBRT/ IMRT compared to EBRT?

Cost effectiveness between EBRT and SRS/SBRT is a very difficult study to quantify due to the quality of life that is being compared. Conventional EBRT is delivered over an average of 2-6 weeks while SRS/SBRT is delivered over 1-5 treatments. Cost and cost effectiveness can be measured in loss of work, cost of treatment, cost of side effect management (acute and long term), or indirect costs but these indirect savings can be difficult to accurately compare.

As is always the case, we choose the most appropriate treatment modality for each patient's specific case. We evaluate all of our treatment options and determine which will offer the patient the best clinical outcome with the least amount of side effects.

We encourage any questions you may have about this topic. Please feel free to contact any of us.

Regards,



James F. Raymond MD
Clinical Director of Radiosurgery
RadiantCare Radiation Oncology

From: Eric W. Taylor, MD

To: HCA ST Health Tech Assessment Prog
Cc: Eric W. Taylor, MD
Subject: Public Comment for: Stereotactic Radiation Surgery and Stereotactic Body Radiation Therapy
Date: Sunday, February 26, 2012 3:29:15 PM

Thank you for the opportunity to comment.
Stereotactic Radiosurgery has been used for certain brain malignancy situations as well as for some benign diseases. The clinical experience is well and heavily reported in the literature. My main concern for overuse of SRS is in the patient with brain metastases. The National Comprehensive Cancer Network guidelines (nccn.org) are clear that this technique is appropriate for patients with 1-3 brain metastases and with disease reasonably controlled or stable elsewhere...so that the cost of such treatment could be justified in well selected patients. Unfortunately, I think that there is OVERUSE of SRS and IMRT for patients with multiple brain metastases whose ultimate outcomes and lives are unfortunately very limited.

The use of Stereotactic Body Radiation Therapy (SBRT) or Stereotactic Ablative Radiation Therapy (SABR) are becoming of increasing usefulness and benefit. The Japanese data for early lung cancer treatment with SBRT is excellent and from an outcome perspective is competitive with surgery. There is a current randomized trial sponsored by the American College of Surgeons and the Radiation Therapy Oncology Group comparing SBRT/SABR versus surgery. Depending on the outcomes of this study, this might support increased use of SBRT in the future. Currently, SBRT is the standard of care (National Comprehensive Cancer Network Guidelines at nccn.org) for early lung cancers in the patient that is medically inoperable. If well planned and delivered, patients tolerate this therapy very well with excellent reports from the current literature (Japan, UT Southwestern, Indiana and others).

Respectfully submitted,

Eric Taylor MD, FACR, FACRO
Evergreen Radiation Oncology
Evergreen Healthcare
Kirkland, Wa

Sent from my iPad

DISCLAIMER:
Evergreen Healthcare Confidentiality Notice: This email message, including any attachments, is for the sole use of the intended recipient(s) and may contain confidential and privileged information. Any unauthorized review, use, disclosure or distribution is prohibited. If you are not the intended recipient, please contact the sender by e-mail and destroy all copies of the original message or you may call

Evergreen Healthcare in Kirkland, WA U.S.A at (425)899-1740.

Submitted from the Tumor Institute Radiation Oncology Group:

Stereotactic Radiosurgery (SRS), Stereotactic Body Radiation Therapy (SBRT) and Key Question 4 IMRT Reimbursement Information

Thank you for the opportunity to comment on questions regarding Intensity Modulated Radiation Therapy (IMRT), Stereotactic Radiosurgery (SRS), and Stereotactic Body Radiation Therapy (SBRT). We recognize that approximately half of all cancer patients receive some form of radiation therapy, and that radiation dose delivery techniques and practices have rapidly evolved over the last decade.

As experts in the field of Radiation Oncology, we embrace your concerns regarding safety, efficacy, and cost of contemporary radiation modalities. Technologies such as IMRT, SRS, and SBRT have broken new ground in their capability to control cancer and minimize side effects. Our goal is to help educate health providers and healthcare payers, as well as government, business, and other professionals as to the patients for whom use of these newer technologies can mean a world of difference in regard to cancer control and a decreased risk of treatment related side effects.

The utility of IMRT, SRS, and SBRT in many circumstances is very specifically dependent on a patient's cancer, their anatomy, the proximity of critical structures, and prior radiation dose delivered. The key aspects that all these modalities have in common is better dose distributions: escalated doses to tumors, lower doses (and lower resultant toxicity) to normal tissue. Using IMRT, SRS, and SBRT, it is now potentially feasible to deliver safe curative or safe palliative treatment to many patients where treatment was not even an option with conventional external beam radiation therapy. For example, in cases where tumors recur in a previously irradiated field, re-irradiation with IMRT, SRS, or SBRT may deliver a long term cure that was not previously possible. We realize that a circumstance such as this is not one in which a comparative trial could be conducted, for most of these patients simply would not be a candidate for treatment with a conventional external beam radiation therapy approach.

We believe that it is imperative to be able to offer these treatments to patients in an expedient time frame when indicated. We remain readily available and encourage an open dialogue on these topics. We have tried our best given the short comment period to address your questions regard SBRT and SRS.

Although there are increased costs associated with newer technologies such as IMRT, SRS, and SBRT, their effectiveness and lower risk for side effects demonstrates long term cost

savings. As well, the relevant key comparison is often IMRT, SRS, or SBRT in comparison to other different modalities of treatment, such as surgery, or radiofrequency ablation (rather than to conventional external beam irradiation). For example, there was a publication a few months ago comparing the cost effectiveness, quality of life and safety for medically inoperable lung cancer patients. The study compared conventional radiation, SBRT, and radiofrequency ablation. SBRT was by far the most effective and cost effective treatment, even though it may have the highest upfront direct cost (reference: [1] Sher, Wee and Punglia, **Cost-effectiveness analysis of stereotactic body radiotherapy and radiofrequency ablation for medically inoperable, early-stage non-small cell lung cancer**. Journal/Int J Radiat Oncol Biol Phys, 81, e767-74, 2011).

Given the extraordinarily short time period for comment, we have done our best to summarize responses to the four key questions of the Washington State Healthcare Authority with regard to SRS, and SBRT in comparison to conventional (conformal) external beam therapy (EBRT). We must emphasize, though, while there are many well done peer reviewed studies from top academic institutions pertinent to IMRT, SRS and SBRT, and in some cases there are head-to-head comparisons which demonstrate the benefits of this technology, the short response timeframe created by your March 6th deadline, which apparently is not negotiable, does not allow adequate time to research. Therefore, we want to be sure the Washington State Healthcare Authority and its staff are advised that we believe the key questions posed for SRS, SBRT and IMRT are extensive and a more complete level of detail is not possible to produce within the time frame allotted.

KQ1: What is the effectiveness for SRS and SBRT compared to conventional external beam radiation therapy (EBRT) for patients with cancer by site and type of cancer.

RESPONSE:

Prostate – SBRT

A conventional radiotherapeutic treatment for prostate cancer consists of 8-9 weeks of daily external beam radiotherapy (EBRT) – such treatment is typically implemented with IMRT and daily image guidance, which helps align the patient prior to delivering each fraction of treatment. An alternative approach is prostate brachytherapy – using either a high dose rate (HDR) delivery system, or the implantation of approximately 100 permanent radioactive seeds. These procedures require anesthesia, and for HDR brachytherapy, hospitalization. Often brachytherapy is combined with a five week course of IMRT.

A newer method of delivering radiotherapy is called "stereotactic body radiotherapy" (SBRT); this differs from conventional radiotherapy in several important ways. First, SBRT uses new technology to deliver radiotherapy with extreme precision. Second, the target is treated from numerous different beam angles, which concentrates dose to the target and minimizes dose to surrounding organs. By contrast, EBRT/IMRT commonly uses 4-7 beam angles, treating from a single rotational plane. Finally, the extreme accuracy and rapid dose fall-off of SBRT allows very high doses of radiation to be safely delivered to the cancer in 1-5 fractions. The CyberKnife is an SBRT platform that uses robotic technology to adjust in real-time for patient and organ motion, thus treating with an accuracy of less than 1mm.

In order to account for prostate motion during EBRT/IMRT treatment delivery, the prostate plus a 5-10mm margin around it is treated. This gives unnecessary radiation to surrounding organs. The CyberKnife is capable of tracking motion of the prostate during treatment delivery, while still treating with sub-mm accuracy (Xie et al., 2008). This exceptional accuracy minimizes radiation exposure to surrounding normal tissues (e.g., rectum and bladder). The Cyberknife can duplicate the radiation delivered with HDR brachytherapy (Fuller et al., 2007) while avoiding anesthesia, hospitalization, and trauma from numerous need punctures. Like HDR, the CyberKnife delivers dose in only a few (five) fractions.

The feasibility of CyberKnife for treating early-stage prostate cancer was first described in 2003 (King et al.), and the first clinical outcomes from Stanford University were published in 2009 (King et al.). Later that year, Friedland reported on a series of 112 prostate cancer patients treated with SBRT. In 2010, Katz published a report of 304 CyberKnife SBRT prostate patients. These publications showed exceptionally good PSA response rates, low relapse rates, acceptable toxicity, and excellent quality of life outcomes. Early results from a large multi-institutional study (Meier et. 2010) employing Cyberknife for prostate cancer recently reported acceptable toxicity and favorable PSA responses. The first 5-year SBRT outcomes have now been reported by Freeman and King (2011): toxicity was low and the rate of cancer remission was similar to other radiation modalities. Finally, the long-term outcomes of prostate SBRT at Stanford University conclude "The current evidence supports consideration of stereotactic body radiotherapy among the therapeutic options for localized prostate cancer" (King and Brooks, 2011). Thus multiple peer-review studies, including mature 5-year outcomes, have confirmed that CyberKnife SBRT is safe and effective in treating early-stage prostate cancer.

Selected reference(s):

- Xie Y, Djajaputra D. Intrafractional Motion of the Prostate During Hypofractionated Radiotherapy. *International Journal of Radiation Oncology, Biology, Physics.* 72(1), 236-246, 2008
- Fuller DB, Naitoh J et al. Virtual HDR CyberKnife Treatment for Localized Prostatic Carcinoma: Dosimetry Comparison With HDR Brachytherapy and Preliminary Clinical Observation. *International Journal of Radiation Oncology Biology Physics* 70(5),1588-97, 2007
- King CR, Lehmann J, Adler JR, Hai J. CyberKnife radiotherapy for localized prostate cancer: Rationale and technical feasibility. *Tech Can Res Treat*: 2003; 2: 25-29.
- King C, Brooks, et al. Stereotactic Body Radiotherapy for Localized Prostate Cancer: Interim Results of a Prospective Phase II Clinical Trial. *International Journal of Radiation Oncology Biology Physics*, 73(4):1043-1048 (2009).
- Friedland J, Freeman D, et al. Stereotactic Body Radiotherapy: An Emerging Treatment Approach for Localized Prostate Cancer. *Technology in Cancer Research and Treatment,* 8(5): 387-392 (2009)
- Katz A, Santor M et al. Stereotactic body radiotherapy for organ confined prostate cancer. BMC Urology, 10(1):2010
- Meier R, Beckman A et al. Stereotactic Radiotherapy for Organ-confined Prostate Cancer: Early Toxicity and Quality of Life Outcomes from a Multi-institutional Trial. *International Journal of Radiation Oncology Biology Physics*. 78(3):S57 (2010)
- Freeman D, King C. Radiation Oncology. 6(3):2011
- King CR, Brooks JD et al. Long-term outcomes for a prospective trail of stereotactic body radiotherapy for low-risk prostate cancer. *International Journal of Radiation Oncology Biology Physics*, in press (2011).

Head and Neck Cancer – SRS/SBRT

SRS and SBRT in Head and Neck cancer play a critical role in patients with locally advanced disease in the region of the skull base in multiple settings. These patients represent a small subgroup of patients for whom SRS/SBRT offer a potentially curative treatment with potentially very low risk in a situation in which historically conventional EBRT simply was not a treatment option.

Head and Neck patients for whom making access to this treatment is critical are

- Patients with recurrent cancer in a previously irradiated field.

Selected reference(s):

[2] Unger, Lominska, Deeken, Davidson, Newkirk, Gagnon, Hwang, Slack, Noone and Harter, **Fractionated stereotactic radiosurgery for reirradiation of head-and-neck cancer**. Journal/Int J Radiat Oncol Biol Phys, 77, 1411-9, 2010

- Patients with skull base invasion at the time of presentation. For these patients, a combined approach of IMRT and a radiosurgical boost with SRS or SBRT can be curative with minimal morbidity.

Selected Reference(s):

[3] Uno, Isobe, Ueno, Fukuda, Sudo, Shirotori, Kitahara, Fukushima and Ito, **Fractionated stereotactic radiotherapy as a boost treatment for tumors in the head and neck region**. Journal/J Radiat Res (Tokyo), 51, 449-54, 2010

[4] Chen, Tsai, Wang, Wu, Hsueh, Yang, Yeh and Lin, **Experience in fractionated stereotactic body radiation therapy boost for newly diagnosed nasopharyngeal carcinoma**. Journal/Int J Radiat Oncol Biol Phys, 66, 1408-14, 2006

[5] Ahn, Lee, Kim, Huh, Yeo, Lim, Kim, Shin, Park and Chang, **Fractionated stereotactic radiation therapy for extracranial head and neck tumors**. Journal/Int J Radiat Oncol Biol Phys, 48, 501-5, 2000

Central Nervous System – SRS/SBRT/IMRT

Please refer to the separate letter and commentary of Dr. Sandra Vermeulen.

CNS/Spine – SRS/SBRT

SBRT plays and increasing role in the management of patients with spinal tumors in three key settings:

- Re-irradiation of the spine.

  For patients that have undergone prior radiation therapy for spine metastases that have progression of spine disease, SBRT offers dramatic control of tumor, protection of neurologic function, and pain control

Selected reference(s):

[6] Garg, Wang, Shiu, Allen, Yang, McAleer, Azeem, Rhines and Chang, **Prospective evaluation of spinal reirradiation by using stereotactic body radiation therapy: The University of Texas MD Anderson Cancer Center experience**. Journal/Cancer, 117, 3509-16, 2011

- Treatment of radioresistant histologies.
  For patients with radioresistant cancers such as renal cell carcinoma and melanoma, conventional external beam radiation therapy offered poor durability of cancer control. With SBRT, cancer control rates are dramatically improved. With SBRT, long term pain improvement and cancer control is 75 to 100% for classically radioresistant cancers. Traditional radiation therapy offered control on average for only 1 to 3 months for radioresistant histologies.

Selected reference(s):

[7] Gerszten, Burton, Ozhasoglu and Welch, **Radiosurgery for spinal metastases: clinical experience in 500 cases from a single institution**. Journal/Spine (Phila Pa 1976), 32, 193-9, 2007

- Treatment of radioresistant tumors after decompressive surgery.
  Increasingly, patients with advanced spine disease are undergoing less invasive surgery. As demonstrated in the article cited below from Memorial Sloan Kettering, patients treated with minimal surgery followed by stereotactic radiosurgery for radioresistant tumors

[8] Moulding, Elder, Lis, Lovelock, Zhang, Yamada and Bilsky, **Local disease control after decompressive surgery and adjuvant high-dose single-fraction radiosurgery for spine metastases**. Journal/J Neurosurg Spine, 13, 87-93, 2010

Gastrointestinal/Pancreas – SBRT

For patients with unresectable pancreatic cancer, the strategy of chemotherapy and stereotactic radiosurgery has been shown to yield excellent local cancer control with low morbidity. Across these studies, tumor control ranges 85 to 95%, and late grade 3 or greater late toxicities occurred in 5 to 10% of patients. Utilizing chemotherapy and stereotactic radiosurgery, long term overall survival is approximately 20%.

Selected reference(s):

[9] Mahadevan, Miksad, Goldstein, Sullivan, Bullock, Buchbinder, Pleskow, Sawhney, Kent, Vollmer and Callery, **Induction gemcitabine and stereotactic body radiotherapy for locally advanced nonmetastatic pancreas cancer**. Journal/Int J Radiat Oncol Biol Phys, 81, e615-22, 2011

[10] Schellenberg, Kim, Christman-Skieller, Chun, Columbo, Ford, Fisher, Kunz, Van Dam, Quon, Desser, Norton, Hsu, Maxim, Xing, Goodman, Chang and Koong, **Single-fraction stereotactic body radiation therapy and sequential gemcitabine for the treatment of locally advanced pancreatic cancer**. Journal/Int J Radiat Oncol Biol Phys, 81, 181-8, 2011

[11] Chang, Schellenberg, Shen, Kim, Goodman, Fisher, Ford, Desser, Quon and Koong, **Stereotactic radiotherapy for unresectable adenocarcinoma of the pancreas**. Journal/Cancer, 115, 665-72, 2009

Gastrointestinal/Liver Metastases

Based on prior experience at this institution and other major medical centers in the United States, Europe and Asia, stereotactic body radiotherapy (SBRT) for liver metastases is effective and safe. Initial reports of phase I/II data for stereotactic body radiation to the liver metastases have been published (Schefter and Colleagues, IJROBP 2005; Kavanagh and colleagues, Acta Oncol 2006). Investigators at the University of Colorado/Denver have demonstrated 92% control of liver lesions at 2 years when treating up to 3 liver lesions. For liver tumors < 3cm, 2 year control was 100%. For this mixed population of cancer patients, median survival was 20.5 months (Rusthoven et al, JCO 2009).

More recently, data from Stanford University (Chang et al, Cancer 2011), detailed a pooled analysis on liver metastases from colorectal primary tumors similarly showing that this treatment is effective and well tolerated. On multivariate analysis, it was found that sustained local control through use of SBRT is closely correlated with overall survival. This was true even for patients heavily pretreated with chemotherapy.

SBRT for liver metastases has been best studied in “oligometastatic situations” (≤4 liver metastases). Extensive published literature exists showing that surgical resection of limited metastatic liver disease is associated with favorable outcome (Gayowski et al, Surgery 1994; Rosen et al, Ann Surg 1992; Nordlinger et al, Ann Surg 1987; Fong et al, JCO, 1997; Singletary et al, Oncologist 2003). Even in a noncurative situation, patients who do not fit this criterion can also safely derive palliative benefit from SBRT by undergoing treatment to symptomatic metastases as detailed above.

Selected reference(s):

[12] Schefter, Kavanagh, Timmerman, Cardenes, Baron and Gaspar, **A phase I trial of stereotactic body radiation therapy (SBRT) for liver metastases**. Journal/Int J Radiat Oncol Biol Phys, 62, 1371-8, 2005

[13] Kavanagh, Schefter, Cardenes, Stieber, Raben, Timmerman, McCarter, Burri, Nedzi, Sawyer and Gaspar, **Interim analysis of a prospective phase I/II trial of SBRT for liver metastases**. Journal/Acta Oncol, 45, 848-55, 2006

[14] Rusthoven, Kavanagh, Cardenes, Stieber, Burri, Feigenberg, Chidel, Pugh, Franklin, Kane, Gaspar and Schefter, **Multi-institutional phase I/II trial of stereotactic body radiation therapy for liver metastases**. Journal/J Clin Oncol, 27, 1572-8, 2009

[15] Chang, Swaminath, Kozak, Weintraub, Koong, Kim, Dinniwell, Brierley, Kavanagh, Dawson and Schefter, **Stereotactic body radiotherapy for colorectal liver metastases: a pooled analysis**. Journal/Cancer, 117, 4060-9, 2011

Gastrointestinal/Primary Liver Cancers

For primary liver lesions such as hepatocellular carcinoma (HCC) and intrahepatic cholangiocarcinoma (ICC), SBRT can also play an important role as a local ablative therapy. A multicenter report published this year (Ibarra et al, Acta Oncol, 2012) showed median time to local progression of 6.3 mo for HCC and 4.2 mo for ICC, better than historical averages for these respective diseases. 1 year survival rates were 87% and 45% for HCC and ICC, respectively. Similar data are reported in a publication by Indiana University (Andolino, IJROBP, 2011). In a separate publication by this same institution, nearly 75% of patients responded to SBRT treatment with the majority of these patients showing complete nonenhancement on followup imaging (Price et al, Cancer 2011).

For primary tumors such as HCC, the data suggests safe, effective treatment for smaller lesions such as those < 6 cm in size (Andolino, IJROBP 2011; Takeda et al, Radiother Oncol, 2012).

Selected reference(s):

[16] Ibarra, Rojas, Snyder, Yao, Fabien, Milano, Katz, Goodman, Stephans, El-Gazzaz, Aucejo, Miller, Fung, Lo, Machtay and Sanabria, **Multicenter results of stereotactic body radiotherapy (SBRT) for non-resectable primary liver tumors**. Journal/Acta Oncol, 2012

[17] Andolino, Johnson, Maluccio, Kwo, Tector, Zook, Johnstone and Cardenes, **Stereotactic body radiotherapy for primary hepatocellular carcinoma**. Journal/Int J Radiat Oncol Biol Phys, 81, e447-53, 2011

[18] Price, Perkins, Sandrasegaran, Henderson, Maluccio, Zook, Tector, Vianna, Johnstone and Cardenes, **Evaluation of response after stereotactic body radiotherapy for hepatocellular carcinoma**. Journal/Cancer, 2011

Lung – SBRT

Stereotactic body radiation therapy for lung cancer in medically inoperable patients has dramatically improved local control and survival for patients with early stage lung cancers. Historic local control of early stage, medically inoperable lung cancer was approximately 50%. In the SBRT era, cancer control rates range 85 to 98%.

In a multi institution trial, RTOG 0236 demonstrated 3 year local control of 90% in patients with medically inoperable T1-T2 lung cancer (Timmerman, JAMA, 2010). Similarly excellent results have been reiterated in multiple single institution studies in the US, as well as internationally.

As well, in the case of lung SBRT, direct comparisons to conventional radiation therapy have demonstrated superior cost effectiveness of SBRT (Sher, 2011)

Selected references:

[19] Timmerman, Paulus, Galvin, Michalski, Straube, Bradley, Fakiris, Bezjak, Videtic, Johnstone, Fowler, Gore and Choy, **Stereotactic body radiation therapy for inoperable early stage lung cancer**. Journal/JAMA, 303, 1070-6, 2010

[20] Fakiris, McGarry, Yiannoutsos, Papiez, Williams, Henderson and Timmerman, **Stereotactic body radiation therapy for early-stage non-small-cell lung carcinoma: four-year results of a prospective phase II study**. Journal/Int J Radiat Oncol Biol Phys, 75, 677-82, 2009

[21] Zimmermann, Wulf, Lax, Nagata, Timmerman, Stojkovski and Jeremic, **Stereotactic body radiation therapy for early non-small cell lung cancer**. Journal/Front Radiat Ther Oncol, 42, 94-114, 2010

[1] Sher, Wee and Punglia, **Cost-effectiveness analysis of stereotactic body radiotherapy and radiofrequency ablation for medically inoperable, early-stage non-small cell lung cancer**. Journal/Int J Radiat Oncol Biol Phys, 81, e767-74, 2011

CNS - SRS/SBRT/IMRT

Please refer to the separate letter and commentary of Dr. Sandra Vermeulen.

Re-irradiation – SRS/SBRT

Multiple lines of evidence exist showing the effectiveness and safety of using stereotactic body radiotherapy (SBRT) for re-irradiation (either for salvage or palliation).

1) Cengiz et al, IJROBP, 2010. Salvage reirradiation with stereotactic body radiotherapy for locally recurrent hand and neck tumors

2) Comet et al, IJROBP, 2012. Salvage stereotactic reirradiation with or without cetuximab for locally recurrent head and neck cancer.

3) Dworzecki et al, Noeplasma 2012. Stereotactic radiotherapy as sole or salvage therapy in non small cell lung cancer patients.

4) Heron et al, IJROBP, 2009. Stereotactic body radiotherapy for recurrent squamous cell carcinoma of the head and neck.

5) Kunos et al, Technol Cancer Res Treat, 2008. Cyberknife radiosurgery for squamous cell carcinoma of vulva after prior pelvic radiation therapy.

6) Thariat et al, Br J Radiol, 2010. Innovative image guided Cyberknife stereotactic radiotherapy for bladder cancer. (Includes previously irradiated bladder cancer patient data).

KQ2: What are the potential harms of SRS/SBRT compared to conventional external beam radiation therapy (EBRT)? What is the incidence of these harms? Include consideration of progression of treatment in unnecessary or inappropriate ways.

SRS/SBRT have been shown in multiple studies to be safe as primary treatment and in cases of re-irradiation. Specific toxicities and risks for harm vary across cancer sites and depend on the specific cancer scenarios, prior radiation dose, and anatomy as well as proximity of normal organs.

After an initial course of radiation, normal adjacent tissue has decreased tolerance to additional radiation delivered over the same region. In many cases, surgery and chemotherapy are not viable treatment options. In these situations, a highly conformal technique with the most rapid dose falloff within adjacent normal tissue is necessary to minimize side effects. SRS, and SBRT techniques can safely provide good salvage or palliative results.

For example, for gastrointestinal/liver tumors, side effects related to radiation therapy can include adjacent soft tissue and bony necrosis (including abdominal wall, surrounding liver, and kidney), skin reaction, fatigue, nausea/vomiting, bowel adhesions, and secondary malignancies. However, when the appropriate constraints are used in terms of total adjacent tissue dose, the incidence of high grade toxicity in SBRT is relatively low due to the much higher degree of

conformality and steeper dose falloff in tissue outside the target. Multi-institutional trial data show that only 2% of patients treated for liver metastases had greater than grade 2 toxicity and none had grade 4 or higher toxicity (Rusthoven, JCO 2009).

Given the short time period allowed for comment, it is not possible to organize a comprehensive site related characterization of potential toxicities related to SRS/SBRT. However, we remain available at any time to answer and site or technology specific questions.

Additional References:

1) Cengiz et al, IJROBP, 2010. Salvage reirradiation with stereotactic body radiotherapy for locally recurrent hand and neck tumors

2) Comet et al, IJROBP, 2012. Salvage stereotactic reirradiation with or without cetuximab for locally recurrent head and neck cancer.

3) Dworzecki et al, Noeplasma 2012. Stereotactic radiotherapy as sole or salvage therapy in non small cell lung cancer patients.

4) Heron et al, IJROBP, 2009. Stereotactic body radiotherapy for recurrent squamous cell carcinoma of the head and neck.

5) Kunos et al, Technol Cancer Res Treat, 2008. Cyberknife radiosurgery for squamous cell carcinoma of vulva after prior pelvic radiation therapy.

6) Thariat et al, Br J Radiol, 2010. Innovative image guided Cyberknife stereotactic radiotherapy for bladder cancer. (Includes previously irradiated bladder cancer patient data).

7) Barney et al, Am J Clin Oncol, 2011. Clinical outcomes and dosimetric considerations using SBRT for abdominopelvic tumors.

8) Peulen et al, Radiother Oncol 2011. Toxicity after reirradiation of pulmonary tumors with SBRT.

9) Scorsetti et al, Strahlenther Onkol, 2011. SBRT for adrenal metastases: a feasibility study of advanced techniques with modulated photons and protons.

10) Rwigema et al, 2011 The impact of tumor volume and radiotherapy dose on outcome in previously irradiated recurrent squamous cell carcinoma of the head and neck treated with SBRT.

KQ3: What is the evidence that SRS/SBRT has differential efficacy or safety issues in subpopulations? Including consideration of:

a. **Gender**
b. **Age**
c. **Site and type of cancer**
d. **Stage and grade of cancer**
e. **Setting, provider characteristics, equipment, quality assurance standards, and procedures.**

The above discussion applies to nearly all patient subpopulations as evidenced by the wide range of anatomical subsites, patient demographics, and tumor characteristics described in the studies listed above.

KQ4: What is the evidence of cost and cost-effectiveness of SRS/SBRT/IMRT compared to EBRT?

Our ability to uncover cost and cost-effectiveness comparisons between these modalities has been significantly affected by the time frame allotted for responding. Except for studies of medically inoperable, early-stage non-small cell lung cancer which were readily available, our response is limited to generalizing our own clinical experience. Further, when determining the true, total "cost" and "cost-effectiveness" of each of these treatment alternatives, one needs to quantify the less obvious, indirect costs and benefits of these alternative therapeutic options. For example, how does one quantify the quality of life improvement for patients cured of head and neck cancers with IMRT? What dollar value do we assign to the improved long-term dental health of the patient who is able to receive IMRT instead of EBRT? Or as a second example, what is the financial cost/benefit dollar value assigned to the longer life expectancy of the SRS/SBRT patient receiving a potentially curative treatment with potentially very low risk rather than not having a treatment option since EBRT is not able to be used as a treatment option? Our analysis does NOT address these less obvious, indirect cost/benefit factors so if anything, the benefits of the appropriate use of SRS, SBRT and IMRT are understated in our own clinical experience generalizations.

Sher, Wee and Punglia in "Cost-effectiveness analysis of stereotactic body radiotherapy and radiofrequency ablation for medically inoperable, early-stage non-small cell lung cancer". (Journal/Int J Radiat Oncol Biol Phys, 81, e767-74, 2011) in a comparison of 3-D EBRT, RFA and SBRT concluded that "SBRT was the most cost-effective treatment for medically inoperable NSCLS over a wide range of treatment and disease assumptions. On the basis of efficacy and cost, SBRT should be the primary treatment approach for this disease".

This is consistent with an earlier study by Lanni, Grills, Kestin and Robertson in "Stereotactic Radiotherapy Reduces Treatment Cost While Improving Overall Survival and Local Control Over Standard Fractionated Radiation Therapy for Medically Inoperable Non-Small-Cell Lung Cancer". (American Journal of Clinical Oncology, 34(5):494-498, October 2011) which concluded that "SBRT was found to be less expensive than standard fractionated EBRT, with the cost savings highly dependent on the number of SBRT fractions and EBRT technique (3-D conformal RT vs. IMRT). SBRT was also associated with superior local control and overall survival."

Most radiation oncologists in Washington State (this group included) do not own the linear accelerators that deliver therapeutic radiation. They are typically owned by the hospitals who charge separately for their use. For linear accelerator based IMRT and 3D treatments, we are paid according to the applicable professional services fee schedule. The actual physician time and work effort involved is vastly greater for IMRT than for 3D yet despite this we are most often paid less for IMRT (in part due to bundling of charges). When we as physicians recommend IMRT over 3D we do so knowing we will spend three to four times more effort on the case and get paid less. Clearly our incentive for doing so is to provide the very best care and treatment for our patients.

From: JASON K. ROCKHILL [jkrock@u.washington.edu]
Sent: Tuesday, March 06, 2012 4:20 PM
To: HCA ST Health Tech Assessment Prog
Cc: mail=jkrock@uw.edu
Subject: Comments on SRS and SBRT from UW Medicine
Attachments: UW Medicine Response SRS_SBRT Final.docx

Please see the attached comments on the use of SRS and SBRT. Thank you - Dr. Jason Rockhill

March 6, 2012

To: Washington State Health Care Authority, HTA Program

Please see attached comments below from the UW Medicine/Seattle Cancer Care Alliance Department of Radiation Oncology and UW Medicine Department of Neurological Surgery regarding the Health Technology Assessment for Stereotactic Radiosurgery / Stereotactic Body Radiotherapy.

Anthony Avellino MD MBA
Professor, Department of Neurological Surgery

Michael Brown MD
Assistant Professor of Radiation Oncology

Ralph Ermoian MD
Assistant Professor of Radiation Oncology

Christine Fang MD
Assistant Professor of Radiation Oncology

Manuel Ferreira MD PhD
Assistant Professor of Neurological Surgery

Eric Ford PhD
Associate Professor of Radiation Oncology

Lia Halasz MD
Assistant Professor of Radiation Oncology

Gabrielle Kane MB EdD FRCPC
Associate Professor of Radiation Oncology

Edward Kim MD
Assistant Professor of Radiation Oncology

Janice Kim MD
Assistant Professor of Radiation Oncology

Wui-Jin Koh MD
Professor of Radiation Oncology

George Laramore MD PhD
Professor and Chair, Department of Radiation Oncology

Jay Liao MD
Assistant Professor of Radiation Oncology

Shilpen Patel MD
Assistant Professor of Radiation Oncology

Mark Phillips PhD
Professor of Radiation Oncology

Jason Rockhill MD PhD
Associated Professor of Radiation Oncology

Robert Rostomily MD
Associate Professor, Department of Neurological Surgery

Ken Russell MD
Professor of Radiation Oncology

George Sandison PhD FCCPM
Professor, Clinical Director of Medical Physics

KQ1: What is the evidence of effectiveness for stereotactic radiation surgery (SRS) and stereotactic body radiation therapy compared to conventional external beam radiation therapy (EBRT) for the following patients:

a. Patients with central nervous system (CNS) tumors

There are well over 10,000 articles spanning more than 30 years of use detailing the effectiveness of stereotactic radiosurgery (1 treatment - SRS) and stereotactic radiotherapy (2-5 treatments – SBRT) for tumors of the central nervous system including the skull base region as well as tumors involving the head and neck region. The benefit of SRS and SBRT has been show for all of the following:

1. Brain metastases
2. Primary brain tumors both initial treatment and recurrent
3. Meningiomas
4. Vestibular Schwanomas/Acoustic Neuromas
5. Pituitary tumors
6. Craniopharyngiomas
7. Paragangliomas
8. Salivary Gland Tumors in conjugation with Fast Neutron Radiotherapy
9. Recurrent Head and Neck tumors
10. Arteriovenous Malformations

A majority of these disease processes are not common and there is limited Level 1 evidence from randomized controlled trials comparing SRS to EBRT. Treatment decisions are based mainly on historical reports from institutional series in addition to the limited level 1 evidence. This is true even if looking at the data for conventional EBRT. A recent meta-analysis published in the Journal of Neurooncology (Pannullo *et. al*. J Neurooncol (2011) 103:1-17) summarized the effectiveness of SRS for a number of disease sites. For vestibular schwanomas and meningiomas, SRS led to control rates of approximately 90%. This reported control rate for meningiomas is further supported by a large retrospective series from Europe following 4565 benign meningiomas treated with SRS (Santacroce *et al.* Journal of Neurosurgery Vol 70:1 Jan 2012). For recurrent high grade primary brain tumors, patients who received SRS had improved survival of 9.5–26 months beyond expected. This is a particularly challenging group given that limited salvage options exist after initial treatment.

The treatment of brain metastases has become very controversial. Multiple randomized trials have failed to end the international debate on the optimal management of brain metastases, which can include supportive care, surgery, whole brain irradiation, SRS/SBRT or some combination of these treatments. At the center of the debate is preserving quality of life for patients who have a short life expectancy. Overtreatment with conventional radiation therapy carries the risk of long term neurocognitive toxicities in those patients who do better than average. Even in the short term, SRS/SBRT has the advantage of less acute toxicity, including fatigue and neurocognitive changes (Chang *et al. Lancet Oncol 2009; 10: 1037–44,)*. Reported control rates of SRS/SBRT for brain metastases have been approximately 80-90%. In addition, SRS/SBRT has been reported to improve local control of tumors that have been traditionally considered “radiation resistant,” such as melanoma, renal cell, and sarcomas,

when compared to standard whole brain irradiation. SRS also offers the benefit of minimizing interruption of chemotherapy, whereas whole brain radiotherapy typically requires patients to discontinue chemotherapy for 3-4 weeks while receiving treatment to avoid synergistic toxicities.

b. Patients with non-central nervous system cancers?

Stereotactic body radiation therapy (SBRT) has been shown to be very effective therapy for prostate, lung, spine, and liver as described below:

Prostate:

For prostate, Kang et al (*Tumori 97: 43-48, 2011*) show biochemical local control at 5 years of 100% for low and intermediate risk disease and 90.8% for high risk disease with Cyberknife (a specific device for SBRT). King et al (*Int J Radiat Oncol Biol Phys 82: 877-882, 2012*) show a 4 year biochemical local control rate of 94% for 67 low risk prostate cancer patients treated at Stanford with Cyberknife.

Lung tumors:

SBRT has improved survival and local control in patients with inoperable early-stage lung cancer, as noted in a study published in the March 17, 2010 issue of the Journal of the American Medical Association. (*Timmerman, et al. JAMA 2010, 303 (11), 1070-6*.) The phase 2 single-group study, which had 55 evaluable patients, demonstrated a 3-year disease-free survival of 48.3% and an overall survival of 55.8%. These findings represent a remarkable improvement over treatment with standard fractionated radiotherapy (EBRT) for patients with early-stage medically inoperable lung cancer. Previous studies reporting results from similar patient groups showed 2- to 3-year survival rates in the range of 25% to 35%. (*Armstrong JG, et al. Cancer Treat Rev. 1989;16(4):247–255; Kaskowitz L, et al. Int J Radiat Oncol Biol Phys. 1993;27(3):517–523*) In lung tumors, there is convincing evidence from United States, Japan and Europe that SBRT may be as effective as surgery for early stage lung cancer.(*Nagata Y, et al. Int J Radiat Oncol Biol Phys. 2005;63(5):1427–1431.; Fakiris AJ, et al. Int J Radiat Oncol Biol Phys. 2009;75(3):677–682*) It is certainly the treatment modality of choice for patients who cannot undergo surgery to remove their tumors from either a medical or technical perspective.

Liver tumors:

Radiation has historically had a minor role in the management of primary or metastatic liver tumors due to the poor tolerance of the entire liver to radiotherapy. Recent advances in treatment planning techniques have allowed delivery of highly focused doses of radiotherapy to portions of the liver while leaving remaining normal liver intact. These stereotactic radiosurgical and stereotactic radiotherapy techniques have allowed successful treatment of primary and metastatic liver tumors either as an alternative to surgery or for patients with medically inoperable disease.

In 2001, the University of Wurzburg published a promising early series of 23 patients who received SBRT for liver tumors with a 2 yr local control rate of 61%. (*Wulf J, et al, Strahlenther Onkol 2001, 177:645-655*) Several years later, the University of Colorado published a phase I/II trial of SBRT for liver metastases treating patients to a higher radiotherapeutic dose with a 93% local control rate at 18 months. (*Kavanaugh et al. Acta oncologica 2006, 45, 848-55*) A multi-institutional phase I/II trial of SBRT for liver tumors showed a 2 year local control rate of 92% and median overall survival of 20.5 months.(*Rusthoven, et al. J Clin Oncol 2009, April 1, (11), 1572-8*) Andolino et al (*Int J Radiat Oncol Biol Phys 81: e447-3453, 2011*) reported on 60 patients with hepatocellular carcinomas treated at Indiana University and concluded that SBRT was a safe and effective option for tumors < 6 cm in greatest

diameter. A Taiwanese group performed a matched-pair analysis of SBRT vs other/no treatments for 36 patients with recurrent hepatocellular cancer. Patients treated with SBRT had a 2 year survival of 72.6% vs 42.3% for other patients (p = 0.013). Toxicities were minimal.*(Huang et al. Int J Radiat Oncol Biol Phys 2012, PMID 22342300)*

By way of comparison to results with EBRT, the University of Michigan has performed dose escalation studies of 3D conformal external beam radiotherapy for patients with liver tumors with concurrent chemotherapy and reported a median survival of 15.2 months with a 30% incidence of grade 3-4 toxicity and 4% incidence of radiation induced liver disease. (*Dawson et al. Cancer Radiotherapie 2008, Mar;12:96-101*)

Aggressive treatment of liver metastases is of particular importance in patients with colorectal cancer, as ~20% of patients with liver-only metastases may achieve long term survival (> 10 years) or cure with successful control of their liver disease. (*Tomlinson JS, et al. J Clin Oncol 2007, 25, 4575-80)* In this group of patients, control of liver disease does not just palliate metastases, but can lead to cure. A pooled analysis of patients with colorectal liver metastases treated with SBRT at 3 different institutions showed sustained local control of disease was strongly correlated with overall survival. (*Chang et al. Cancer 2011, Sep 117, 4060-9*)

Spinal radiosurgery:
There is also evidence supporting the use of SBRT for the treatment of spine metastases. This is a similar situation to SRS/SBRT for brain metastases in that these patients likely have a short survival. Local control based on imaging and/or pain control indicates high rates of local control around 80% (Sahgal *et al*. J Neurosurg Spine 14:151-166, 2011.) This is particularly important given one usual indication for treatment is for palliation of pain. Conventional treatment over 10 fractions can be very challenging to patients due to the pain issue. SBRT can be administered as primary treatment or as salvage after failure of prior radiotherapy. In this clinical setting, the primary purpose of treatment is palliation of symptoms for the longest duration of benefit, prevention/reduction of morbidity from tumor progression into the spinal canal, and reduction of treatment-related toxicity. Mayo Clinic published a series of 85 patients with a 1 year local control rate of 83% for patients who were treated for salvage and 91% for patients treated with radiosurgery alone. (*Ahmed et al. Int J Radiat Oncol Biol Phys 2012 -epub ahead of print- PMID 22330988*)

Other disease sites:
Because of its non-invasive but ablative approach, SBRT has been investigated as a means of treating patient populations for which surgical metastatectomy has previously demonstrated benefit (i.e. colorectal cancer, sarcoma). A Korean group has published 3 year local control and overall survival rates of 64% and 60% for patients treated with SBRT to oligometastases from colorectal cancer in lymph nodes, liver, and lung. *(Bae et al. J Surg Oncol 2012, PMID 22297789)* The University of Colorado has also published a series showing 2 yr local control rates of 96% and medial survival of 19 months for patients with lung metastases treated with SBRT. (*Rusthoven et al. J Clin Oncol 2009, 27, 1579-84*)

Radiation-resistant tumors:
Certain tumors, such as melanoma and renal cell cancer, are resistant to radiation damage with conventionally fractionated doses of radiotherapy. The ablative doses used in SBRT are able to overcome this radiation resistance. In these clinical scenarios, SBRT's benefit is less likely to be

measured in improvements in overall survival, but in palliation of symptoms, and prevention of morbidity from local progression of disease at a symptomatic site. The University of Colorado has published a series of patients with melanoma or renal cell carcinoma with local control of 88% at 18 months with tumor control probability modeling predicting > 90% local control with doses equivalent to 48 Gy or higher. *(Stinauer et al. Radiat Oncol 2011, Apr,6, 34*). This exceeds

KQ2: What are the potential harms of SRS and SBRT compared to conventional external beam radiation therapy (EBRT)? What is the incidence of these harms? Include consideration of progression of treatment in unnecessary or inappropriate ways.

SRS/SBRT is well tolerated due to the treatment of smaller fields. The acute and long-term toxicity of SRS/SBRT for brain metastases is generally dependent on the size of lesions treated. In the series by Elliott *et al.,* the risk of permanent neurological deficit was less than 3.3% for lesions less than 2 cm in eloquent areas to 0% in lesions in non-eloquent areas (J Neurosurg 113:53–64, 2010). In the meta-analysis by Pannullo *et al.* the rate of complications following SRS was less than 7% for vestibular schwanomas and meningiomas. This rate is higher than most modern series due to inclusion of older series when higher doses were used for benign diseases. In the prostate study above, Grade 3 or greater bladder toxicities were only 3%, there were no grade 3 or greater rectal toxicities. In the JAMA study mentioned above for lung patients, seven patients (12.7%) experienced grade 3 and 2 patients (3.6%) experienced grade 4 protocol-specified adverse events. These events included hypoxia, hypocalcemia, pneumonitis, and decreased pulmonary function tests. However, the study has also led to better guidelines regarding patients suitable for lung SBRT, including decreasing the dose for patients with more central tumors. In general, patients must be carefully selected by an experienced radiation oncologist.

KQ3: What is the evidence that SRS and SBRT have differential efficacy or safety issues in sub populations? Including consideration of:
a. Gender
b. Age
c. Site and type of cancer
d. Stage and grade of cancer
e. Setting, provider characteristics, equipment, quality assurance standards and procedures

There has been no evidence that SRS/SBRT use would have different efficacy or safety issues based on gender. There is a least a theoretical advantage that SRS/SBRT in younger patients might reduce the long-term complication of radiation due to the smaller volume of normal tissue that receives a therapeutic dose.

Many cancers occur adjacent to organs that are more radiation sensitive such as the optic nerves, optic chiasm, cranial nerves, and spinal cord. The challenge is to obtain the optimal therapeutic dose for a good chance of tumor control without exceeding normal tissue tolerance. Many times the tumor may be adjacent to an organ that tolerates radiation reasonable well, however higher doses or dose escalation would allow for better tumor control. For low grade tumors or early stage cancers the concern is that these patients are likely going to survive for a long time and have to deal with the long-

term effects of large field EBRT. SRS/SBRT with smaller fields and less dose to normal tissue reduces the risk of long-term complications if delivered appropriately. At the other end of the spectrum, patients with aggressive cancers or advanced stage have a poor prognosis where survival is limited and their time is best not taken up by protracted trips to the clinic for 4-8 weeks of EBRT.

The equipment used for SRS/SBRT is fairly equivalent but with subtle differences. An important component to optimal efficacy and improved safety is having a team with adequate experience, procedural acumen and quality assurance protocols in place (including medical physics support).

KQ4: What is the evidence of cost and cost-effectiveness of SRS and SBRT compared to EBRT?

When comparing the cost and cost-effectiveness of SRS/SBRT, the comparison is not only to external beam radiotherapy but also conventional surgery. From the patient's out-of-pocket expenses, the fact that the treatment is much shorter significantly reduces cost. In addition, with fewer side effects, patients are able to return to work faster. Chao et al. found that 84% of patients returned to work in a median of 4 days following SRS treatment for a variety of disease processes (Technol Cancer Res Treat. 2012 Apr;11(2):117-22).

Mehta and colleagues performed a cost analysis of radiosurgery versus resection for single brain metastases. Though they found that both resection and radiosurgery yielded superior survival and functional independence, compared to whole brain radiotherapy alone. Resection resulted in a 1.8-fold increase in cost when compared to radiosurgery. (Int J Radiat Oncol Biol Phys 1997; 39(2):445-54. Lal *et al*. found that SRS with observation had a higher average cost when compared to whole brain plus SRS. They also found that SRS with observation was associated also with higher average life years saved (0.6 for WBI + SRS versus 1.64 for SRS + observation) (American Journal of Clinical Oncology 35:1 Feb 2012). Part of the reason for the higher average cost in the SRS + observation arm was that those who did progress after SRS alone where generally salvaged with surgery thus contributing to the overall cost.

SRS/SBRT is generally less expensive than conventional surgery. The Mayo group found that for vestibular schwanomas the mean cost was $23,788 for the microsurgery group compared with $16,143 for the radiosurgical group (Banerjee et al., J. Neurosurg 108:1220-1224, 2008).

Direct comparisons between EBRT and SRS/SBRT are limited. Haley *et al*., found that patients who underwent SBRT for spine metastases had the higher total gross charge but that depending on the technique, EBRT could approach 71% of the SBRT charge (J Neurosurgery Spine 14:537-542, 2011). Furthermore patients treated using EBRT had more acute toxicities, and required further intervention at the initial treated level. Papatheofanis *et al.* found that the cost of SBRT for spine metastases with Cyberknife was $1933 less than EBRT for comparable effectiveness (Neurosurgery 64:2, Feb 2009 Supplement.) Lastly, Sher *et al*., found the SBRT was cost effective over a wide range of conditions when compared to EBRT or RFA for medically inoperable non-small cell lung cancer. (Int. J. Radiation Oncology Biol. Phys., Vol. 81, No. 5, pp. e767–e774, 2011).

Washington University published a cost-comparison analysis of surgical intervention vs SBRT for early stage lung tumors in high risk patients. In that analysis, SBRT was less costly than surgical intervention. (*Puri et al. J Thorac Cardiovasc Surg. 2012, 143(2), 428-36.; Crabtree TD, et al. J Thorac Cardiovasc Surg. 2010 Aug;140(2):377-86)*

William Beaumont Hospital published a cost comparison for SBRT and EBRT demonstrating lower expenses with SBRT for stage I non-small cell lung cancer patients. *(Lanni et al. Am J Clin Oncol 2011, 34(5): 494-8)*

From: Pamela Barrett
To: HCA ST Health Tech Assessment Prog
Cc: jimkiefert@aol.com; Jack7474Sr@aol.com; raf0444@comcast.net
Subject: Us TOO International, prostate cancer patient comments on SBRT coverage in WA state
Date: Tuesday, March 06, 2012 10:38:40 AM
Attachments: WA state health care authority Us TOO LOR Mar 2012.pdf
Importance: High

Dear Washington State Health Care Authority Health Technology Assessment Team,

In response to your recent request to concerned stakeholders to submit comments as part of your upcoming review of stereotactic radiosurgery and stereotactic body radiation therapy (SBRT), we prostate cancer survivors in the Us TOO International Prostate Cancer Education & Support Network encourage the Washington State Health Care Authority add prostate cancer as a diagnosis that is eligible for coverage under its SBRT policy.

Please find attached our letter of support from our President and CEO, Tom Kirk.

We are happy to answer any questions you may have.

Thank you for taking into consideration the lives of all the men and their families battling a prostate cancer diagnosis in Washington state.

All the best,
Pam

Pam Barrett, Director of Development
Us TOO International Prostate Cancer Education & Support Network
5003 Fairview Ave, Downers Grove, IL 60515-5286
630-795-1002 ph | 630-795-1602 fax | pam@ustoo.org
www.ustoo.org | facebook.com/UsTOOInternational
Us TOO makes list of Top 10 Health Charities -- read our reviews here

March 6, 2012

Someone to talk to... who understands!

Washington State Health Care Authority
Health Technology Assessment Team
626 8th Avenue SE
Olympia, WA 98501

Dear Health Technology Assessment Team,

Us TOO International is a 21-year old Chicagoland-based, 501c3 non-profit, grassroots prostate cancer education and support network made up of 325 support group/chapters worldwide. We are the largest global survivor and volunteer-based organization for prostate cancer, and we are a source of peer-to-peer support and free materials for men and their families to make informed choices on prostate cancer detection, treatment options and coping with ongoing survivorship. In addition to providing education and support programs, Us TOO is an active advocate for patients.

Medicare coverage issues have been brought to our attention by patients and their care givers over the years, and we are concerned with ongoing patient access issues. We believe that men who happen to live in Washington state and have Medicare medical coverage should not be denied access to SBRT (stereotactic body radiation therapy) treatment.

We feel that it is Medicare's obligation to provide coverage for all medical treatments that have shown to improve the lives of prostate cancer patients. SBRT, a more recent form of radiation therapy, has been used to treat prostate cancer since 2001. Data suggest that this treatment is as effective as conventional treatments such as HDR brachytherapy, alternate external beam radiation techniques, and surgery. Due to the unique nature of prostate cancer, we do not believe there is not a "one size fits all" treatment for this disease. We do not make any recommendations on which type of therapy is best for a patient. However, it is our opinion that patients should be afforded the opportunity to select a therapy that both he and his health care provider feel will provide the best possible outcomes. This requires that all clinically appropriate treatment options be eligible for coverage under the Medicare program.

In conclusion, we request that the Washington State Health Care Authority add prostate cancer as a diagnosis that is eligible for coverage under its SBRT policy. By providing coverage for this treatment, the state of Washington will provide hope to thousands of men and their families who suffer from this disease.

Thank you in advance for your thoughtful consideration of this matter.

Sincerely,

Thomas N. Kirk
President & CEO
tom@ustoo.org

Member since 2005
Standards of Excellence® Certification Program

Us TOO is a 501(c)3 non-profit organization founded in 1990 by prostate cancer survivors and their families.

Us TOO PROSTATE CANCER EDUCATION & SUPPORT

Us TOO International
Prostate Cancer Education
& Support Network

5003 Fairview Avenue
Downers Grove, IL
60515-5286
Phone: (630) 795-1002
Fax: (630) 795-1602
PCa Support HelpLine:
(800) 80-Us TOO
(800-808-7866)
Email: ustoo@ustoo.org
www.ustoo.org

BOARD OF DIRECTORS

EXECUTIVE COMMITTEE
Chairman of the Board
Fred Mills
Vice Chair
Kay Lawmaster, MSW, LCSW
Secretary
Ridge Taylor
Treasurer
David Houghtons, PhD
President and CEO
Thomas N. Kirk

DIRECTORS
James C. Hemmeck, DDS
Jerry Hardy
Jean Jellins
Howard Kaczmarek
David Lubaroff, PhD
Rick Lyke, APR
James L. Riede
Dieter C. Rumsey III
John D. Shoff, Jr.
Rev. Harold Teuscher

DIRECTORS EMERITUS
Founder
John DeBoer
Founder
Ed Kaps
Immediate Past Chairman
James Kichart, EdD

OUR MISSION
Be the leading prostate cancer organization helping men and their families make informed decisions about prostate cancer detection and treatment through support, education and advocacy

SEA BLUE
SUPPORT RESEARCH ADVOCACY

From: Sarah Svoboda
To: HCA ST Health Tech Assessment Prog
Cc: Andy Whitman
Subject: 2012 Washington HTA Review of SRS and SBRT: Varian Comments and Clinical Evidence
Date: Tuesday, March 06, 2012 3:01:55 PM
Attachments: SRS SBRT Review by Washington HTA- Varian Comments 6 March 2012.pdf
Enclosure 1- Varian Cover Letter and SRS SBRT Bibliography Jan 17 2011.pdf
Importance: High

Dear Mr. Morse,
Please find attached Varian Medical Systems' submittal of clinical evidence and answers to the Key Questions in regards to the Washington Health Tech Assessment's 2012 review of Stereotactic Radiosurgery and Stereotactic Body Radiation Therapy with related enclosure. Thank you and please let me know if you have any questions regarding these materials.

Sincerely,

Sarah Svoboda

Sarah Svoboda
Government Affairs Associate
Varian Medical Systems
525 9th St NW, Suite 450
Washington, DC 20004
Phone: (202) 629-3441
Mobile: (408) 314-4199
Fax: (202) 559-0904

VARIAN medical systems | A partner for life

Varian Medical Systems, Inc.
3100 Hansen Way
Palo Alto, CA 94304-1038

Telephone: 1.650.493.4000

www.varian.com

Delivered via E-mail

January 14, 2011

Denise Santoyo
Program Coordinator
Washington Health Technology Assessment
P.O. Box 42712
Olympia, WA 98504-2712
shtap@hca.wa.gov

Dear Ms. Santoyo:

Attached please find information compiled by Varian Medical Systems that may be useful in your evaluation of stereotactic radiosurgery for the 2011 Washington Health Technology Assessment Program.

The information is a bibliography of clinical and technical journal publications from the time period January 2000 through December 2010, where Varian LINACs were used for Radiosurgery (SRS) or Stereotactic Body Radiotherapy (SBRT) or Varian users developed enabling techniques that are applied in the clinical practice of SRS and SBRT.

The bibliography is organized such that the first portion is the relevant journal papers, grouped by anatomical organ system. The second section is a collection of journal papers that are broad assessments or reviews. The third section details technical aspects of the delivery of SRS and SBRT.

Please feel free to contact me if you have any questions regarding the materials submitted.

Sincerely yours,

Calvin J. Huntzinger
Senior Director, Varian Surgical Sciences

VARIAN medical systems | A partner for life

Varian Medical Systems, Inc
525 9th Street NW, Suite 450
Washington, DC 20004
Telephone: 202.629.3459
www.varian.com

March 6, 2012

Mr. Josiah Morse, MPH
Program Director
Health Technology Assessment Program
Washington State Health Care Authority
P.O. Box 42712
Olympia, WA 98504-2712
shtap@hca.wa.gov

Dear Mr. Morse:

Thank you for the opportunity to submit clinical evidence to answer the Key Questions for your upcoming review of Stereotactic Radiosurgery (SRS) and Stereotactic Body Radiation Therapy (SBRT). In addition to the data below, I have also included our previous comment letter that provides numerous studies on this topic that may be helpful. Please feel free to contact me with any questions at (202) 629 3441.

Sincerely yours,

Andrew M. Whitman
Vice President, Government Affairs

Enclosures (1)

KQ1: What is the evidence of effectiveness for stereotactic radiation surgery (SRS) and stereotactic body radiation therapy compared to conventional external beam radiation therapy (EBRT) for the following patients:

The research cited below is categorized by disease-site studies highlighting the benefits of SRS and/or SBRT. For example, the research shows that SRS and SBRT have improved accuracy and tumor control rates, and effective symptom alleviation. The research also demonstrates that there is a potential improvement in quality of life as well as the ability to treat medically inoperable tumors with this non-invasive treatment.

a. Patients with central nervous system (CNS) tumors

Evidence/Quotation	Reference
The delivered radiation dose does appear to make a difference. With image-guided treatment verification, errors can be minimized to within 2 mm. This level of accuracy has enabled the delivery of high-dose, single-fraction RT within close proximity to the spinal cord without toxicity. IMRT is ideally suited to creation of the concave dose distributions necessary for cord-sparing treatment plans. Image-guided verification provides a mechanism to minimize the uncertainties associated with traditional RT. The coupling of IMRT and image-guided techniques takes full advantage of the extremely conformal potential of IMRT to provide high-dose RT with low normal tissue exposure and a high degree of confidence. The experience reported for high-dose, single-fraction image-guided RT is proof of principle that improved treatment accuracy has resulted in improved outcomes, with minimal serious morbidity.	Yamada, Y., Bilsky, M.H., Lovelock, D.M., Venkatraman, E.S., Toner, S., Johnson, J., … Fuks, Z.,(2008), High-dose, single-fraction image-guided intensity-modulated radiotherapy for metastatic spinal lesions. International journal of radiation oncology biology physics, 71(2), 484-490. doi: 10.1016/j.ijrobp.2007.11.046
"Both conventional and stereotactic radiosurgery are important treatment methods for the management of solid tumors metastatic to the spine. Both methods are well tolerated and provide effective tumor control and symptom palliation." Led here by SBRT symposium summary which quotes the authors of this study saying "We are able to deliver these treatments safely, and significant complications are rare. The literature consistently shows local control rates of up to 85 percent for those patients, and they often experience near complete pain relief. The majority of patients feel a significant improvement in pain within about 10 days of radiosurgery."	Gerszten PC, Mendel E, Yamada Y. Radiotherapy and radiosurgery for metastatic spine disease: what are the options, indications, and outcomes? Spine. 2009:34(suppl):S78-92.

b. Patients with non-central nervous system cancers

Evidence/Quotation	Reference

"The main finding in this prospective study was the high rate of primary tumor control (97.6% at 3 years). Primary tumor control is an essential requirement for the cure of lung cancer... Stereotactic body radiation therapy as delivered in [one study] provided more than double the rate of primary tumor control than reports describing conventional radiotherapy... Series reporting results from conventional radiotherapy for similar patient groups report 2-3 year OS in the 20-35% range, considerably lower than the 55.8% rate at 3 years in this report."	Timmerman R, et al. Stereotactic body radiation therapy for inoperable early stage lung cancer. JAMA. 2010;303:1070–1076
Indeed, for both T1 and T2 malignancies, SBRT was still the most cost-effective treatment modality over many assumptions. Furthermore, if SBRT is not available, RFA would be the most cost-effective therapy for small cancers, whereas 3D-CRT would be the preferred modality for larger lesions. The implications of this study could affect a significant number of patients, because an estimated 25% to 35% of early-stage lung cancer patients are not medically fit for lobar resection, and thus alternative therapies must be implemented 24... As we have shown, the superb control rates with SBRT overwhelm almost any increase in cost... If SBRT is available, conventional fractionated radiotherapy no longer appears to be a viable treatment approach for peripheral, early-stage lung cancers, based either on efficacy or on cost outcomes.	Sher, D.J., Wee, J.O., & Punglia, R.S. (2011). Cost-Effectiveness Analysis Of Stereotactic Body Radiotherapy And Radiofrequency Ablation For Medically Inoperable, Early-Stage Non–Small Cell Lung Cancer. International journal of radiation oncology, biology, physics, in press. doi: 10.1016/j.ijrobp.2010.10.074
Continuous hyperfractionated and accelerated radiotherapy "was found to yield better overall survival than conventional irradiation...with a 22% reduction in the relative risk of death..."	Chouaid, C., Atsou, K., Hejblum, G., & Vergnenegre, A.. (2009). Economics of Treatments for Non-Small Cell Lung Cancer. PharmacoEconomics, 27(2), 113-25. Retrieved September 6, 2011, from Alumni - ABI/INFORM Complete. (Document ID: 1692754451).
"The results of the present study have confirmed single-dose RT as a powerful clinical approach for achieving long-term local control of human tumors." "The experience reported for high-dose, single-fraction image-guided RT is proof of principle that improved treatment accuracy has resulted in improved outcomes, with minimal serious morbidity."	Yamada, Yoshiya, et al. (2008). High-Dose, Single-Fraction Image-Guided Intensity-Modulated Radiotherapy for Metastatic Spinal Lessons. International Journal of Radiation Oncology, Biology, and Physics, Vol 71:2, 484-490.
"The delivery of SBRT as described in this report offers excellent local control for medically inoperable patients with Stage I lung cancer, and results in an overall survival rate that is superior to outcomes reported for similar patients treated with conventionally fractionated RT." "Timmerman et al. reported a 95% local tumor control rate at 24 months in their Phase II study of SBRT in 70 medically inoperable lung cancer patients." "In conclusion, IMRT-based SBRT for medically inoperable Stage I [non-small cell lung cancer]...provides excellent local control and survival without undue toxicity."	Videtic G, et al. Intensity-modulated radiotherapy-based stereotactic body radiotherapy for medically inoperable early-stage lung cancer: excellent local control. Int J Radiat Oncol Biol Phys. 2010; 77:344–349.

KQ2: What are the potential harms of SRS and SBRT compared to conventional external beam radiation therapy (EBRT)? What is the incidence of these harms? Include consideration of progression of treatment in unnecessary or inappropriate ways.

The peer-reviewed studies listed below highlight that the use of SRS and SBRT can improve outcomes for patients. The research also shows that these types of treatment techniques are safe and effective.

Evidence/Quotation	Reference
The delivered radiation dose does appear to make a difference. With image-guided treatment verification, errors can be minimized to within 2 mm. This level of accuracy has enabled the delivery of high-dose, single-fraction RT within close proximity to the spinal cord without toxicity. IMRT is ideally suited to creation of the concave dose distributions necessary for cord-sparing treatment plans. Image-guided verification provides a mechanism to minimize the uncertainties associated with traditional RT. The coupling of IMRT and image-guided techniques takes full advantage of the extremely conformal potential of IMRT to provide high-dose RT with low normal tissue exposure and a high degree of confidence. The experience reported for high-dose, single-fraction image-guided RT is proof of principle that improved treatment accuracy has resulted in improved outcomes, with minimal serious morbidity.	Yamada, Y., Bilsky, M.H., Lovelock, D.M., Venkatraman, E.S., Toner, S., Johnson, J., … Fuks, Z.,(2008), High-dose, single-fraction image-guided intensity-modulated radiotherapy for metastatic spinal lesions. International journal of radiation oncology biology physics, 71(2), 484-490. doi: 10.1016/j.ijrobp.2007.11.046
Figures on page 1189-90 on symptom reduction post RT--decreased fatigue, pain, disturbed sleep, drowsiness, and distress, with less symptom interference affecting genera; activity, mood, normal work, relations, walking ability, and enjoyment of life.	Nguyen, QN, et al. Management of spinal metastases from renal cell carcinoma using stereotactic body radiotherapy. Int J Radiat Oncol Biol Phys. 2010;76:1185–1192
"Both conventional and stereotactic radiosurgery are important treatment methods for the management of solid tumors metastatic to the spine. Both methods are well tolerated and provide effective tumor control and symptom palliation." Led here by SBRT symposium summary which quotes the authors of this study saying "We are able to deliver these treatments safely, and significant complications are rare. The literature consistently shows local control rates of up to 85 percent for those patients, and they often experience near complete pain relief. The majority of patients feel a significant improvement in pain within about 10 days of radiosurgery."	Gerszten PC, Mendel E, Yamada Y. Radiotherapy and radiosurgery for metastatic spine disease: what are the options, indications, and outcomes? Spine. 2009:34(suppl):S78-92

KQ4: What is the evidence of cost and cost-effectiveness of SRS and SBRT compared to EBRT?

The studies listed below show that an investment in technology that can perform radiosurgery (SRS/SBRT) can be beneficial given the wide array of treatments that can be performed using a single medical device. In comparison to other treatment techniques for cancer, radiosurgery may be the most cost-effective.

Evidence/Quotation	Reference
Subsequent sensitivity analyses showed that SRS and observation was always cost effective compared with SRS and WBRT with ICERs in the range of $50,000 to $100,000/QALY. Therefore, from a resource allocation perspective, SRS and observation for brain metastases is a cost-effective treatment option within a WTP (willingness-to-pay) threshold of $100,000/QALY	Lal, L.S., Byfield, S.D., Chang, E.L., Franzini, L., Miller, L.A., Arbuckle, R., … Swint, J.M. (2011). Cost-effectiveness Analysis of a Randomized Study Comparing Radiosurgery With Radiosurgery and Whole Brain Radiation Therapy in Patients With 1 to 3 Brain Metastases. American journal of clinical oncology, 0, 0. doi: 10.1097/COC.0b013e3182005a8f
Indeed, for both T1 and T2 malignancies, SBRT was still the most cost-effective treatment modality over many assumptions. Furthermore, if SBRT is not available, RFA would be the most cost-effective therapy for small cancers, whereas 3D-CRT would be the preferred modality for larger lesions. The implications of this study could affect a significant number of patients, because an estimated 25% to 35% of early-stage lung cancer patients are not medically fit for lobar resection, and thus alternative therapies must be implemented 24... As we have shown, the superb control rates with SBRT overwhelm almost any increase in cost... If SBRT is available, conventional fractionated radiotherapy no longer appears to be a viable treatment approach for peripheral, early-stage lung cancers, based either on efficacy or on cost outcomes.	Sher, D.J., Wee, J.O., & Punglia, R.S. (2011). Cost-Effectiveness Analysis Of Stereotactic Body Radiotherapy And Radiofrequency Ablation For Medically Inoperable, Early-Stage Non–Small Cell Lung Cancer. International journal of radiation oncology, biology, physics, in press. doi: 10.1016/j.ijrobp.2010.10.074
The incremental cost-effectiveness ratio for SBRT over 3D-CRT was $6,000/quality-adjusted life-year, and the incremental cost-effectiveness ratio for SBRT over RFA was $14,100/quality-adjusted life-year. One-way sensitivity analysis showed that the results were robust across a range of tumor sizes, patient utility values, and costs. ...In comparison to 3D-CRT and RFA, SBRT was the most cost-effective treatment for medically inoperable NSCLC over a wide range of treatment and disease assumptions. On the basis of efficacy and cost, SBRT should be the primary treatment approach for this disease	Sher, D.J., Wee, J.O., & Punglia, R.S. (2011). Cost-Effectiveness Analysis Of Stereotactic Body Radiotherapy And Radiofrequency Ablation For Medically Inoperable, Early-Stage Non–Small Cell Lung Cancer. International journal of radiation oncology, biology, physics, in press. doi: 10.1016/j.ijrobp.2010.10.074

For inoperable stage I NSCLC, carbon-ion therapy costed euro 67.257 per quality-adjusted-life-year gained compared to SBRT. Both treatments dominated protons and CRT. Considerable uncertainty surrounded these results, resulting in a high EVPI. For operable stage I NSCLC SBRT dominated carbon-ion therapy.	Grutters, J.P.C., Pijls-Johannesma, M., De Ruysscher, D., Peeters, A., Reimoser, S., Severens, J.L., … Joore, M.A. (2010). The cost-effectiveness of particle therapy in non-small cell lung cancer: Exploring decision uncertainty and areas for future research. Cancer Treatment Reviews, 36(6), 468-476. doi: 10.1016/j.ctrv.2010.02.018
The cost-effectiveness per unit of QALY was better for the GKRS treatment (US$10,381/QALY) than in the WBRT treatment (US$17,622/QALY), $p<0.05$. The cost-effectiveness per KPS score was also higher for the GKRS treatment (US$139/KPS score) than for WBRT (US$229/KPS score), $p<0.01$. Thus, the mortality rate for multiple metastatic brain tumors treated by GKRS is significantly better with a good initial KPS score and when the tumor number is 2-5. GKRS results in a better post-treatment KPS score, QALY, and higher cost-effectiveness than WBRT for treating multiple metastatic brain tumors.	Lee, W.Y., Cho, D.Y., Lee, H.C., Chuang, H.C., Chen, C.C., Liu, J.L., … Ho, L.H. (2009). Outcomes and cost-effectiveness of gamma knife radiosurgery and whole brain radiotherapy for multiple metastatic brain tumors. Journal of Clinical Neuroscience,(5), 630-634. doi: 10.1016/j.jocn.2008.06.021

SWEDISH
CANCER INSTITUTE

1221 Madison Street, 1st Floor
Seattle, WA 98104
T 206.215.3536
F 206.215-3537

February 29, 2012

To whom it may concern,

As a member of the IRSA (International Radiosurgery Association) Board of Directors, my colleagues and I spent years developing consensus-based radiosurgery practice guidelines for the radiosurgical treatment of conditions as well as for numerous benign and malignant tumor diagnoses in the brain. These areas included the radiosurgical treatment of **Acoustic Neuromas**, **Trigeminal Neuralgia, Pituitary Adenomas**, **AVM (Aterio-Venous Malformations) and Brain Metastases**. Our aim was to improve outcomes for these diagnoses by assisting physicians in applying research evidence to clinical decisions while promoting the responsible use of health care resources. I have attached the link to these documents below. Guidelines from ISRA are pending for the following tumors and conditions **Meningiomas, Essential Tremor and Gliomas.** Nevertheless, the rational to treat them with SRS are included in this letter.

Acoustic Neuroma

http://www.irsa.org/AN%20Guideline.pdf

KQ1 and KQ2:

Gamma Knife Radiosurgery: Clinical Results

Tumor Growth Control

Long-term results of Gamma Knife® radiosurgery for vestibular schwannomas have been documented.[14,22,32,42,45,55] Recent reports suggest a tumor control rate of 93–100% after radiosurgery.[14,16,21-24,31,32,34,36,37,42-45,50-52,54,55,61,67,68] Kondziolka et al studied 5 to 10-year outcomes in 162 vestibular schwannoma patients who had radiosurgery at the University of Pittsburgh.[44] In this study a long-term 98% tumor control rate was reported. Sixty-two percent of tumors became smaller, 33% remained unchanged, and 6% became slightly larger. Some tumors initially enlarged 1–2 mm during the first 6 to 12 months after radiosurgery as they lost their central contrast enhancement. Such tumors generally regressed in volume compared to their pre-radiosurgery size. Only 2% of patients required tumor resection after radiosurgery. Norén, in his 28-year experience with vestibular schwannoma radiosurgery, reported a 95% long-term tumor control rate. Litvack et al reported a 98% tumor control rate at a mean follow-up of 31 months after radiosurgery using a 12 Gy margin dose.[53] Niranjan et al analyzed the outcome of intracanalicular tumor radiosurgery performed at the University of Pittsburgh.[65] All patients (100%) had imaging-documented tumor growth control. Flickinger et al performed an outcome analysis of acoustic neuroma patients treated between August 1992 and August 1997 at the University of Pittsburgh. The actuarial 5-year clinical tumor control rate (no requirement for surgical intervention) was 99.4 + 0.6%.[21,22] The long-term (10–15 year) outcome of benign tumor radiosurgery has been evaluated. In a study which included 157 patients with vestibular schwannomas**,** the median follow-up for the patients still living at the time of the study (n=136) was 10.2 years. Serial imaging studies after radiosurgery (n=157) showed a decrease in tumor size in 114 patients (73%), no change in 40 patients (25.5%), and an increase in three patients who later had resection (1.9%).[45] No patient developed a radiation associated malignant or benign tumor (defined as a histologically confirmed and distinct neoplasm arising in the initial radiation field after at least two years have passed).

Hearing Preservation

Pre-radiosurgery hearing can now be preserved in 60–70% of patients, with higher preservation rates found for smaller tumors. In a long-term (5–10 year follow-up) study conducted at the University of Pittsburgh, 51% of patients had no change in hearing ability.[21,44] All patients (100%) who were treated with a margin dose of 14 Gy or less maintained a serviceable level of hearing after intracanalicular tumor radiosurgery.[65] Among patients treated after 1992, the 5-year actuarial rates of hearing level preservation and speech preservation were 75.2% and 89.2%, respectively, for patients (n=89) treated with a 13 Gy tumor margin dose. The 5-year actuarial rates of hearing level preservation and speech preservation were 68.8% and 86.3%, respectively, for patients (n=103) treated with >14 Gy as the tumor margin dose.[22] Unlike microsurgery, immediate hearing loss is uncommon after radiosurgery. If hearing impairment is noted, it occurs gradually over 6 to 24 months. Early hearing loss after radiosurgery (within three months) is rare and may result from neural edema or demyelination. The exact mechanism of delayed hearing loss after radiosurgery is still unclear. Perhaps gradual obliteration of microvessels or even direct radiation axonal or cochlear injury is implicated. The effect of radiation on normal microvessels supplying the cochlear nerve or cochlea itself is not known. However, with doses as low as 12–13 Gy (which are sufficient to halt the tumor growth) vascular obliteration of normal vessels seems less likely. This dose probably does not adversely affect the vessels as well as the axons. Although with current imaging techniques the cochlear nerve cannot be well visualized, efforts should be made to achieve high conformality at anterior and inferior margin of the tumor. Conformal dose planning using 4 mm collimators for the intracanalicular portion of the tumor may prevent further injury to the cochlear nerve. It is likewise important to avoid radiation of the cochlea.[70]

Facial Nerve and Trigeminal Nerve Preservation

Facial and trigeminal nerve function can now be preserved in the majority of patients (>95%). In the early experience at University of Pittsburgh normal facial function was preserved in 79% of patients after five years and normal trigeminal nerve function was preserved in 73%. These facial and trigeminal nerve preservation rates reflected the higher tumor margin dose of 18–20 Gy used during the CT based planning era before 1991. In a recent study using MR based dose planning, a 13 Gy tumor margin dose was associated with 0% risk of new facial weakness and 3.1% risk of facial numbness (5-year actuarial rates). A margin dose of >14 Gy was associated with a 2.5% risk of new onset facial weakness and a 3.9% risk of facial numbness (5-year actuarial rates).[22] None of the patients who had radiosurgery for intracanalicular tumors developed new facial or trigeminal neuropathies.

Neurofibromatosis 2

Patients with vestibular schwannomas associated with neurofibromatosis 2 represent a special challenge because of the risk of complete deafness. Unlike the solitary sporadic tumors that tend to displace the cochlear nerve, tumors associated with NF2 tend to form nodular clusters that engulf or even infiltrate the cochlear nerve. Complete resection may not always be possible. Radiosurgery has been performed for patients with NF2. Subach et al studied 40 patients (with 45 tumors) who were treated with radiosurgery for NF2. Serviceable hearing was preserved in 6 of 14 patients (43%), and this rate improved to 67% after modifications made to the technique in 1992. The tumor control rate was 98%.[98] Only one patient showed imaging documented growth. Normal facial nerve function and trigeminal nerve function was preserved in 81% and 94% of patients, respectively. In two recent series,[78,80] serviceable hearing was preserved in only 30%[78] and 40%[80] of cases, respectively. The tumor control rate was respectively 71%[78] and 79%.[80] It now appears that preservation of serviceable hearing in patients with NF2 is an attainable goal with modern radiosurgery technique, and some centers propose this early treatment when the hearing level is still excellent."

KQ3:

"Clinical Algorithm

A number of patient related factors are considered in making a recommendation. These factors include:

• Age
• Symptoms
• Hearing status
• Current neurological status
• Medical condition
• Presence or absence of NF2
• Presence or absence of prior procedures
• Concern and risk tolerance for hearing, facial and trigeminal nerve function
• Patient desires
• Patient's decision after informed consent"

KQ4:

EBRT is not the standard of care for Acoustic Neuromas

Trigeminal Neuralgia

http://www.irsa.org/TN%20Guideline-UpdatedJan2009.pdf

KQ1 and KQ2:

"Several reports have documented the efficacy of Gamma Knife® stereotactic radiosurgery for TN.[1,3,16,18,20,26,27,29,32,35,39-42,46,50-53,58,62,68] Because radiosurgery is the least invasive procedure for TN, it is a good treatment option for patients with co-morbidities, high-risk medical illness, or pain refractory to prior surgical procedures. Radiosurgery is a good alternative for most patients with medically refractory trigeminal neuralgia, especially those who do not want to accept the greater risk of an MVD for a greater chance of pain relief.

To date, the largest reported series are still characterized by a wide spectrum of success rates after radiosurgery with Grade I outcome in 21–76.8% of patients and Grade II outcome in 65–88% of patients.[6,7,21,29,38,48,52,58,67] Regis et al reported that 87% of patients were initially free of pain in their series of 57 patients treated with a maximum dose of 75–90 Gy.[52,54] In many patients, they used the higher maximum dose of 90 Gy, and their target was placed at a more anterior site (closer to retrogasserian portion). In a series of 441 patients presented at the 2001 meeting of the International Stereotactic Radiosurgery Society, Young et al noted that 87% of patients were free of pain after radiosurgery, with or without medication (median follow-up period, 4.8 years, including repeat procedures). Brisman et al noted vascular contact with trigeminal nerve on thin section MRI in 59% of patients with TN. These authors reported a complete (100%) pain relief without medicines in 22% of patients, 90% or greater relief with or without small doses of medicines in 30% of patients, 75–89% relief in 11% of patients, 50–74% relief in 7% of patients, and less than 50% relief in 8% of patients. Recurrent pain requiring a second procedure occurred in 24% of patients.[7]

In a study, Petit et al. assessed the safety, efficacy and quality of life associated with radiosurgical treatment for TN in 112 patients treated with Gamma Knife® radiosurgery using a standard questionnaire. Ninety-six patients completed questionnaires for a median follow-up of 30 months. Seventy-four patients (77%) reported pain relief at a median of three weeks after the procedure.[44] A decrease in medication usage was noted in 66% of patients. Seven (7.3%) patients reported new or increased trigeminal dysfunction; however, only 3.1% reported these symptoms as bothersome. Patients with sustained pain relief reported an average of 100% improvement in their quality of life as a direct result of pain relief after radiosurgery, and 100% believed that the procedure was successful. Furthermore, among those patients with temporary pain relief and subsequent recurrence, 65% felt their treatment was a success with an average of 80% improvement in their quality of life.[44] Smith et al. recently published the results of trigeminal neuralgia radiosurgery using a dedicated linear accelerator.[59] These investigators treated 60

patients with central doses of 70–90 Gy delivered to trigeminal nerve root entry zone using a 5-mm collimator. Pain relief was experienced at a mean of 2.7 months. Significant pain relief was obtained in 87.5% of the patients who had essential TN and in 58.3% of the patients who had secondary facial pain. In a recent article, Longhi et al. reported on the results of Gamma Knife® radiosurgery for treatment of medically and, in some instances, surgically refractory TN.[35] These authors found 57% Grade I and 33% Grade II pain control after Gamma Knife® radiosurgery. These favorable results are similar to those reported by Pollock et al.[49] and Kondziolka et al.[28] Recurrence of pain occurred in 18% of patients at a mean interval of 14.2 months after radiosurgery. The side effects of trigeminal paresthesia or hypoesthesia were observed in 9.5% of patients; no cases of anesthesia dolorosa were observed. A higher radiosurgical dose and no previous neurosurgical intervention for TN were positive predictors of a pain-free outcome. The growing body of recent literature suggests that low rates of complications of Gamma Knife® radiosurgery, coupled with high success rates and patient satisfaction, allow it to be increasingly used as primary intervention for trigeminal neuralgia for appropriate patients.[2,12,13,18,20,22,26,34]

KQ3:

"A number of factors are considered in making a recommendation. These factors include:

1. Patient's age
2. Patient's medical condition
3. Presence or absence of multiple sclerosis
4. Presence or absence of vascular contact and/or compression on thin section MRI
5. Presence or absence of prior procedures
6. The type of prior procedure and its response
7. Severity of pain and how long the patient can reasonably wait for pain relief
8. Patient's concern and risk tolerance for dysesthesias, recurrence or complications from surgery"

Pituitary Adenoma

http://www.irsa.org/Pituitary%20Guideline.pdf

KQ1 and KQ2:

Stereotactic Radiosurgery

The endocrine control aims of radiosurgery are no different from those of surgical resection; namely, normalization of any hypersecretory syndrome without new onset hypopituitarism. Unlike surgical resection, which eliminates the tumor on subsequent neuroimaging, the neoplastic goal of stereotactic radiosurgery is permanent tumor control. This means that a tumor, which has been enlarging, is made incapable of further tumor growth, and this control is confirmed through long-term neuroimaging follow-up. While permanent stabilization of tumor size is the desired goal, the majority of tumors will demonstrate varying degrees of tumor shrinkage over time. Thus the goal of pituitary adenoma radiosurgery is to permanently control tumor growth, maintain pituitary function, normalize hormonal secretion in the case of functional adenomas, and preserve neurological function, especially vision. The small risks of late radiation-induced tumorigenesis and of late cerebrovascular accidents from radiation damage to the internal carotid arteries also exist for patients treated with radiosurgery. Delayed complications are less than that of stereotactic radiotherapy.

Tumor Growth Control After Radiosurgery

Non-functioning pituitary adenomas are usually diagnosed late when patients complain of visual dysfunction. Trans-sphenoidal decompression is recommended as the first line of management for these patients. Radiosurgery is often indicated as an adjuvant management after partial resection or later recurrence of pituitary adenomas. However, radiosurgery can be performed as the primary management

of nonfunctioning adenomas in carefully selected patients, including those who are high risk for surgery or consciously choose not to undergo resective surgery. Tumor growth control rates of 90–100% have now been confirmed by multiple centers following pituitary radiosurgery (13, 20, 21, 24, 26, 41). The antiproliferative effect of radiosurgery has been reported in nearly all patients who underwent Gamma Knife® radiosurgery (24, 41). Relatively few patients (who usually had received lower margin doses) eventually required additional treatment (12, 46).

Functional Effect of Radiosurgery

Growth Hormone Secreting Adenomas (Acromegaly)

A biochemical remission is defined as GH level suppressed to below 1 µg/L on OGTT and normal age-related serum IGF-1 levels. OGTT remains the gold standard for defining a cure of acromegaly. IGF-1, however, is far more practical. Decrease of random GH to less than 2.5 µg/L is achieved more frequently than the normalization of IGF-1 but it is necessary to obtain the fulfillment of both criteria. Microsurgery results in biochemical remission in 31–80% of patients (1, 5, 19, 53, 59). The suppression of hormonal hyperactivity is more effective when higher doses of radiation are used. Hormonal normalization after radiosurgery was achieved in 29–82% of cases in the published series (3, 4, 11–14, 17, 19, 20, 22, 24, 25, 30, 32, 33, 35, 36, 41, 42, 45, 47–49, 57, 62, 68). Because hormone suppressive medication during radiosurgery may act as a radioprotective agent, this medication should be discontinued at least six to eight weeks prior to radiosurgery (25, 49) and may be resumed after a week. In a study at the University of Pittsburgh, 38% of patients were cured (GH <1 µg/L) and overall, 66% had growth hormone levels <5 µg/L, 3–5 years after radiosurgery (44). An important goal of resective surgery is to achieve an immediate postoperative effect, while the results of radiosurgery have a latency of about 20–28 months (18, 28) that must be sometimes temporized through the temporary use of hormone suppressive medications.

ACTH Secreting Adenomas

Cushing's disease: The results to date achieved by radiosurgery (usually used after failed resective surgery) are slightly inferior to those reported after primary surgical resection in regard to secretory normalization. In addition there is a latency of approximately 14–18 months for maximal therapeutic response (18, 28). Patients with Cushing's disease respond to radiosurgery but more than one procedure may be needed. In various published series 63–98% hormone normalization after radiosurgery has been observed (10, 16, 29, 33, 36, 38, 40, 43, 46, 50, 51, 54, 55, 58, 63). *Nelson's syndrome:* Maintenance of elevated ACTH levels indicates continued biochemical activity of a pituitary adenoma after prior adrenalectomy for Cushing's disease. Strict hormonal normalization is not as important for the treatment of pituitary adenomas associated with Nelson's syndrome as it is for other secretory pituitary adenomas. The most important task of radiosurgery in the case of Nelson's syndrome is to control the growth of the tumor, which has been achieved in the majority of cases (66).

Prolactin Secreting Adenomas

Most prolactinomas can be controlled successfully by medical treatment. Surgery is indicated for cases of intolerance to medical treatment, in cases where women desire to have children, or when patients are dopamine agonist resistant (5–10% of patients). Some patients prefer microsurgery or radiosurgery to the need for life long medical treatment. In published studies of patients treated with radiosurgery, 25–29% showed normalization (26, 49). The possible radioprotective effect of dopaminergic drugs should be taken into account. In one of the studies patients treated with dopamine agonist had lower remission rates. It is therefore recommended that radiosurgery for prolactinoma be performed during a period of drug withdrawal (26).

Radiation Tolerance of Functioning Pituitary Tissue

The most important factor influencing post-irradiation hypopituitarism seems to be the mean dose to the hypophysis (pituitary stalk). Vladyka et al. observed some worsening of gonadotropic, corticotropic or thyrotropic functions 12–87 months after radiosurgery and usually 4–5 years after radiosurgery (61). There was no post radiation worsening of gonadotropic and thyrotropic functions when the mean dose to

the hypophysis did not exceed 15 Gy. The limiting mean dose to the hypophysis for adrenocorticotropic function was 18 Gy (61). In another study, deterioration in pituitary functions was observed when the pituitary stalk received higher doses (10). The risk for hypopituitarism after stereotactic radiosurgery thus becomes a primary function of the anatomy of the tumor and the dose prescribed. For recurrent tumors primarily involving the cavernous sinus, where the pituitary stalk (and even at times the residual pituitary gland) is separate from the tumor, easily visualized, and can be excluded from the treatment volume, the risk of hypopituitarism is extremely small, even when high doses are utilized for secretory adenomas. For adenomas that cannot be visually separated from the normal gland, particularly if they extend upward to involve or compress the pituitary stalk, the risk is predominantly related to the dose necessary to effectively achieve all treatment goals for the functional status of the tumor (higher for secretory than non-secretory adenomas).

Complications of Pituitary Radiosurgery

Complications of pituitary radiosurgery fall into three categories: hypopituitarism, visual deterioration and hypothalamic damage. The following rates of hypopituitarism have been reported: Levy et al. (32), 33%; Thoren et al. (57), 24%; Rocher et al. (52), 33%; and Lunsford et al. (34), 0%. As discussed in the section above, hypopituitarism risks vary with tumor anatomy relative to the pituitary stalk and gland, and vary with whether the adenoma is secretory or non-secretory (higher dose needed in the former). Stereotactic radiosurgery for residual or recurrent non-secretory adenomas solely involving the cavernous sinus carries the lowest risk of subsequent hypopituitarism, while secretory tumors close to the median eminence or requiring targeting of the whole pituitary gland carry the highest risk. Future studies must stratify for these variables in order to better predict hypopituitarism risk after stereotactic radiosurgery in an individual patient. Levy et al. (32) reported <1% increase in visual deficit in their large series. Lunsford et al. (34) reported one patient with visual compromise. Using LINAC radiosurgery, Rocher et al. reported a 39% incidence of some visual compromise (6% of patients were blinded) (52). The key to avoiding this complication lies in proper patient selection (adequate space between the optic apparatus and the superior edge of the tumor for the radiosurgery technique you are employing), insisting on strictly conformal planning at the critical structure interface, and accurate dose delivery. Lunsford et al. reported one death due to hypothalamic injury in a patient who had multiple operations, prior pituitary apoplexy and prior fractionated radiation therapy (34). Voges et al. reported one patient who developed a severe hypothalamic syndrome (62). Mitsumori et al., using LINAC radiosurgery for tumor invading the cavernous sinus, reported three cases of temporal lobe necrosis (39). As discussed above, there is a theoretical risk of late radiation induced tumorigenesis for patients receiving radiosurgical treatment. A small risk also exists of late cerebrovascular accidents from the effect of the ionizing radiation on the cerebral circulation passing adjacent to the pituitary gland. Fortunately, while the risk of major morbidity or mortality is not zero with radiosurgery, these occurrences appear to be extremely rare.

KQ3:

Clinical Algorithms

“The final recommendation is usually influenced by the cumulative experience of the medical management team. Combinations of different treatments may be necessary and/or desired under certain circumstances. Common examples include patients with cavernous sinus involvement present at diagnosis who undergo first stage microsurgery for the extra-cavernous portion of their tumor followed by second stage radiosurgery for the cavernous sinus component, and patients with secretory adenomas who undergo radiosurgery but are then maintained on their anti-secretory medications during the latency period for hormonal normalization after radiosurgery. The common need for staged or tandem treatments with multiple modalities underscores the importance of the presence of a comprehensive and coordinated multidisciplinary team in the optimal management of pituitary adenoma patients.”

KQ4:

“Fractionated Radiation Therapy (EBRT)

Fractionated radiation therapy has been used for the treatment of unresectable pituitary adenomas. Rates of tumor control have been reported to vary from 76% to 97%. Fractionated radiation therapy, however, has been less successful (38–70%) in reducing hypersecretion of hormones by hormonally active tumors. It may take years before the full therapeutic effect is exhibited. The delayed complications of fractionated radiation therapy (2–10 years) include a relatively high risk of hypopituitarism (12–100%) and a low but definite risk of optic neuropathy (1–2%) and secondary tumor formation. Some investigators have reported a higher likelihood of cerebrovascular disease in patients treated with radiation therapy for pituitary tumors. In patients with a benign 3 neoplasm and an otherwise normal expected life span, external beam fractionated radiotherapy (EBRT) leads to exposure of normal surrounding brain to potential long term cognitive effects of radiotherapy. Newer fractioned radiotherapy techniques such as intensity modulated radiotherapy (IMRT) can minimize the amount of normal brain exposed to radiation compared with conventional or standard 3-D conformal techniques. However, the medial temporal lobes on either side, which are intimately involved in memory processing and learning, often remain exposed as the radiation distribution is shifted away from the optic nerves and chiasm. Minimal long-term outcome data exist for IMRT."

Intra-cranial Ateriovenous Malformations:

http://www.irsa.org/AVM%20Guideline.pdf

KQ1, KQ2 and KQ3:

"Stereotactic radiosurgery is considered for patients with unresectable AVMs. Such patients may warrant treatment based on age, location, volume or medical history.[77] Radiation technologies for stereotactic radiosurgery include Gamma Knife® radiosurgery, proton beam radiosurgery, and linear accelerators (LINACs) modified at Centers of Excellence with extensive AVM experience. Multi-modal management teams are essential for proper patient selection and patient care. Because of the delayed obliteration rate of AVMs after radiosurgery, comprehensive long-term management and observational strategies are necessary.

Probability of AVM Obliteration with Radiosurgery

Current studies indicate a success rate between 50–95% at the end of three years of observation after a single radiosurgery procedure.[1,4,5,7–10,17,21,22,33–35,38–43,47,48,51,52,56,57,61–63,66,71,74,76–79,82,84] The long-term (5–14 years) results of Gamma Knife® radiosurgery suggest that the majority of AVM patients (73%) are protected from the risk of future hemorrhage and continue their normal daily activities after radiosurgery.[63]

In a study of rate of AVM obliteration after Gamma Knife® radiosurgery at the University of Pittsburgh, obliteration was documented by angiography in 73% and by MR alone in 86% of patients who refused further angiography.[17] Assuming a 96% accuracy for MR-detected obliteration, the corrected obliteration rate for all patients was 75%.[65] Persistent out-of-field nidus (marginal failure) was identified in 18% of previously embolized versus 5% of non-embolized patients ($p = 0.006$). This was the only significant factor associated with marginal failure. Multivariate analysis correlated in-field obliteration with marginal dose ($p < 0.0001$) and sex (slightly lower in women [$p \leq 0.026$], but overall obliteration was not significantly lower [$p = 0.19$]).

Early Adverse Effects of Radiosurgery

Adverse effects of radiosurgery include short-term problems such as headache from the frame, nausea from pain medication, and perhaps a small increased risk of seizure in patients with cortical lobar AVMs, particularly if a prior history of episodic seizures is present.[14,16,18,65] For this reason we use perioperative anticonvulsants in lobar AVMs.

Late Complications After AVM Radiosurgery

Delayed complications of radiosurgery on AVMs include hemorrhage despite angiographically documented complete obliteration of the AVM, temporary or permanent radiation injury to the brain such

as persistent edema, radiation necrosis, radiation-induced tumors and cyst formation. Cyst formation after AVM radiosurgery was first reported by Japanese investigators who reviewed the outcomes of patients initially treated in Sweden.[24] Jokura et al. 6

KQ3:

A number of factors are considered in making a recommendation. These factors include:

1. Patient's age
2. Patient's medical condition
3. Previous bleed
4. Prior procedures
5. Volume of AVM
6. Location of AVM
7. Presenting symptoms

KQ4:

The standard of care does not include EBRT in the treatment of AVM's.

Brain Metastases

http://www.irsa.org/Metastatic%20Guideline.pdf

KQ1 and KQ2:

"Radiosurgery as the sole initial management or as a boost before or after WBRT has emerged as a widely practiced treatment modality for brain metastases. The goal of radiosurgery without WBRT is to achieve brain control without the possible long term neurotoxic or cognitive side effects of WBRT.[17] The rationale for radiosurgery, when used as a boost after WBRT, is to achieve improved local brain tumor control. Radiosurgery boost improves survival in selected patients in whom the predominant problem is brain disease rather than extracranial disease. Radiosurgery is also used as salvage treatment for progressive intracranial disease after surgery or WBRT. Traditionally radioinsensitive histologies tend to be more responsive to SRS than to conventional fractionated radiation treatment. In addition, SRS causes indirect vascular injury and subsequent sclerosis of blood vessels, and eventual compromise of the blood supply and circulation within the tumor.[121] The overall side effects of SRS are limited but can occasionally be serious. There are very few acute side effects of SRS related to the radiation. Stereotactic radiosurgery may cause mild fatigue and sometimes a temporary patch of hair loss if the tumor is close to the skull and scalp. There is a risk of late side effects that can develop, the most common and serious of which is tumor radionecrosis.[134] Radiation necrosis is damage to the tumor and or adjacent brain in the high-dose area. This can result in edema and additional side effects produced by the mass including seizures and neurological deficits. Radionecrosis can often be managed with corticosteroids. Occasionally surgical intervention is required to reduce the mass effect. The risk of symptomatic radionecrosis is usually less than 5%.[2,5,56] A multicenter phase I RTOG trial involving SRS documented safe SRS in patients previously treated with standard external beam radiation therapy.[111] Early publications showed good control rates and led to further investigation.[24,64,76,120] Retrospective series have consistently revealed local control of the target lesions in the range of 80–85% or even higher with a very acceptable side effect profile.[5,10,20,30,37,51,70] Prospective randomized trials have demonstrated that the one-year local control rate of target lesions with radiosurgery is 73%, which increases to 82–89% with the addition of WBRT.[2,4]

Retrospective Studies for SRS

Patients treated with conventional open surgical resection without WBRT had a 46% risk of failure at the site of the resection in a randomized trial evaluating the role of WBRT after surgical resection.[89] In subsequent studies patients were treated with SRS alone (without WBRT). These studies 8 found excellent local control (70–80% at one year).[21,83] Other published series of patients treated with SRS have demonstrated a risk of distant brain failure at one year, ranging from 43% to 57%.[22,49,66,117] In general, the risk of new metastasis in patients with solitary tumors is approximately 37% (crude), but the actuarial risk is 50% at one year.[62,89] The histologic features or tumor type may play a role, with melanoma being more likely to be associated with multiple metastases than some other tumor types.[95] Despite a relatively high risk of new metastases outside the radiosurgery volume in patients who have SRS alone, retrospective studies have not confirmed a survival benefit to adjuvant WBRT.[94,117,118] Freedom from local progression in the brain at one year was significantly superior in patients who received both SRS and WBRT compared with SRS alone (28% vs. 69%), although the overall survival rate was not significantly different.[49] A retrospective, multi-institutional study in which patients were treated with SRS alone (n = 268) or SRS + WBRT (n = 301) also reported no significant difference in the overall survival rate.[161] Despite the higher rate of new lesions developing in patients treated with SRS alone, the overall survival appears to be equivalent to SRS + WBRT since salvage therapies are fairly effective and patients' extracranial disease is frequently the cause of death.[117] Only 24% of patients managed initially with radiosurgery alone required salvage WBRT. Pirzkall et al. reported that there was no survival benefit for an overall group of 236 patients with adjuvant WBRT but these authors noted a trend toward improved survival in a subset of patients with no extracranial tumor (15.4 vs. 8.3 months, p = 0.08).[94] Chidel et al. reported on 78 patients managed initially with SRS alone and 57 patients treated with SRS and adjuvant WBRT.[157] Whole-brain radiation therapy did not improve the overall survival rate but was useful in preventing both the local progression and the development of new brain metastases (74% vs. 48%, p = 0.06). These retrospective studies suggest that WBRT will improve local and distant control in the brain, but do not clearly demonstrate a survival advantage.[117]

A multicenter retrospective analysis was performed with 502 patients treated at 10 institutions in which all of the patients were treated with WBRT and SRS. The patients were stratified by the recursive partitioning analysis and compared with similar patients from the RTOG database who had been treated with WBRT alone.[104] The study revealed that patients with higher KPS, controlled primary tumor, absence of extracranial metastases and lower RPA class had statistically superior survival. The addition of an SRS boost resulted in a median survival of 16.1, 10.3 and 8.7 months, respectively, for RPA classes I, II and III. This is in comparison to 7.1, 4.2 and 2.3 months for similar RPA class patients from the RTOG database. This improvement in overall survival, stratified by RPA class with an SRS boost, was statistically significant.[104] In a recent study SRS alone was found to be as effective as resection plus WBRT in the treatment of one or two brain metastases for patients in RPA classes I and II.[98]

Local Tumor Control

In a randomized trial reported in abstract form by Chougule et al.,[23] patients were randomized to Gamma Knife® radiosurgery alone vs. WBRT and Gamma Knife® radiosurgery vs. WBRT alone. The local brain control rate was higher in the two radiosurgery arms: 87% for Gamma Knife® radiosurgery alone and 91% for Gamma Knife® radiosurgery and WBRT, compared with 62% in the WBRT only arm. Another randomized trial compared the use of radiosurgery with WBRT plus radiosurgery as initial therapy in selected patients with brain metastases.[4] Aoyama et al. reported the results of a prospective, multi-institutional, randomized controlled trial comparing WBRT plus SRS vs. SRS alone for patients with limited (defined as < 4) brain metastases with a maximum diameter of 3 cm on contrast-enhanced MRI scan.[4] Patients with metastases from small cell carcinoma, lymphoma, germinoma and multiple myeloma were excluded. Eligible patients had a KPS score of 70 or higher. The WBRT dosage schedule was 30 Gy in 10 fractions over 2–2.5 weeks. Metastases with a maximum diameter of up to 2 cm were treated with SRS doses of 22–25 Gy and those larger than 2 cm were treated with doses of 18–20 Gy. The dose was reduced by 30% when the treatment was combined with WBRT. Local tumor progression was defined as a radiographic increase of 25% or more in the size of a metastatic lesion. The primary end point of the study was overall survival. Secondary end points were cause of death, functional preservation, brain tumor recurrence, salvage treatment and toxic effects of radiation. One hundred thirty-two patients were randomized (65 to WBRT + SRS and 67 to SRS alone). The interim analysis was

performed with 122 patients (approximately 60 in each group). The Japanese Radiation Oncology Study Group 99-1 trial[4] reported an actuarial one-year local tumor control rate of 88.7% in the WBRT + SRS group and 72.5% in the SRS-alone group (p = 0.002). The one-year actuarial rate of developing new brain metastases was 41.5% in the WBRT + SRS group and 63.7% in the SRS-alone group (p = 0.003). A prospective, single arm, multi-institutional Eastern Cooperative Oncology Group (ECOG) Phase II study of radiosurgery alone for "radioresistant" histologies (melanoma, sarcoma, renal cell carcinoma) in patients with one to three brain metastases has also been reported.[69] Inclusion criteria were one to three newly diagnosed brain metastases with a maximum diameter of 4 cm. In patients with multiple lesions and any lesion > 3 cm, all remaining lesions were required to be < 3 cm. Of 36 patients accrued, 31 were eligible and evaluable; 14 had melanoma, 14 had renal cell carcinoma and three had sarcoma. Three of thirty-one patients (10%) had partial response, 10 of 31 (32%) had stable disease, 14 of 31 (42%) had progressive disease, and 4 of 31 (14%) were not evaluable. At six months, 39.2% failed within the radiosurgery volume and 39.4% failed outside the radiosurgery volume. Several retrospective studies[21,94,113,117,128] compared local brain control rates of those patients receiving initial radiosurgery alone with those receiving whole-brain radiation therapy. Chidel et al.[21] found a statistically significant improvement in two-year brain control with the use of WBRT in addition to radiosurgery boost: 80% vs. 52% in patients treated with radiosurgery alone (p = 0.034). Pirzkall et al.[94] found one-year local control rates to be inferior with the radiosurgery alone group: 89% vs. 92% in the WBRT and radiosurgery boost group. Shehata et al.[113] reported that patients who had whole-brain radiation therapy had superior local tumor control rates (97%) compared with patients treated with radiosurgery alone (87%; p = 0.0001). Sneed et al.[117] reported a statistically significant improvement in one-year brain freedom from progression rate in those patients treated with WBRT + SRS boost (69%) compared with those patients treated with initial radiosurgery only (28%). It was commented that the one-year brain control rate allowing for salvage (using WBRT or serial SRS) at first failure was not statistically different between those treated with initial WBRT + SRS boost (73%) vs. those treated initially with SRS alone (62%). Wang et al.[128] found that the local brain control rate of patients treated with SRS alone was 93.3%, compared with 95.6% in patients treated with WBRT + SRS boost.

Survival

The Japanese trial[4] found no significant survival difference between the groups receiving WBRT + SRS and SRS alone. The median survival time was 7.5 months with WBRT + SRS and 8.0 months with SRS alone. In addition, no significant difference in the frequency of death due to neurologic causes was observed. Death was attributed to neurologic causes in 22.8% in the WBRT + SRS group and in 19.3% in the SRS alone group. In Chougule et al.'s abstract,[23] median survivals were seven, five and nine months for Gamma Knife® radiosurgery alone vs. WBRT and Gamma Knife® radiosurgery vs. WBRT, respectively. Survival was reported as not different among the three arms. The ECOG 12 Phase II trial[69] of radiosurgery alone for radioresistant histologies found median survival to be 8.2 months (95% CI, 7.4–12.2 months) in its cohort of patients. Lutterbach performed a prospective study[66] using radiosurgery alone for the initial management of brain metastases. However, no survival comparisons were made with patients treated with WBRT. Several retrospective studies have reported on the use of radiosurgery alone as initial management of selected patients with brain metastases.[15,21,39,49,53,105,109,113,115,117,118,124,128] Survival outcomes ranged from 8–15 months. Chidel et al.[21] reported the median survival of patients treated with radiosurgery alone as 10.5 months compared with 6.4 months in patients treated with radiosurgery boost and whole-brain radiation therapy (p value not stated). Sneed et al.[117] reported that the median survival of patients treated initially with radiosurgery alone was 11.3 months, which was not statistically different from the survival of patients treated with WBRT + SRS boost (11.1 months). Wang et al.[128] reported a median survival of 15 months in patients treated with SRS alone vs. 20 months in patients treated with WBRT + SRS boost vs. 8.5 months for patients treated with WBRT alone. Pirzkall et al.[94] found no difference in overall survival for patients treated with radiosurgery alone or radiosurgery and WBRT; however, in the subset of patients without extracranial disease, omitting whole-brain radiation therapy resulted in a survival decrement from 15.4 to 8.3 months. Sneed et al.[118] collected data from 10 institutions to compare the survival probabilities of patients with newly diagnosed brain metastases managed initially with SRS alone vs. SRS and WBRT. Of the 569 evaluable patients, 268 had radiosurgery alone initially (24% of these ultimately needed salvage WBRT) and 301 had radiosurgery and up-front WBRT. The median

survival times for patients treated with SRS initially vs. SRS + WBRT were 14.0 vs. 15.2 months for RPA Class 1, 8.2 vs. 7.0 months for Class II, and 5.3 vs. 5.5 months for Class III. With adjustment by RPA class, there was no survival difference comparing radiosurgery alone initially with radiosurgery and up-front whole-brain radiation therapy. There is Level I evidence from the recently published Japanese trial[4] and Level II-3 evidence from literature that addition of up-front WBRT does not improve survival in patients treated with up-front radiosurgery. Thus patients with newly diagnosed brain metastases can be treated with up-front SRS alone, reserving WBRT for salvage."

Role of SRS for Multiple Brain Metastases
Stereotactic radiosurgery is an effective treatment for patients with multiple brain metastases. A substantial amount of published literature now supports use of radiosurgery in the treatment of multiple brain metastases. Stereotactic radiosurgery offers a very high control rate with a low risk of serious side effects. The RTOG 95-08 study authors concluded that addition of stereotactic radiosurgery to WBRT improved functional autonomy for all patients; therefore WBRT and stereotactic radiosurgery should be considered for patients with two or three brain metastases. For patients with good performance status up to three brain metastases, SRS with or without the addition to WBRT is reasonable."

Indications for Radiosurgery
• Newly diagnosed single or multiple brain metastases without significant mass effect documented on imaging
• Boost after WBRT for single or multiple brain metastases
• Recurrent brain metastases after WBRT
• Radiosurgery for residual tumor after resection

KQ3:

"Clinical Algorithm

Several factors are considered in making a recommendation. These factors include:

1. Patient's age
2. Patient's symptoms
3. Status of systemic disease
4. Patient's current neurological status
5. Patient's medical condition
6. Presence or absence of other organ metastases
7. History of prior WBRT
8. History of prior brain procedures
9. Patient's concern and risk tolerance for neuro-cognitive functions
10. Patient's wishes

Tumor Size
Radiosurgery can be performed for tumors up to 4 cm in maximum diameter. However, tumor volume, dose and location are more important variables.

Patient Preference
Patients' preferences are also considered in selecting a management approach. A broad outline of brain metastases diagnostic work-up and management algorithms for single tumor, limited brain disease (2–4 tumors) and multiple metastases are shown. However, the final recommendation is usually influenced by the recommending surgeon's, radiation oncologist's and neuro-oncologist's experiences along with patient preference.

Conclusion
There is Level I to Level II-3 evidence that addition of WBRT in patients treated with radiosurgery for 1–3 newly diagnosed brain metastases does not improve survival, compared with radiosurgery alone with WBRT reserved for salvage therapy. There is Level I evidence that omission of WBRT results in decreased tumor control, both at the site of radiosurgery and also in the remaining untreated brain. Level II-1 and Level II-3 evidence further support this observation"

Meningiomas: This information is from an on-line journal (Brain Talk, Volume 6, Number 2).
References are stated below each paragraph

KQ1 and KQ2:

MENINGIOMALONG-TERM OUTCOMES AFTER RADIOSURGERY...
In an effort to determine long-term outcomes of radiosurgery for meningioma, researchers at the University of Pittsburgh followed 99 patients for 5-10 years after radiosurgery Ninety-three percent of the tumors were controlled by radiosurgery. Sixty-three percent of the tumors became smaller, the size of 32% did not change and 5% were enlarged. Three to thirty-one months after radiosurgery, neurological deficits developed in 5% of patients. Fourteen percent of patients reported at least one complication which resolved in nearly half (44%) of these cases. Ninety-six percent of patients completing an outcomes questionnaire 5-10 years after radiosurgery believed it was successful. The authors concluded that long-term tumor control, preservation of neurological function and patient satisfaction were afforded by radiosurgery.
– from the Journal of Neurosurgery 1999;91(1):44-50.

RADIOSURGERYFOR MALIGNANT MENINGIOMA...
Twenty-two patients with malignant meningioma were treated with Gamma Knife® radiosurgery. The five-year survival estimate was 40% and the five-year progression-free survival estimate was 26%. Patient age and tumor volume were significant predictors of time to progression and survival. Twenty-three percent of patients developed radiation necrosis. Complications, treatment variables and patient characteristics were unrelated. Greater tumor control after Gamma Knife® radiosurgery was observed in younger patients and in those with smaller tumors. The authors concluded that malignant meningiomas may be treated with Gamma Knife® radiosurgery with acceptable toxicity, and recommended that the relative efficacies of recurrent malignant meningioma therapies be further evaluated.
– from the Journal of Neurosurgery 2000;93(Suppl.3):62-67.

CAVERNOUS SINUS MENINGIOMAS AND RADIOSURGERY...
The functional tolerance and tumor control rate of benign cavernous sinus meningiomas treated with Gamma Knife® radiosurgery was evaluated in 80 patients. After radiosurgery, the tumor stabilized in 51 patients, shrank in 25 patients and enlarged in four patients. The five-year progression-free survival was 92.8%. New oculomotor deficits were not observed. Fifty-four patients had existing oculomotor nerve deficits; of these, 15 improved, eight recovered, and one worsened. Thirteen patients had trigeminal neuralgia; of these, four improved, five were unchanged, three recovered and one worsened (coincident with tumor growth). The authors concluded that Gamma Knife® radiosurgery was an effective tool for the low-morbidity treatment of cavernous sinus meningioma. Oculomotor function was restored in a significant number of patients. The authors suggested that Gamma Knife® radiosurgery was an alternative to surgical removal of confined enclosed cavernous sinus meningiomas.
– from the Journal of Neurosurgery 2000;93(Suppl.3):68-73.

MENINGIOMAS, RADIOSURGERYAND EARLY COMPLICATIONS...
Complications arising within one year of Gamma Knife® radiosurgery for intracranial meningiomas were assessed in 77 patients. Gamma Knife® radiosurgery followed surgery in 49 patients and was the primary therapy in 28 patients. Fifty patients had basal meningiomas and 27 had non-basal meningiomas. The

most common sites were the cerebellopontine angle (14 patients) and parasagittal (23 patients). Five patients experienced seizures and four had increased headaches. Two patients with parasagittal tumors experienced a temporary worsening of hemiparesis. Perilesional edema was observed in nine patients and was symptomatic in six. Six (22%) of the 27 patients with non-basal tumors had edema (all parasagittal); four patients were symptomatic. Three (6%) of the 50 patients with basal meningiomas had edema, and only one patient was symptomatic. Occurrence of edema was not related to radiation received by adjacent brain or tumor volume, margin or maximum dose. Tumor size was reduced in seven patients. The authors concluded that although Gamma Knife® radiosurgery provides good results for selected patients with meningiomas, patients with parasagittal tumors should be treated with caution because of the high incidence of perilesional edema.
– from the Journal of Neurosurgery 2000;93(Suppl.3):57-61.

KQ3 and KQ4

Radiosurgery is considered a standard of care in the treatment of Meningiomas. SRS treats far less normal brain tissue than EBRT which is significant in reducing the long-term side effects in all age groups. These are generally benign tumors and the life expectancy of patients treated is usually not related to this condition. As a result, chronic toxicity from EBRT can present as a life long struggle.

SRS thalamotomy for tremor (Essential and Parkinsons). This information is from an on-line journal (Another Perspective, Volume 4, Number 4) **which was submitted by one of our Neurosurgeons, Dr Ronald Young**

KQ1 and KQ2;

Both radiofrequency and radiosurgical thalamotomy can be expected to relieve tremor in about 85% of patients. In some patients, the tremor is markedly suppressed but not totally relieved and in other patients, the tremor is completely relieved. Examples of a patient's handwriting before and after a thalamotomy was performed with the Gamma Knife® are shown in figures one and two. Virtually all of the treatment of movement disorders using radiosurgery has been with the Gamma Knife®. There is little or no experience in using the other forms of radiosurgery, that is, the linear accelerator or heavy particle beam radiosurgery, to make such lesions for treatment of movement disorders. Therefore, results achieved with Gamma Knife® may not be indicative of results achieved with other types of radiosurgical equipment. The Gamma Knife® is designed to perform this type of treatment. We have performed more than 200 thalamotomies for the relief of tremor over a period of more than eight years. Only two relatively mild side effects have been seen in these 200 patients. Both involve mild weakness or coordination difficulty in the side of the body opposite to the thalamotomy. No other complications of any kind have been seen in any of the other patients. For radiofrequency thalamotomy, the complication rate has been variously estimated from as low as five percent to as high as 20% or 25%. These complications can include paralysis, loss of feeling, difficulties with speech and, in a rare case, severe hemorrhage requiring a major operation (craniotomy) to remove a large blood clot within the brain or on the surface of the brain. It is our belief that radiosurgical thalamotomy with the Gamma Knife® offers the safest method for treatment of tremor. Figure 3 shows a lesion created in the thalamus by radiosurgical thalamotomy.

KQ3 and KQ4

By the end of 1998, it had been reported that 814 patients had received Gamma Knife® treatment for Parkinson's disease at all Gamma Knife® centers throughout the world, and a significant number of additional patients had received treatment for essential tremor and other forms of tremor. The interest in using radiosurgery to treat movement disorders is increasing. It is attractive to patients and their families because of its effectiveness and safety. Many radiosurgical centers perform the procedures on an outpatient basis and, at maximum, an overnight stay is required. Patients are able to return to normal activities immediately without the recovery period generally required after an open skull procedure, such as a radiofrequency thalamotomy or deep brain stimulator implantation.

This procedure is not performed with EBRT.

Dr. Deane B. Jacques is a practicing neurosurgeon at Good Samaritan Hospital in Los Angeles, California. He can be reached at +213-977-2920. Dr. Ronald F. Young is a practicing neurosurgeon at both Good Samaritan Hospital in Los Angeles, California, and Swedish Hospital in Seattle, Washington. He can be reached in Los Angeles at +213-977-2920 and in Seattle at +206-320-7130.

Gliomas

KQ1, KQ2, KQ3 and KQ4

Stereotactic Radiosurgery Prolongs Survival

GLIOBLASTOMA MULTIFORME...
Researchers at the University of Maryland examined the results of treating 64 glioblastoma multiforme patients with either external beam radiotherapy (EBRT) alone or EBRT followed by Gamma Knife® radiosurgery. Forty-five and 19 patients had previously undergone craniotomies and stereotactic localization needle biopsies, respectively. Subsequently, 33 patients were treated with EBRT alone, while 31 patients were treated with EBRT and Gamma Knife® within four weeks of EBRT. External beam radiotherapy was delivered in a three-dimensional conformal manner. Median survival for the group with EBRT alone was 13 months from the time of diagnosis, while median survival for the group that received EBRT and a Gamma Knife® boost was 25 months from the time of diagnosis.

- *from Neurosurgery 2002;50(1):41-47.*

ANAPLASTIC ASTROCYTOMA AND GLIOBLASTOMA MULTIFORME...
During an 8 year period, University of Pittsburgh researchers studied the effect of stereotactic radiosurgery with the Gamma Knife on the survival of patients with anaplastic astrocytoma or glioblastoma multiforme. Tumor diagnosis was obtained either through craniotomy or stereotactic biopsy. Sixty-four glioblastoma multiforme patients and 43 anaplastic astrocytoma patients were included in the study. Two year survival time for glioblastoma multiforme patients was 51%, and for anaplastic astrocytoma patients was 67%. The authors concluded that compared to historical controls, radiosurgery provided an improved survival benefit for glioblastoma multiforme and anaplastic astrocytoma patients. Radiosurgery was and is well tolerated with no acute neurological complications after treatment. Further studies with radiosurgery as an adjunct treatment are warranted.

- *from Neurosurgery 1997;41(4):776-785.*

I hope this information will help in your review. Please let me know if I can be of further assistance.

Sandra Vermeulen, MD

Executive Director, Swedish Radiosurgery Center
Swedish Hospital/Cherry Hill
Seattle, Washington

Phone: 206-320-7130

From: Pham, Huong [Huong.Pham@vmmc.org]
Sent: Tuesday, March 06, 2012 4:22 PM
To: HCA ST Health Tech Assessment Prog
Subject: Public Comment for: Stereotactic Radiation Surgery and Stereotactic Body Radiation Therapy

We at Virginia Mason Medical center feel strongly that there is good supporting evidence for the Washington State Health Care Authority to cover the services listed below.

Stereotactic radiosurgery/stereotactic radiation therapy
There is high level evidence for the effectiveness of stereotactic radiosurgery (SRS) for many small intracranial lesions such as arteriovenous malformations (AVM), acoustic neuromas, meningiomas, and brain metastases. SRS or SRT may also be useful for pituitary adenomas and recurrent malignant gliomas. SRS has also demonstrated effectiveness for functional disorders such as trigeminal neuralgia and essential tremor from Parkinson's disease. For many of these, SRS offers an alternative to neurosurgery especially when surgery would be associated with significant risks of morbidity or mortality. In contrast to surgery, SRS can be done as an outpatient in a few hours with minimal recovery time. Often, patients can return to work or resume regular daily activities by the next day.

SRS can be delivered with devices such as Gamma Knife or Linear accelerator based technology. There is most data demonstrating the safety and effectiveness of treatment available with Gamma Knife technology. There is also a fair amount of data for linear accelerator based treatments. Less has been published with Cyberknife and Tomotherapy. Quality assurance standards and procedures are available through American Society of Therapeutic Radiology and Oncology (ASTRO) and American Association of Physicists in Medicine (AAPM). However, currently, there is really no organization or process to ensure that the center or facility performing these procedures have these processes in place. It is reassuring though that if a center is to participitate on any clinical trial through the Radiation Therapy Oncology Group (RTOG), which employs the use of SRS/SRT, they must pass a credentialing process which requires external review of the SRS/SRT process. I think is important for patients (and payors) to be aware of when deciding on where to have treatment

For AVMs, the American Stroke Association recommends that SRS should be considered for small lesions when surgery may be associated with increased risk based on anatomic location or feeding vessel anatomy [1]. The rationale is that the high dose single fraction treatment causes fibrointimal hyperplasia and ultimately obliteration of the feeding vessel. There is an overall 80 percent obliteration (success) rate by three years occurs with lesions that are 3 cm or smaller. The rate for lesions greater than 3 cm is 30 -70 % depending on dose and size. There is little data regarding the effectiveness of standard external beam radiation therapy (EBRT) for treatment of AVMs. Therefore EBRT is not recommended for the treatment of AVMs.

Acoustic neuromas (vestibular schwannomas) are commonly treated with SRS or stereotactic radiation therapy (SRT) as an alternative to surgery. There are no randomized data but many retrospective studies demonstrate its effectiveness (90% or better control of tumor growth) with few side effects (1-5 % facial or trigeminal neuropathy)[2,3]. In addition, SRS or SRT can help preserve hearing in up 70% of patients who had good hearing prior to treatment which is comparable to most surgical series. SRS or SRT is also used when there is residual disease after surgery or in the setting of recurrence after surgery. Because these tend to be small tumors near the brainstem, high precision with stereotactic approaches are recommended to minimize dose to the brainstem to avoid long term complications. With high focused, precise treatment, it may also be possible to limit dose to the cochlea which has been found to be associated with hearing loss associated with treatment. These are reasons why SRT or SRS are preferred over EBRT.

EBRT is a well established treatment for unresectable and incompletely resected benign meningiomas [4]. The typical course of treatment is 6 weeks of radiation therapy. If the tumors are small, < 3 cm, SRS or SRT may be a good option since this is a 1-5 day treatment compared to a 6 weeks. SRS appears to be as effective as surgery and is an excellent alternative to surgery for these small tumors especially when in the skull base or cavernous sinus regions when there is a high risk of morbidity with surgery. Large series of SRS have demonstrated excellent local control rates in the range of 94-98% at 5 years with low complications rate [5,6,7].

SRS is an important treatment option for patients with small brain metastases (< 3-4 cm). Many studies support its use in patients with favorable prognosis which include patients with Karnofsky performance status 70 or greater and/or controlled primary and stable systemic disease. Studies demonstrate that SRS is more cost effective than surgery for brain mets [8]. It can also be use to treat multiple brain metastases and in locations where surgery is associated with increased morbidity[9]. SRS advantages over EBRT (whole brain radiation therapy, WBRT) include shorter course of therapy(1 fx vs. 10-15 fx), less acute side effects such as hair loss and fatigue, and less late neuro-cognitive effects [10]. The main disadvantages of SRS is a small risk of radiation necrosis of around 5- 10% depending on dose and size of tumor, and the higher risk of additional brain metastases that may require additional treatment with radiosurgery or WBRT [11,12]. Local control rates are dose dependent usually around 90% especially if doses are greater than 14 Gy[13]. In addition to its effectiveness against breast, lung, and other solid tumors, SRS is also effective in tumors which are traditionally considered to be radioresistant such as renal cell, sarcomas, and melanomas [14] .Overall survival rates are the same or better for SRS vs.WBRT [15]. SRS used as a boost after WBRT has been shown to improve survival in patients with a single brain metastasis[16] SRS is also useful for progression of brain mets after WBRT [17].

SRS has been shown to be as effective as EBRT for residual or recurrent nonfunctioning pituitary adenomas. Advantages are that the treatment is 1 day vs. 5 weeks and there is less risk of pituitary dysfunction by sparing the normal pituitary tissue with the focused precise

radiation treatment [18,19]. It can also useful in recurrent secretory adenomas such as for Cushing's disease and acromegaly.

For malignant gliomas, use of SRS or SRT has been reserved primarily for treatment in the recurrent setting when pt. has already received prior EBRT and additional EBRT would be associated with increased risk of morbidity from treatment. SRS or SRT to small recurrent targets offers a relatively safe option. Survival times from SRS/SRT for recurrent gliomas can be up to 1 year[20,21].

For patients with trigeminal neuralgia refractory to medication, it is reasonable to consider surgery, rhizotomy or SRS. The rationale is to deliver very high focused radiation to the proximal nerve root causing axonal degeneration and necrosis and subsequent pain relief. Pain relief is achieved in about 70 % of patients at one year and 50% at 3 years. Often, patients can lower or discontinue their pain medications which could be disabling to the elderly patient [22-24].

In conclusion, SRS/SRT is an effective, safe, and cost effective treatment with definite advantages over EBRT for the disorders listed above.

Stereotactic body radiation therapy

Stereotactic body radiation therapy (SBRT) is similar to SRS/SRT except used for extracranial indications. Treatment is typically 3-5 fractions. There is most evidence for the use of SBRT for early stage lung cancers[25,26]. Typically, patients who are offered this treatment are not felt to be good surgical candidates due to poor lung function or other comorbidities. SBRT offers an excellent alternative as it can be done in the outpatient setting with minimal acute side effects and minimal recovery time. Studies demonstrate local control rates as high as 90% at 3 years which is much higher than can be achieved with standard EBRT which has local control rates in the range of 50-60% and requires daily M-F treatments of 7-8 weeks. Grade 3 or higher toxicities occurred in 15-25% of patients and no patients experienced a lethal toxicity. Majority of the toxicities were pulmonary which is not surprising since the majority of these patients have poor lung function at baseline.

Small peripheral lung tumors or metastasis are also well suited for SBRT due to low acute toxicity and short course therapy. The lung tissue is very sensitive to radiation therapy and therefore minimizing dose to surrounding lung tissue is critical at minimizing risk of lung toxicity. This is a key advantage of SBRT over standard EBRT in this setting.

Other indications for SBRT are under investigation including early stage prostate cancer, spine/vertebral body tumors, and liver tumors. The RTOG currently has 4 studies which involve SBRT. It's crucial that insurance companies pay for the study treatments so that improvements in therapy can be developed.

ASTRO, ACR, and AAPM have put forth guidelines for quality assurance and safety procedures needed in an SBRT program. However, there is no organization monitoring the quality of these programs or facilities. Again, facilities who do participate in RTOG studies which use SBRT do have to go through a credentialing process to have their program approved for SBRT treatment. I think this is important for patients(and payors) to be aware of when deciding on where to have treatment.

References

1. AHA Scientific Statement: Recommendations for the management of intracranial arteriovenous malformations: a statement for healthcare professionals from a special writing group of the Stroke Council, American Stroke Association. Ogilvy CS, Stieg PE, Awad I, Brown RD Jr, Kondziolka D, Rosenwasser R, Young WL, Hademenos G, Special Writing Group of the Stroke Council, American Stroke Association. Stroke. 2001;32(6):1458.

2. Radiotherapy for vestibular schwannomas: a critical review. Murphy ES, Suh JH Int J Radiat Oncol Biol Phys. 2011;79(4):985.

3. Long-term follow-up of acoustic schwannoma radiosurgery with marginal tumor doses of 12 to 13 Gy.Chopra R, Kondziolka D, Niranjan A, Lunsford LD, Flickinger JC. Int J Radiat Oncol Biol Phys. 2007;68(3):845.

4. The role of radiotherapy in the management of intracranial meningiomas: the Royal Marsden Hospital experience with 186 patients. Glaholm J, Bloom HJ, Crow JH. Int J Radiat Oncol Biol Phys. 1990;18(4):755.

5. Stereotactic radiosurgery providing long-term tumor control of cavernous sinus meningiomas. Lee JY, Niranjan A, McInerney J, Kondziolka D, Flickinger JC, Lunsford LD. J Neurosurg. 2002;97(1):65.

6. Cavernous sinus meningiomas: a large LINAC radiosurgery series. Spiegelmann R, Cohen ZR, Nissim O, Alezra D, Pfeffer R. J Neurooncol. 2010;98(2):195.

7. Gamma knife surgery of meningiomas involving the cavernous sinus: long-term follow-up of 100 patients. Skeie BS, Enger PO, Skeie GO, Thorsen F, Pedersen PH. Neurosurgery. 2010;66(4):661.

8. A cost-effectiveness and cost-utility analysis of radiosurgery vs. resection for single-brain metastases. Mehta M, Noyes W, Craig B, Lamond J, Auchter R, French M, Johnson M, Levin A, Badie B, Robbins I, Kinsella T. Int J Radiat Oncol Biol Phys. 1997;39(2):445.

9. A comparison of surgical resection and stereotactic radiosurgery in the treatment of solitary brain metastases. O'Neill BP, Iturria NJ, Link MJ, Pollock BE, Ballman KV, O'Fallon JR. .Int J Radiat Oncol Biol Phys. 2003;55(5):1169.

10. Neurocognition in patients with brain metastases treated with radiosurgery or radiosurgery plus whole-brain irradiation: a randomised controlled trial. Chang EL, Wefel JS, Hess KR, Allen PK, Lang FF, Kornguth DG, Arbuckle RB, Swint JM, Shiu AS, Maor MH, Meyers CA. Lancet Oncol. 2009;10(11):1037.

11. Radiosurgery alone or in combination with whole-brain radiotherapy for brain metastases. Pirzkall A, Debus J, Lohr F, Fuss M, Rhein B, Engenhart-Cabillic R, Wannenmacher M. J Clin Oncol. 1998;16(11):3563.

12. Adjuvant whole-brain radiotherapy versus observation after radiosurgery or surgical resection of one to three cerebral metastases: results of the EORTC 22952-26001 study. Kocher M, Soffietti R, Abacioglu U, VillàS, Fauchon F, Baumert BG, Fariselli L, Tzuk-Shina T, Kortmann RD, Carrie C, Ben Hassel M, Kouri M, Valeinis E, van den Berge D, Collette S, Collette L, Mueller RP. J Clin Oncol. 2011;29(2):134.

13. Predictors of tumor control in patients treated with linac-based stereotactic radiosurgery for metastatic disease to the brain. Schomas DA, Roeske JC, MacDonald RL, Sweeney PJ, Mehta N, Mundt AJ. Am J Clin Oncol. 2005;28(2):180.

14. Stereotactic radiosurgery without radiation therapy providing high local tumor control of multiple brain metastases from renal cell carcinoma. Muacevic A, Kreth FW, Mack A, Tonn JC, Wowra B. Minim Invasive Neurosurg. 2004;47(4):203.

15. Stereotactic radiosurgery plus whole brain radiotherapy versus radiotherapy alone for patients with multiple brain metastases. Kondziolka D, Patel A, Lunsford LD, Kassam A, Flickinger JC. Int J Radiat Oncol Biol Phys. 1999;45(2):427.

16. Whole brain radiation therapy with or without stereotactic radiosurgery boost for patients with one to three brain metastases: phase III results of the RTOG 9508 randomised trial.Andrews DW, Scott CB, Sperduto PW, Flanders AE, Gaspar LE, Schell MC, Werner-Wasik M, Demas W, Ryu J, Bahary JP, Souhami L, Rotman M, Mehta MP, Curran WJ Jr. Lancet. 2004;363(9422):1665.

17. Salvage stereotactic radiosurgery effectively treats recurrences from whole-brain radiation therapy. Chao ST, Barnett GH, Vogelbaum MA, Angelov L, Weil RJ, Neyman G, Reuther AM, Suh JH. Cancer. 2008;113(8):2198.

18. Stereotactic radiosurgery for pituitary adenomas: an intermediate review of its safety, efficacy, and role in the neurosurgical treatment armamentarium. Sheehan JP, Niranjan A, Sheehan JM, Jane JA Jr, Laws ER, Kondziolka D, Flickinger J, Landolt AM, Loeffler JS, Lunsford LD. J Neurosurg. 2005;102(4):678.

19. Gamma surgery in the treatment of nonsecretory pituitary macroadenoma. Mingione V, Yen CP, Vance ML, Steiner M, Sheehan J, Laws ER, Steiner L. J Neurosurg. 2006;104(6):876.

20. Efficacy of fractionated stereotactic reirradiation in recurrent gliomas: long-term results in 172 patients treated in a single institution. Combs SE, Thilmann C, Edler L, Debus J, Schulz-Ertner D. J Clin Oncol. 2005;23(34):8863.

21. Hypofractionated stereotactic radiation therapy: an effective therapy for recurrent high-grade gliomas. Fogh SE, Andrews DW, Glass J, Curran W, Glass C, Champ C, Evans JJ, Hyslop T, Pequignot E, Downes B, Comber E, Maltenfort M, Dicker AP, Werner-Wasik M. J Clin Oncol. 2010 Jun 20;28(18):3048-53. Epub 2010 May 17. Erratum in: J Clin Oncol. 2010 Sep 20;28(27):4280.

22. Prospective controlled trial of gamma knife surgery for essential trigeminal neuralgia. Régis J, Metellus P, Hayashi M, Roussel P, Donnet A, Bille-Turc F. J Neurosurg. 2006;104(6):913.

23. Radiosurgical treatment of trigeminal neuralgia: evaluating quality of life and treatment outcomes.Petit JH, Herman JM, Nagda S, DiBiase SJ, Chin LS. .Int J Radiat Oncol Biol Phys. 2003;56(4):1147.

24. Clinical outcomes after stereotactic radiosurgery for idiopathic trigeminal neuralgia. Maesawa S, Salame C, Flickinger JC, Pirris S, Kondziolka D, Lunsford LD. J Neurosurg. 2001; 94(1):14.

25. Timmerman R, Paulus R, Galvin J, Michalski J, Straube W, Bradley J, Fakiris A, Bezjak A, Videtic G, Johnstone D, Fowler J, Gore E, Choy H. Stereotactic Body Radiation Therapy for Inoperable Early Stage Lung Cancer. JAMA 2010; 303 (11): 1070-1076

26. Outcome in a prospective phase II trial of medically inoperable stage I non-small-cell lung cancer patients treated with stereotactic body radiotherapy. Baumann P, Nyman J, Hoyer M, Wennberg B, Gagliardi G, Lax I, Drugge N, Ekberg L, Friesland S, Johansson KA, Lund JA, Morhed E, Nilsson K, Levin N, Paludan M, Sederholm C, Traberg A, Wittgren L, Lewensohn R. J Clin Oncol. 2009 Jul 10;27(20):3290-6

Thank you for your attention and allowing us to comment on this topic.

Huong Pham, MD
Kasra Badiozamanni, MD
Michelle Yao, MD
Paul Mitsuyama, MD
Guobin Song, MD

Section of Radiation Oncology
Virginia Mason Medical Center
1100 Ninth Ave, PO Box 900
CB-RO
Seattle, WA 98111
(206) 223-6801

********** CONFIDENTIALITY DISCLAIMER **********

The information contained in this e-mail may be confidential. IF YOU RECEIVED THIS IN ERROR, please call the Virginia Mason Privacy Officer through the Virginia Mason Operator at (206) 223-6600. Thank you.

Patients: E-mail is NOT considered secure. By choosing to communicate with Virginia Mason by e-mail, you will assume the risk of a confidentiality breach. Please do not rely on e-mail communication if you or a family member is injured or is experiencing a sudden change in health status.

If you need emergency attention, call 911.

APPENDIX A. SAMPLE SRS AND SBRT POLICIES SUBMITTED BY ASTRO

American Society for Radiation Oncology (ASTRO)
Stereotactic Radiosurgery (SRS) Model Coverage Policy

AMA CPT / Copyright Statement

CPT® codes, descriptions and other data only are copyright 2010 American Medical Association (or such other date of publication of CPT). CPT is a registered trademark of the American Medical Association. All Rights Reserved.

Indications and Limitations of Coverage and/or Medical Necessity

This Model Policy[1] addresses coverage for Stereotactic Radiosurgery (SRS).

Stereotactic Radiosurgery (SRS) is a distinct discipline that utilizes externally generated ionizing radiation in certain cases to inactivate or eradicate a defined target(s) in the head or spine without the need to make an incision. The target is defined by high-resolution stereotactic imaging. To assure quality of patient care, the procedure involves a multidisciplinary team consisting of a neurosurgeon, radiation oncologist, and medical physicist. (For a subset of tumors involving the skull base, the multidisciplinary team may also include a head and neck surgeon with training in stereotactic radiosurgery).

The adjective "Stereotactic" describes a procedure during which a target lesion is localized relative to a fixed three dimensional reference system, such as a rigid head frame affixed to a patient, fixed bony landmarks, a system of implanted fiducial markers, or other similar system. This type of localization procedure allows physicians to perform image-guided procedures with a high degree of anatomic accuracy and precision.

Stereotactic radiosurgery (SRS) couples this anatomic accuracy and reproducibility with very high doses of highly precise, externally generated, ionizing radiation, thereby maximizing the ablative effect on the target(s) while minimizing collateral damage to adjacent tissues. SRS requires computer-assisted, three-dimensional planning and delivery with stereotactic and convergent-beam technologies, including, but not limited to: multiple convergent cobalt sources (e.g. Gamma Knife®); protons; multiple, coplanar or non-coplanar photon arcs or angles (e.g. XKnife®); fixed photon arcs; or image-directed robotic devices (e.g. CyberKnife®) that meet the criteria.

SRS typically is performed in a single session, using a rigidly attached stereotactic guiding device, other immobilization technology and/or a stereotactic-guidance system, but can be performed in a limited number of sessions, up to a maximum of five.

Regardless of the number of sessions, all SRS procedures include the following components:

1. Position stabilization (attachment of a frame or frameless)
2. Imaging for localization (CT, MRI, angiography, PET, etc.)
3. Computer assisted tumor localization (i.e. "Image Guidance")

[1] ASTRO model policies were developed as a means to efficiently communicate what ASTRO believes to be correct coverage policies for radiation oncology services. The ASTRO Model Policies do not serve as clinical guidelines and they are subject to periodic review and revision without notice. The ASTRO Model Policies may be reproduced and distributed, without modification, for noncommercial purposes.

4. Treatment planning - number of isocenters, number, placement and length of arcs or angles, number of beams, beam size and weight, etc.
5. Isodose distributions, dosage prescription and calculation
6. Setup and accuracy verification testing
7. Simulation of prescribed arcs or fixed portals

Radiation oncologists and neurosurgeons have separate CPT billing codes for SRS. CPT Codes 61781–61783, 61796-61800 and 63620 and 63621 are reported for the work attributed to the neurosurgeon. These codes are mutually exclusive with the radiation oncology CPT codes 77432 and 77435; therefore the same physician should not bill for both of these codes.

A radiation oncologist may bill the SRS management code 77432 (*stereotactic radiation treatment management of cranial lesion(s) (complete course of treatment consisting of one session*) for single fraction intracranial SRS (and only once per treatment course) when and only when fully participating in the management of the procedure. CPT 77432 will be paid only once per course of treatment for cranial lesions regardless of the number of lesions. When SRS is administered in more than one but not more than five fractions to the brain or in one through five fractions to the spine, the radiation oncologist should instead bill the Stereotactic Body Radiation Therapy (SBRT) code 77435 to cover patient management during that course of therapy. CPT 77435 will be paid only once per course of therapy regardless of the number of sessions, lesions or days of treatment. The radiation oncologist may not bill 77432 and 77435 for the same course of therapy. In addition to the management codes, a radiation oncologist may bill other appropriate radiation oncology (77xxx) codes for services performed prior to the delivery of SRS as indicated by the pattern of care and other Medicare policies.

No one physician may bill both the neurosurgical codes 61781-83, 61796–61800, 63620 or 63621 and the radiation oncology 77XXX codes. If either the radiation oncologist or the neurosurgeon does not fully participate in the patient's care, that physician must take care to indicate this change by use of the appropriate -54 modifier (followed by any appropriate -55 modifier) on the global procedure(s) submitted. As the services are collegial in nature with different specialties providing individual components of the treatment, surgical assistants will not be reimbursed.

The technical charges used by hospital-based and outpatient facilities for SRS delivery are described by the CPT codes listed below. It is not appropriate to bill more than one treatment delivery code on the same day of service, even though some types of delivery may have elements of several modalities (for example, a stereotactic approach with IMRT). Only one delivery code is to be billed.

Other radiation oncology professional and technical services required prior to the delivery of SRS are coded separately and may be appropriately billed by the radiation oncologist, when necessary.

Indications for SRS:

1. Primary central nervous system malignancies, generally used as a boost or salvage therapy for lesions <5cm.
2. Primary and secondary tumors involving the brain or spine parenchyma, meninges/dura, or immediately adjacent bony structures.
3. Benign brain tumors and spinal tumors such as meningiomas, acoustic neuromas, other schwannomas, pituitary adenomas, pineocytomas, craniopharyngiomas, glomus tumors, hemangioblastomas
4. Arteriovenous malformations and cavernous malformations.
5. Other cranial non-neoplastic conditions such as trigeminal neuralgia and select cases of medically refractory epilepsy. As a boost treatment for larger cranial or spinal lesions that have been treated initially with external beam radiation therapy or surgery (e.g. sarcomas, chondrosarcomas, chordomas, and nasopharyngeal or paranasal sinus malignancies).
6. Metastatic brain or spine lesions, with stable systemic disease, Karnofsky Performance Status 40 or greater (and expected to return to 70 or greater with treatment), and otherwise reasonable survival expectations, OR an Eastern Cooperative Oncology Group (ECOG) Performance Status of 3 or less (or expected to return to 2 or less with treatment).
7. Relapse in a previously irradiated cranial or spinal field where the additional stereotactic precision is required to avoid unacceptable vital tissue radiation.

Limitations:

SRS is not considered medically necessary under the following circumstances:

1. Treatment for anything other than a severe symptom or serious threat to life or critical functions.
2. Treatment unlikely to result in functional improvement or clinically meaningful disease stabilization, not otherwise achievable.
3. Patients with wide-spread cerebral or extra-cranial metastases with limited life expectancy unlikely to gain clinical benefit within their remaining life.
4. Patients with poor performance status (Karnofsky Performance Status less than 40 or ECOG Performance greater than 3) - see Karnofsky and ECOG Performance Status scales below.
5. For ICD-9-CM code 333.1, essential tremor, coverage should be limited to the patient who cannot be controlled with medication, has major systemic disease or coagulopathy, and who is unwilling or unsuited for open surgery. Coverage should further be limited to unilateral thalamotomy.

Karnofsky Performance Status Scale

100	Normal; no complaints, no evidence of disease
90	Able to carry on normal activity; minor signs or symptoms of disease
80	Normal activity with effort; some signs or symptoms of disease
70	Cares for self; unable to carry on normal activity or to do active work
60	Requires occasional assistance but is able to care for most needs
50	Requires considerable assistance and frequent medical care
40	Disabled; requires special care and assistance
30	Severely disabled; hospitalization is indicated although death not imminent
20	Very sick; hospitalization necessary; active supportive treatment is necessary
10	Moribund, fatal processes progressing rapidly
0	Dead

Karnofsky DA, Burchenal JH. (1949). "The Clinical Evaluation of Chemotherapeutic Agents in Cancer." In: MacLeod CM (Ed), Evaluation of Chemotherapeutic Agents. Columbia Univ Press. Page 196.

ECOG Performance Status Scale

Grade 0:	Fully active, able to carry on all pre-disease performance without restriction.
Grade 1:	Restricted in physically strenuous activity but ambulatory and able to carry out work of a light or sedentary nature, e.g. light house work, office work.
Grade 2:	Ambulatory and capable of all self-care but unable to carry out and work activities. Up and about more than 50% of waking hours.
Grade 3:	Capable of only limited self-care, confined to bed or chair more than 50% of waking hours.
Grade 4:	Completely disabled. Cannot carry on any self-care. Totally confined to bed or chair.
Grade 5:	Dead

Eastern Cooperative Oncology Group, Robert Comis M.D., Group Chair.

* As published in Am. J. Clin. Oncol.:*Oken, M.M., Creech, R.H., Tormey, D.C., Horton, J., Davis, T.E., McFadden, E.T., Carbone, P.P.: Toxicity And Response Criteria Of The Eastern Cooperative Oncology Group. Am J Clin Oncol 5:649-655, 1982.*

CPT/HCPCS Codes

Note: Uses of 77435 and 77373 are addressed in both this Model Policy and in the Stereotactic Body Radiation Therapy Model Policy.

77371 Radiation treatment delivery, stereotactic radiosurgery (SRS), complete course of treatment of cranial lesion(s) consisting of 1 session; multi-source Cobalt 60 based

77372 Radiation treatment delivery, stereotactic radiosurgery (SRS), complete course of treatment of cranial lesion(s) consisting of 1 session; linear accelerator based

77373 Stereotactic body radiation therapy, treatment delivery, per fraction to 1 or more lesions, including image guidance, entire course not to exceed 5 fractions. (Do not report 77373 in conjunction with 77401-77416, 77418). (For single fraction cranial lesion, see 77371, 77372)

77432 Stereotactic radiation treatment management of cranial lesion(s) (complete course of treatment consisting of 1 session)

(The same physician should not report both stereotactic radiosurgery services [61796-61800] and radiation treatment management [77432 or 77435] for cranial lesions)

(For stereotactic body radiation therapy treatment, use 77435)

77435 Stereotactic body radiation therapy, treatment management, per treatment course, to 1 or more lesions, including image guidance, entire course not to exceed 5 fractions
(Do not report 77435 in conjunction with 77427-77432)
(The same physician should not report both stereotactic radiosurgery services [63620, 63621] and radiation treatment management [77435] for extracranial lesions)

G0173 Linear accelerator based stereotactic radiosurgery, complete course of therapy in one session

G0251 Linear accelerator based stereotactic radiosurgery, delivery including collimator changes and custom plugging, fractionated treatment, all lesions, per session, maximum five sessions per course of treatment

G0339 Image-guided robotic linear accelerator-based stereotactic radiosurgery, complete course of therapy in one session or first session of fractionated treatment

G0340 Image-guided robotic linear accelerator-based stereotactic radiosurgery, delivery including collimator changes and custom plugging, fractionated treatment, all lesions, per session, second through fifth sessions, maximum five sessions per course of treatment

ICD-9 Codes that Support Medical Necessity

Note: Diagnosis codes are based on the current ICD-9-CM codes that are effective at the time of Model Policy publication. Any updates to ICD-9-CM codes will be reviewed by ASTRO, and coverage should not be presumed until the results of such review have been published/posted. These ICD-9-CM codes support medical necessity under this Model Policy:

147.0 MALIGNANT NEOPLASM OF SUPERIOR WALL OF NASOPHARYNX
147.1 MALIGNANT NEOPLASM OF POSTERIOR WALL OF NASOPHARYNX
147.2 MALIGNANT NEOPLASM OF LATERAL WALL OF NASOPHARYNX
147.3 MALIGNANT NEOPLASM OF ANTERIOR WALL OF NASOPHARYNX

147.8 MALIGNANT NEOPLASM OF OTHER SPECIFIED SITES OF NASOPHARYNX
147.9 MALIGNANT NEOPLASM OF NASOPHARYNX UNSPECIFIED SITE
160.0 MALIGNANT NEOPLASM OF NASAL CAVITIES
160.1 MALIGNANT NEOPLASM OF AUDITORY TUBE MIDDLE EAR AND MASTOID AIR CELLS
160.2 MALIGNANT NEOPLASM OF MAXILLARY SINUS
160.3 MALIGNANT NEOPLASM OF ETHMOIDAL SINUS
160.4 MALIGNANT NEOPLASM OF FRONTAL SINUS
160.5 MALIGNANT NEOPLASM OF SPHENOIDAL SINUS
160.8 MALIGNANT NEOPLASM OF OTHER ACCESSORY SINUSES
160.9 MALIGNANT NEOPLASM OF ACCESSORY SINUS UNSPECIFIED
191.0 MALIGNANT NEOPLASM OF CEREBRUM EXCEPT LOBES AND VENTRICLES
191.1 MALIGNANT NEOPLASM OF FRONTAL LOBE
191.2 MALIGNANT NEOPLASM OF TEMPORAL LOBE
191.3 MALIGNANT NEOPLASM OF PARIETAL LOBE
191.4 MALIGNANT NEOPLASM OF OCCIPITAL LOBE
191.5 MALIGNANT NEOPLASM OF VENTRICLES
191.6 MALIGNANT NEOPLASM OF CEREBELLUM NOS
191.7 MALIGNANT NEOPLASM OF BRAIN STEM
191.8 MALIGNANT NEOPLASM OF OTHER PARTS OF BRAIN
191.9 MALIGNANT NEOPLASM OF BRAIN UNSPECIFIED SITE
192.0 MALIGNANT NEOPLASM OF CRANIAL NERVES
192.1 MALIGNANT NEOPLASM OF CEREBRAL MENINGES
194.3 MALIGNANT NEOPLASM OF PITUITARY GLAND AND CRANIOPHARYNGEAL DUCT
194.4 MALIGNANT NEOPLASM OF PINEAL GLAND
194.6 MALIGNANT NEOPLASM OF AORTIC BODY AND OTHER PARAGANGLIA
198.3 SECONDARY MALIGNANT NEOPLASM OF BRAIN AND SPINAL CORD
198.4* SECONDARY MALIGNANT NEOPLASM OF OTHER PARTS OF NERVOUS SYSTEM
198.5* SECONDARY MALIGNANT NEOPLASM OF BONE AND BONE MARROW
198.89* SECONDARY MALIGNANT NEOPLASM OF OTHER SPECIFIED SITES
225.0 BENIGN NEOPLASM OF BRAIN
225.1 BENIGN NEOPLASM OF CRANIAL NERVES
225.2 BENIGN NEOPLASM OF CEREBRAL MENINGES
227.3 BENIGN NEOPLASM OF PITUITARY GLAND AND CRANIOPHARYNGEAL DUCT
227.4 BENIGN NEOPLASM OF PINEAL GLAND
227.5 BENIGN NEOPLASM OF CAROTID BODY
227.6 *BENIGN NEOPLASM OF AORTIC BODY AND OTHER PARAGANGLIA
228.02 HEMANGIOMA OF INTRACRANIAL STRUCTURES
237.0 NEOPLASM OF UNCERTAIN BEHAVIOR OF PITUITARY GLAND AND CRANIOPHARYNGEAL DUCT
237.1 NEOPLASM OF UNCERTAIN BEHAVIOR OF PINEAL GLAND
237.3* NEOPLASM OF UNCERTAIN BEHAVIOR OF PARAGANGLIA
237.5* NEOPLASM OF UNCERTAIN BEHAVIOR OF BRAIN AND SPINAL CORD
237.6* NEOPLASM OF UNCERTAIN BEHAVIOR OF MENINGES

239.6* NEOPLASM OF UNSPECIFIED NATURE OF BRAIN
239.7* NEOPLASM OF UNSPECIFIED NATURE OF ENDOCRINE GLANDS AND OTHER PARTS OF NERVOUS SYSTEM
332.0 PARALYSIS AGITANS
333.1** ESSENTIAL AND OTHER SPECIFIED FORMS OF TREMOR
345.11 GENERALIZED CONVULSIVE EPILEPSY WITH INTRACTABLE EPILEPSY
345.3 GRAND MAL STATUS EPILEPTIC
345.91 EPILEPSY UNSPECIFIED WITH INTRACTABLE EPILEPSY
350.1 TRIGEMINAL NEURALGIA
350.8 OTHER SPECIFIED TRIGEMINAL NERVE DISORDERS
350.9 TRIGEMINAL NERVE DISORDER UNSPECIFIED
351.0 BELL'S PALSY
351.1 GENICULATE GANGLIONITIS
351.8 OTHER FACIAL NERVE DISORDERS
351.9 FACIAL NERVE DISORDER UNSPECIFIED
352.0* DISORDERS OF OLFACTORY (1ST) NERVE
352.1* GLOSSOPHARYNGEAL NEURALGIA
352.2* OTHER DISORDERS OF GLOSSOPHARYNGEAL (9TH) NERVE
352.3* DISORDERS OF PNEUMOGASTRIC (10TH) NERVE
352.4* DISORDERS OF ACCESSORY (11TH) NERVE
352.5* DISORDERS OF HYPOGLOSSAL (12TH) NERVE
352.6* MULTIPLE CRANIAL NERVE PALSIES
352.9* UNSPECIFIED DISORDER OF CRANIAL NERVES
747.81* CONGENITAL ANOMALIES OF CEREBROVASCULAR SYSTEM
990*** EFFECTS OF RADIATION UNSPECIFIED

* ICD-9-CM codes 198.4, 198.5, 198.89, 234.8, 237.5, 237.6, 239.6, 239.7, 333.1, 352.0, 352.1, 352.2, 352.3, 352.4, 352.5, 352.6, 352.9 and 747.81 are all limited to use for lesions occurring either above the neck or in the spine.

** ICD-9-CM 333.1 code is limited to the patient who cannot be controlled with medication, has major systemic disease or coagulopathy, and who is unwilling or unsuited for open surgery.

*** ICD-9-CM 990 may only be used where prior radiation therapy to the site is the governing factor necessitating SRS in lieu of other radiotherapy. An ICD-9-CM code for the anatomic diagnosis must also be used.

General Information

Documentation Requirements

The patient's record must support the necessity and frequency of treatment. Medical records should include not only the standard history and physical but also the patient's functional status and a description of current performance status (Karnofsky Performance Status or ECOG Performance Status). See Karnofsky Performance Status or ECOG Performance Status listed under Indications and Limitation of Coverage above.

Documentation should include the date and the current treatment dose. A radiation oncologist and a neurosurgeon must evaluate the clinical aspects of the treatment, and document and sign this evaluation as well as the resulting management decisions. A radiation oncologist and medical physicist must evaluate the technical aspects of the treatment and document and sign this evaluation as well as the resulting treatment management decisions.

For Medicare claims, the HCPCS/CPT code(s) may be subject to Correct Coding Initiative (CCI) edits. This policy does not take precedence over CCI edits. Please refer to the CCI for correct coding guidelines and specific applicable code combinations prior to billing Medicare.

SRS References

1. Adler JR Jr, Gibbs IC, Puataweepong P, Chang SD. Visual field preservation after multisession cyberknife radiosurgery for perioptic lesions. Neurosurgery. 2006 Aug; 59(2):244-54; discussion 244-54.

2. American College of Radiology ACR Appropriateness Criteria Brain Metastasis. 2006. Accessed April 2009. Available at: http://www.acr.org/SecondaryMainMenuCategories/quality_safety/app_criteria/pdf/Expert

3. American College of Radiology Practice Guideline for the performance of Stereotactic Radiosurgery. Effective 10/01/2006. Accessed April 2009. Available at URL address: http://www.acr.org/ SecondaryMainMenuCategories/ quality_safety/guidelines/ro/ stereotactic_radiosurgery.aspx

4. American College of Radiology Practice Guideline for the Performance of Stereotactic Body Radiation Therapy. Amended 2006 Accessed April 2009. Available at: http://www.acr.org /Secondary MainMenuCategories /quality_safety/ guidelines /ro/stereo_body_radiation.aspx

5. American Society for Radiation Oncology (ASTRO). Report of the ASTRO Emerging Technology Committee (ETC) September 19, 2008 Stereotactic Body Radiotherapy (SBRT) For Primary Management of Early-Stage, Low-Intermediate Risk Prostate Cancer Available at: http://www.astro.org/HealthPolicy/EmergingTechnology/EvaluationProjects/documents/SBRTpros.pdf. Accessed April 2009.

6. American Society for Therapeutic Radiation and Oncology (ASTRO). The ASTRO/ACR Guide to Radiation Oncology Coding 2007. Fairfax, VA: ASTRO; 2007.

7. Andrews DW, Scott CB, Sperduto PW, Flanders AE, Gaspar LE, Schell MC, et al. Whole brain radiation therapy with or without stereotactic radiosurgery boost for patients with one to three brain metastases: phase III results of the RTOG 9508 randomised trial. Lancet. 2004 May 22; 363(9422):1665-72.

8. Aoyama H, Shirato H, Tago M, Nakagawa K, Toyoda T, Hatano K, et al. Stereotactic radiosurgery plus whole-brain radiation therapy vs stereotactic radiosurgery alone for treatment of brain metastases: a randomized controlled trial. JAMA. 2006 Jun 7; 295(21):2483-91.

9. Barajas MA, Ramirez-Guzman MG, Rodriguez-Vazquez C, Toledo-Buenrostro V, Cuevas-Solorzano A, Rodriguez-Hernandez G. Gamma Knife surgery for hypothalamic hamartomas accompanied by medically intractable epilepsy and precocious puberty: experience in Mexico. J Neurosurg. 2005 Jan; 102 Suppl: 53-5.

10. Barbaro NM, Quigg M, Broshek DK, et al. A multicenter, prospective pilot study of gamma knife radiosurgery for mesial temporal lobe epilepsy: seizure response, adverse

events, and verbal memory. Ann Neurol. 2009 Feb;65(2):167-75.

11. Barcia-Salorio JL, Barcia JA, Hernandez G, Lopez-Gomez L. Radiosurgery of epilepsy. Long-term results. Acta Neurochir Suppl (Wien). 1994; 62:111-113.

12. Barnett GH, Linskey ME, Adler JR, Cozzens JW, Friedman WA, Heilbrun MP, Lunsford LD, Schulder M, Sloan AE; American Association of Neurological Surgeons; Congress of Neurolofical Surgeons Washington Committee Stereotactic Radiosurgery Task Force. Stereotactic radiosurgery--an organized neurosurgery-sanctioned definition. J Neurosurg. 2007 Jan; 106(1):1-5.

13. Bhatnagar AK, Flickinger JC, Kondziolka D, Lunsford LD. Stereotactic radiosurgery for four or more intracranial metastases. Int J Radiat Oncol Biol Phys. 2006 Mar 1; 64(3):898-903.

14. Brisman R. Microvascular decompression vs. Gamma Knife radiosurgery for typical trigeminal neuralgia: preliminary findings. Stereotact Funct Neurosurg. 2007; 85(2-3):94-8.

15. Chang SD, Gibbs IC, Sakamoto GT, Lee E, Oyelese A, Adler JR Jr. Staged stereotactic irradiation for acoustic neuroma. Neurosurgery. 2005 Jun; 56(6):1254-61; discussion 1261-3.

16. Chougule PB, Burton-WilliamsM, Saris S, Zheng Z, Ponte B, Noren G, et al. Randomized treatment of brain metastases with Gamma Knife radiosurgery, whole brain radiotherapy or both (abstract). International Journal of Radiation Oncology, Biology, Physics 2000; 48: 114.

17. Chua DT, Sham JS, Hung KN, Leung LH, Au GK. Predictive factors of tumor control and survival after radiosurgery for local failures of nasopharyngeal carcinoma. Int J Radiat Oncol Biol Phys. 2006 Dec 1; 66(5):1415-21.

18. Cohen VM, Carter MJ, Kemeny A, Radatz M, Rennie IG. Metastasis-free survival following treatment for uveal melanoma with either stereotactic radiosurgery or enucleation. Acta Ophthalmol Scand. 2003 Aug; 81(4):383-8.

19. Dieckmann K, Georg D, Bogner J, Zehetmayer M, Petersch B, Chorvat M, et al. Optimizing LINAC based stereotactic radiotherapy of uveal melanomas: 7 years' clinical experience. Int J Radiat Oncol Biol Phys. 2006 Nov 15; 66(4 Suppl):S47-52.

20. Donnet A, Tamura M, Valade D, RJ. Trigeminal nerve radiosurgical treatment in intractable chronic cluster headache: unexpected high toxicity. Neurosurgery. 2006 Dec; 59(6):1252-7; discussion 1257.

21. Dodd RL, Ryu MR, Kamnerdsupaphon P, Gibbs IC, Chang SD Jr, Adler JR Jr. CyberKnife radiosurgery for benign intradural extramedullary spinal tumors. Neurosurgery. 2006 Apr; 58(4):674-85; discussion 674-85.

22. Duma CM. Movement disorder radiosurgery--planning, physics and complication avoidance. Prog Neurol Surg. 2007; 20:249-66.

23. ECRI Institute Health Technology Assessment Information Service (HTAIS). CyberKnife and Gamma Knife Radiosurgery for Trigeminal Neuralgia. Hotline Response. May 2007. Archived

24. Elia AE, Shih HA, Loeffler JS. Stereotactic radiation treatment for benign meningiomas. Neurosurg Focus. 2007; 23(4):E5.

25. Friehs GM, Park MC, Goldman MA, Zerris VA, NorG, Sampath P. Stereotactic radiosurgery for functional disorders. Neurosurg Focus. 2007; 23(6):E3.

26. Gagnon GJ, Henderson FC, Gehan EA, Sanford D, Collins BT, Moulds JC, Dritschilo A. Cyberknife radiosurgery for breast cancer spine metastases: a matched-pair analysis. Cancer. 2007 Oct 15; 110(8):1796-802.

27. Gerszten PC, Burton SA, Ozhasoglu C, Welch WC. Radiosurgery for spinal metastases: clinical experience in 500 cases from a single institution. Spine. 2007 Jan 15; 32(2):193-9.

28. Gerszten PC, Burton SA. Clinical Assessment of Stereotactic IGRT: Spinal Radiosurgery. Med Dosim. 2008 summer; 33(2):107-16.

29. Gerszten PC, Burton SA, Ozhasoglu C, McCue KJ, Quinn AE. Radiosurgery for benign intradural spinal tumors. Neurosurgery. 2008 Apr; 62(4):887-95; discussion 895-6.

30. Gerszten PC, Ozhasoglu C, Burton SA, Vogel WJ, Atkins BA, Kalnicki S, Welch WC. CyberKnife frameless stereotactic radiosurgery for spinal lesions: clinical experience in 125 cases. Neurosurgery. 2004 Jul; 55(1):89-98; discussion 98-9.

31. Gerszten PC, Ozhasoglu C, Burton SA, Vogel WJ, Atkins BA, Kalnicki S, Welch WC. CyberKnife frameless single-fraction stereotactic radiosurgery for benign tumors of the spine. Neurosurg Focus. 2003 May 15; 14(5):e16.

32. Gerszten PC, Burton SA, Welch WC, Brufsky AM, Lembersky BC, Ozhasoglu C, Vogel WJ. Single-fraction radiosurgery for the treatment of spinal breast metastases. Cancer. 2005a Nov 15; 104(10):2244-54.

33. Gerszten PC, Burton SA, Ozhasoglu C, Vogel WJ, Welch WC, Baar J, Friedland DM. Stereotactic radiosurgery for spinal metastases from renal cell carcinoma. J Neurosurg Spine. 2005b Oct; 3(4):288-95.

34. Gerszten PC, Burton SA, Quinn AE, Agarwala SS, Kirkwood JM Radiosurgery for the treatment of spinal melanoma metastases. Stereotact Funct Neurosurg. 2005c; 83(5-6):213-21.

35. Gerszten PC, Germanwala A, Burton SA, Welch WC, Ozhasoglu C, Vogel WJ. Combination kyphoplasty and spinal radiosurgery: a new treatment paradigm for pathological fractures. J Neurosurg Spine. 2005d Oct; 3(4):296-301.

36. Gerszten PC, Burton SA, Belani CP, Ramalingam S, Friedland DM, Ozhasoglu C, Quinn AE, McCue KJ, Welch WC. Radiosurgery for the treatment of spinal lung metastases. Cancer. 2006 Dec 1; 107(11):2653-61.

37. Gibbs IC, Kamnerdsupaphon P, Ryu MR, Dodd R, Kiernan M, Chang SD, Adler JR Jr. Image-guided robotic radiosurgery for spinal metastases. Radiother Oncol. 2007 Feb; 82(2):185-90.

38. Giller CA, Berger BD, Fink K, Bastian E. A volumetric study of CyberKnife hypofractionated stereotactic radiotherapy as salvage for progressive malignant brain tumors: initial experience. Neurol Res. 2007 Sep; 29(6):563-8.

39. Gopalan R, Dassoulas K, Rainey J, Sherman JH, Sheehan JP. Evaluation of the role of Gamma Knife surgery in the treatment of craniopharyngiomas. Neurosurg Focus. 2008; 24(5):E5.

40. Gottfried ON, Liu JK, Couldwell WT. Comparison of radiosurgery and conventional surgery for the treatment of glomus jugulare tumors. Neurosurg Focus. 2004 Aug 15; 17(2):E4.

41. Grabenbauer GG, Reinhold Ch, Kerling F, et al. Fractionated stereotactically guided radiotherapy of pharmacoresistant temporal lobe epilepsy. Acta Neurochir Suppl. 2002; 84: 65-70.

42. Gronseth G, Cruccu G, Alksne J, Argoff C, Brainin M, Burchiel K, Nurmikko T, Zakrzewska JM. Practice parameter: the diagnostic evaluation and treatment of trigeminal neuralgia (an evidence-based review): report of the Quality Standards Subcommittee of the American Academy of Neurology and the European Federation of Neurological Societies. Neurology. 2008 Oct 7; 71(15):1183-90.

43. Han JH, Kim DG, Chung HT, et al. Clinical and neuroimaging outcome of cerebral arteriovenous malformations after Gamma Knife surgery: analysis of the radiation injury rate depending on the arteriovenous malformation volume. J Neurosurg. 2008; 109(2):191-198.

44. Hara W, Loo BW Jr, Goffinet DR, Chang SD, Adler JR, Pinto HA, et al. Excellent Local Control with Stereotactic Radiotherapy Boost After External Beam Radiotherapy in Patients with Nasopharyngeal Carcinoma. Int J Radiat Oncol Biol Phys. 2007 Dec 28.

45. Hayes, Inc. HAYES Medical Technology Directory. Stereotactic Radiosurgery for Arteriovenous Malformations and Intracranial Tumors. Lansdale, PA: Hayes, Inc. January 2009.

46. Ikeda H, Jokura H, Yoshimoto T. Transsphenoidal surgery and adjuvant Gamma Knife treatment for growth hormone-secreting pituitary adenoma. J Neurosurg. 2001 Aug; 95(2):285-91.

47. International RadioSurgery Association. Radiosurgery practice guideline initiative: stereotactic radiosurgery for patients with vestibular schwannomas. Issued May 2006. Accessed April 2009. Available at: http://www.irsa.org/AN%20Guideline.pdf.

48. International RadioSurgery Association. Radiosurgery practice guideline initiative: stereotactic radiosurgery for patients with intractable typical trigeminal neuralgia who have failed medical management. Issued: September 2003. Accessed April 2009. Available at: http://www.irsa.org/ TN%20Guideline.pdf.

49. International RadioSurgery Association. Radiosurgery practice guideline initiative: stereotactic radiosurgery for patients with pituitary adenomas. Issued: April 2004. Accessed April 2009. Available at: http://www.irsa.org /Pituitary%20 Guideline.pdf

50. International RadioSurgery Association, The. Radiosurgery practice guideline initiative: stereotactic radiosurgery for patients with intracranial arteriovenous malformations. Issued September 2003. Accessed April 2009. Available at: http://www.irsa.org/AVM%20Guideline.pdf

51. Ishihara H, Saito K, Nishizaki T, Kajiwara K, Nomura S, Yoshikawa K, Harada K, Suzuki M. CyberKnife radiosurgery for vestibular schwannoma. Minim Invasive Neurosurg. 2004 Oct; 47(5):290-3.

52. Kajiwara K, Saito K, Yoshikawa K, Kato S, Akimura T, Nomura S, Ishihara H, Suzuki M. Image-guided stereotactic radiosurgery with the CyberKnife for pituitary adenomas. Minim Invasive Neurosurg. 2005 Apr; 48(2):91-6.

53. Karpinos M, Teh BS, Zeck O, Carpenter LS, Phan C, Mai WY, Lu HH, Chiu JK, Butler EB, Gormley WB, Woo SY. Treatment of acoustic neuroma: stereotactic radiosurgery vs. microsurgery. Int J Radiat Oncol Biol Phys. 2002 Dec 1; 54(5):1410-21. Stereotactic radiotherapy. Front Radiat Ther Oncol. 2007; 40:415-26.

54. Kim SH, Weil RJ, Chao ST, Toms SA, Angelov L, Vogelbaum MA, Suh JH, Barnett GH. Stereotactic radiosurgical treatment of brain metastases in older patients. Cancer. 2008 Aug 15; 113(4):834-40.

55. Kondziolka D, Ong JG, Lee JY, Moore RY, Flickinger JC, Lunsford LD. Gamma Knife thalamotomy for essential tremor. J Neurosurg. 2008 Jan; 108(1):111-7.

56. Kondziolka D, Patel A, Lunsford LD, Kassam A, Flickinger JC. Stereotactic radiosurgery plus whole brain radiotherapy versus radiotherapy alone for patients with multiple brain metastases. Int J Radiat Oncol Biol Phys. 1999 Sep 1; 45(2):427-34.

57. Kong DS, Lee JI, Lim do H, Kim KW, Shin HJ, Nam DH, et al. The efficacy of fractionated radiotherapy and stereotactic radiosurgery for pituitary adenomas: long-term results of 125 consecutive patients treated in a single institution. Cancer. 2007 Aug 15; 110(4):854-60.

58. Lee M, Kalani MY, Cheshier S, Gibbs IC, Adler JR, Chang SD. Radiation therapy and CyberKnife radiosurgery in the management of craniopharyngiomas. Neurosurg Focus. 2008; 24(5):E4.

59. Lee JY, Kondziolka D, Flickinger JC, Lunsford LD. Radiosurgery for intracranial meningiomas. Prog Neurol Surg. 2007; 20:142-9.

60. Lim M, Bower R, Nangiana JS, Adler JR, Chang SD. Radiosurgery for glomus jugulare tumors. Technol Cancer Res Treat. 2007 Oct; 6(5):419-23.

61. Lim M, Cotrutz C, Romanelli P, Schaal D, Gibbs I, Chang SD, Adler JR. Stereotactic radiosurgery using CT cisternography and non-isocentric planning for the treatment of trigeminal neuralgia. Comput Aided Surg. 2006 Jan; 11(1):11-20.

62. Lim M, Villavicencio AT, Burneikiene S, Chang SD, Romanelli P, McNeely L,McIntyre M, Thramann JJ, Adler JR. CyberKnife radiosurgery for idiopathic trigeminal neuralgia. Neurosurg Focus. 2005 May 15; 18(5):E9.

63. Linskey ME, Davis SA, Ratanatharathorn V. Relative roles of microsurgery and stereotactic radiosurgery for the treatment of patients with cranial meningiomas: a single-surgeon 4-year integrated experience with both modalities. J Neurosurg. 2005 Jan; 102 Suppl: 59-70.

64. Lipani JD, Jackson PS, Soltys SG, Sato K, Adler JR. Survival Following CyberKnife Radiosurgery and Hypofractionated Radiotherapy for Newly Diagnosed Glioblastoma Multiforme. Technol Cancer Res Treat. 2008 Jun; 7(3):249-56.

65. Madsen BL, Hsi RA, Pham HT, Fowler JF, Esagui L, Corman J. Stereotactic hypofractionated accurate radiotherapy of the prostate (SHARP), 33.5 Gy in five fractions for localized disease: first clinical trial results. Int J Radiat Oncol Biol Phys. 2007 Mar 15; 67(4):1099-105.

66. Mathieu D, Kondziolka D, Niranjan A, Flickinger J, Lunsford LD. Gamma knife radiosurgery for refractory epilepsy caused by hypothalamic hamartomas. Stereotact Funct Neurosurg. 2006; 84(2-3):82-7.

67. McClelland S 3rd, Gerbi BJ, Higgins PD, Orner JB, Hall WA. Safety and efficacy of fractionated stereotactic radiotherapy for acoustic neuromas. J Neurooncol. 2008 Jan; 86(2):191-4.

68. Meijer OW, Vandertop WP, Baayen JC, Slotman BJ. Single-fraction vs. fractionated

linac-based stereotactic radiosurgery for vestibular schwannoma: a single-institution study. Int J Radiat Oncol Biol Phys. 2003 Aug 1; 56(5):1390-6.

69. Muacevic A, Wowra B, Siefert A, Tonn JC, Steiger HJ, Kreth FW. Microsurgery plus whole brain irradiation versus Gamma Knife surgery alone for treatment of single metastases to the brain: a randomized controlled multicentre phase III trial. J Neurooncol. 2008 May; 87(3):299-307.

70. Muragaki Y, Nakamura R, Iseki H, Hori T, Takakura K. Outcome after pituitary radiosurgery for thalamic pain syndrome. Int J Radiat Oncol Biol Phys. 2007 Nov 1; 69(3):852-7.

71. Myrseth E, MP, Pedersen PH, Vassbotn FS, Wentzel-Larsen T, Lund-Johansen M. Vestibular schwannomas: clinical results and quality of life after microsurgery or Gamma Knife radiosurgery. Neurosurgery. 2005 May; 56(5):927-35; discussion 927-35.

72. National Comprehensive Cancer Network (NCCN).Web site. Clinical Practice Guidelines in Oncology. Central Nervous System Cancers V.1.2008. Accessed April 2009. Available at http://www.nccn.org/professionals/physician_gls/PDF/cns.pdf.

73. National Comprehensive Cancer Network (NCCN).Web site. Clinical Practice Guidelines in Oncology. Soft Tissue Sarcoma. V.1.2009. Accessed April 2009. Available at: http://www.nccn.org/professionals/physician_gls/PDF/sarcoma.pdf.

74. National Institute for Clinical Excellence. Stereotactic radiosurgery for trigeminal neuralgia using the Gamma Knife. August 2004.

75. National Institute for Health and Clinical Excellence. Interventional procedure Guidance IPG085 Stereotactic radiosurgery for trigeminal neuralgia using the Gamma Knife - guidance. August 2004. Accessed April 2009. Available at: http://www.nice.org.uk/nicemedia/pdf/ip/IPG085guidance .pdf.

76. National Institute for Health and Clinical Excellence. Systematic review of the clinical efficacy and safety of stereotactic radiosurgery (Gamma Knife) in the treatment of trigeminal neuralgia. 27 April 2004. Accessed April 2009. Available at: http://www.nice.org.uk /nicemedia /pdf/ip/173 systematic review.pdf.

77. Niranjan A, Jawahar A, Kondziolka D, Lunsford LD. A comparison of surgical approaches for the management of tremor: radiofrequency thalamotomy, Gamma Knife thalamotomy and thalamic stimulation. Stereotact Funct Neurosurg. 1999; 72(2-4):178-84.

78. Nishizaki T, Saito K, Jimi Y, Harada N, Kajiwara K, Nomura S, Ishihara H, Yoshikawa K, Yoneda H, Suzuki M, Gibbs IC. The role of cyberknife radiosurgery/radiotherapy for brain metastases of multiple or large-size tumors. Minim Invasive Neurosurg. 2006 Aug; 49(4):203-9.

79. Ogilvy CS, Stieg PE, Awad I, Brown RD Jr, Kondziolka D, Special Writing Group of the Stroke Council, American Stroke Association, et al. AHA Scientific Statement: Recommendations for the management of intracranial arteriovenous malformations: a statement for healthcare professionals from a special writing group of the Stroke Council, American Stroke Association. Stroke. 2001 Jun; 32(6):1458-71.

80. Okun MS, Stover NP, Subramanian T, Gearing M, Wainer BH, Holder CA, Watts RL, Juncos JL, Freeman A, Evatt ML, Schuele SU, Vitek JL, DeLong MR. Complications of Gamma Knife surgery for Parkinson disease. Arch Neurol. 2001 Dec; 58(12):1995-2002.

81. Pan DH, Guo WY, Chung WY, et al. Gamma knife radiosurgery as a single treatment modality for large cerebral arteriovenous malformations. J Neurosurg. 2000; 93(suppl 3):113-119.

82. Patil CG, Veeravagu A, Bower RS, Li G, Chang SD, Lim M, Adler JR Jr. CyberKnife radiosurgical rhizotomy for the treatment of atypical trigeminal nerve pain. Neurosurg Focus. 2007; 23(6):E9.

83. Picozzi P, Losa M, Mortini P, Valle MA, Franzin A, Attuati L, Ferrari da Passano C, Giovanelli M. Radiosurgery and the prevention of regrowth of incompletely removed nonfunctioning pituitary adenomas. J Neurosurg. 2005 Jan; 102 Suppl: 71-4.

84. Pollock BE, Stafford SL, Utter A, Giannini C, Schreiner SA. Stereotactic radiosurgery provides equivalent tumor control to Simpson Grade 1 resection for patients with small- to medium-size meningiomas. Int J Radiat Oncol Biol Phys. 2003 Mar 15; 55(4):1000-5.

85. Pollock BE. Stereotactic radiosurgery in patients with glomus jugulare tumors. Neurosurg Focus. 2004 Aug 15; 17(2):E10.

86. Pollock, BE. An evidence-based medicine review of stereotactic radiosurgery. Prog Neurol Surg. 2006; 19152-170.

87. Pollock BE, Lunsford LD, Flickinger JC, Clyde BL, Kondziolka D. Vestibular schwannoma management. Part I. Failed microsurgery and the role of delayed stereotactic radiosurgery. J Neurosurg. 1998 Dec; 89(6):944-8.

88. Quigg M, Barbaro NM. Stereotactic radiosurgery for treatment of epilepsy. Arch Neurol. 2008 Feb; 65(2):177-83.

89. Rades D, Bohlen G, Pluemer A, Veninga T, Hanssens P, Dunst J, Schild SE. Stereotactic radiosurgery alone versus resection plus whole-brain radiotherapy for 1 or 2 brain metastases in recursive partitioning analysis class 1 and 2 patients. Cancer. 2007 Jun 15; 109(12):2515-21.

90. Regis J, Arkha Y, Yomo S, Bartolomei F, Peragut JC, Chauvel P. Radiosurgery for drug-resistant epilepsies: state of the art, results and perspectives. Neurochirurgie. 2008 May;

54(3):320-31.

91. Regis J, Bartolomei F, Rey M, et al. Gamma knife surgery for mesial temporal lobe epilepsy. J Neurosurg. 2000; 93(Suppl 3):141-146.

92. Regis J, Pellet W, Delsanti C, Dufour H, Roche PH, Thomassin JM, Zanaret M, Peragut JC. Functional outcome after Gamma Knife surgery or microsurgery for vestibular schwannomas. J Neurosurg. 2002 Nov; 97(5):1091-100.

93. Regis J, Rey M, Bartolomei F, Vladyka V, Liscak R, Schrottner O, Pendl G. Gamma knife surgery in mesial temporal lobe epilepsy: a prospective multicenter study. Epilepsia. 2004 May;45(5):504-15.

94. Regis J, Scavarda D, Tamura M, et al. Epilepsy related to hypothalamic hamartomas: Surgical management with special reference to Gamma Knife surgery. Childs Nerv Syst. 2006; 22(8):881-895.

95. Regis J, Bartolomei F, de Toffol B, Genton P, Kobayashi T, Mori Y, et al. Gamma knife surgery for epilepsy related to hypothalamic hamartomas. Neurosurgery. 2000 Dec; 47(6):1343-51; discussion 1351-2.

96. Regis J, Rey M, Bartolomei F, Vladyka V, Liscak R, Schrottner O, Pendl G. Gamma knife surgery in mesial temporal lobe epilepsy: a prospective multicenter study. Epilepsia. 2004 May; 45(5):504-15.

97. Roche PH, Robitail S, Delsanti C, Marouf R, Pellet W, RJ. Radiosurgery of vestibular schwannomas after microsurgery and combined radio-microsurgery Neurochirurgie. 2004 Jun; 50(2-3 Pt 2):394-400.

98. Romanelli P, Anschel DJ. Radiosurgery for epilepsy. Lancet Neurol. 2006 Jul; 5(7):613-20.

99. Romanelli P, Heit G, Chang SD, Martin D, Pham C, Adler J. Cyberknife radiosurgery for trigeminal neuralgia. Stereotact Funct Neurosurg. 2003; 81(1-4):105-9.

100. Ryu S, Jin R, Jin JY, Chen Q, Rock J, Anderson J, Movsas B. Pain control by image-guided radiosurgery for solitary spinal metastasis. J Pain Symptom Manage. 2008 Mar; 35(3):292-8.

101. Sahgal A, Chou D, Ames C, Ma L, Lamborn K, Huang K, Chuang C, Aiken A, Pett P, Weinstein P, Larson D .Image-guided robotic stereotactic body radiotherapy for benign spinal tumors: the University of California San Francisco preliminary experience. Technol Cancer Res Treat. 2007 Dec; 6(6):595-604.

102. Schaeuble B, Cascino GD, Pollock BE, Gorman DA, Weigand S, Cohen-Gadol AA, McClelland RL. Seizure outcomes after stereotactic radiosurgery for cerebral arteriovenous

malformations. Neurology. 2004 Aug 24; 63(4):683-7.

103. Selch MT, Gorgulho A, Mattozo C, Solberg TD, Cabatan-Awang C, DeSalles AA. Linear accelerator stereotactic radiosurgery for the treatment of gelastic seizures due to hypothalamic hamartoma. Minim Invasive Neurosurg. 2005 Oct; 48(5):310-4.

104. Serizawa, Toru; Hirai, Tatsuo; Nagano, Osamu; Higuchi, Yoshinori; Matsuda, Shinji; Ono, Junichi; Saeki, Naokatsu. Gamma knife surgery for 1–10 brain metastases without prophylactic whole-brain radiation therapy: analysis of cases meeting the Japanese prospective multi-institute study (JLGK0901) inclusion criteria. Journal of Neuro-Oncology (2010) 98: 163-167, June 10, 2010

105. Sinclair J, Chang SD, Gibbs IC, Adler JR Jr. Multisession CyberKnife radiosurgery for intramedullary spinal cord arteriovenous malformations. Neurosurgery. 2006 Jun; 58(6):1081-9; discussion 1081-9.

106. Souhami L, Seiferheld W, Brachman D, Podgorsak EB, Werner-Wasik M, Lustig R, Schultz CJ, Sause W, Okunieff P, Buckner J, Zamorano L, Mehta MP, Curran WJ Jr. Randomized comparison of stereotactic radiosurgery followed by conventional radiotherapy with carmustine to conventional radiotherapy with carmustine for patients with glioblastoma multiforme: report of Radiation Therapy Oncology Group 93-05 protocol. Int J Radiat Oncol Biol Phys. 2004 Nov 1; 60(3):853-60.

107. Steinvorth S, Wenz F, Wildermuth S, et al. Cognitive function in patients with cerebral arteriovenous malformations after radiosurgery: prospective long-term follow-up. Int J Radiat Oncol Biol Phys. 2002; 54(5):1430-7.

108. Tsao MN, Lloyd N, Wong R, Chow E, Rakovitch E, Laperriere N. Whole brain radiotherapy for the treatment of multiple brain metastases. Cochrane Database of Systematic Reviews 2006, Issue 3. Art. No.: CD003869.

109. Tsao MN, Mehta MP, Whelan TJ, Morris DE, Hayman JA, Flickinger JC, Mills M, Rogers CL, Souhami L. The American Society for Therapeutic Radiology and Oncology (ASTRO) evidence-based review of the role of radiosurgery for malignant glioma. Int J Radiat Oncol Biol Phys. 2005 Sep 1; 63(1):47-55.

110. Villavicencio AT, Lim M, Burneikiene S, Romanelli P, Adler JR, McNeely L, Chang SD, Fariselli L, McIntyre M, Bower R, Broggi G, Thramann JJ. Cyberknife radiosurgery for trigeminal neuralgia treatment: a preliminary multicenter experience. Neurosurgery. 2008 Mar; 62(3):647-55; discussion 647-55.

111. Whang CJ, Kwon Y. Long-term follow-up of stereotactic Gamma Knife radiosurgery in epilepsy. Stereotact Funct Neurosurg. 1996; 66(Suppl 1):349-356.

112. Weil M. Stereotactic Radiosurgery for Brain Tumors. Hematology/Oncology Clinics of North America. 2001; 15(6).

113. Wu SX, Chua DT, Deng ML, Zhao C, Li FY, Sham JS, Wang HY, Bao Y, Gao YH, Zeng ZF. Outcome of fractionated stereotactic radiotherapy for 90 patients with locally persistent and recurrent nasopharyngeal carcinoma. Int J Radiat Oncol Biol Phys. 2007 Nov 1; 69(3):761-9.

114. Yang KJ, Wang KW, Wu HP, Qi ST. Radiosurgical treatment of intractable epilepsy with low radiation dose. Di Yi Jun Yi Da Xue Xue Bao. 2002; 22(7):645-647.

115. Yoshikawa K, Saito K, Kajiwara K, Nomura S, Ishihara H, Suzuki M. CyberKnife stereotactic radiotherapy for patients with malignant glioma. Minim Invasive Neurosurg. 2006 Apr; 49(2):110-5.

116. Young RF, Jacques S, Mark R, Kopyov O, Copcutt B, Posewitz A, Li F. Gamma knife thalamotomy for treatment of tremor: long-term results. J Neurosurg. 2000 Dec; 93 Suppl 3:128-35.

117. Young RF, Vermeulen S, Posewitz A, Shumway-Cook A. Pallidotomy with the Gamma Knife: a positive experience. Stereotact Funct Neurosurg. 1998 Oct; 70 Suppl 1:218-28.

118. Young RF, Vermeulen SS, Grimm P, Posewitz AE, Jacques DB, Rand RW, Copcutt BG. Gamma Knife thalamotomy for the treatment of persistent pain. Stereotact Funct Neurosurg. 1995; 64 Suppl 1:172-81.

119. Zesiewicz TA, Elble R, Louis ED, Hauser RA, Sullivan KL, Quality Standards Subcommittee of the American Academy of Neurology, et al. Practice parameter: therapies for essential tremor: report of the Quality Standards Subcommittee of the American Academy of Neurology. Neurology. 2005 Jun 28; 64(12):2008-20.

American Society for Radiation Oncology (ASTRO)
Stereotactic Body Radiation Therapy (SBRT) Model Coverage Policy

AMA CPT / Copyright Statement

CPT® codes, descriptions and other data only are copyright 2009 American Medical Association (or such other date of publication of CPT). CPT is a registered trademark of the American Medical Association. All Rights Reserved.

Indications and Limitations of Coverage and/or Medical Necessity

This Model Policy[1] addresses coverage for Stereotactic Body Radiation Therapy (SBRT).

SBRT is a treatment that couples a high degree of anatomic targeting accuracy and reproducibility with very high doses of extremely precise, externally generated, ionizing radiation, thereby maximizing the cell-killing effect on the target(s) while minimizing radiation-related injury in adjacent normal tissues. SBRT is used to treat extra-cranial sites as opposed to stereotactic radiosurgery (SRS) which is used to treat intra-cranial and spinal targets. However, some of the CPT codes discussed here are also utilized in the billing process for SRS and are discussed accordingly in the SRS model policy.

The adjective "stereotactic" describes a procedure during which a target lesion is localized relative to a known three dimensional reference system that allows for a high degree of anatomic accuracy and precision. Examples of devices used in SBRT for stereotactic guidance may include a body frame with external reference markers in which a patient is positioned securely, a system of implanted fiducial markers that can be visualized with low-energy (kV) x-rays, and CT-imaging-based systems used to confirm the location of a tumor immediately prior to treatment.

Treatment of extra-cranial sites requires accounting for internal organ motion as well as for patient motion. Thus, reliable immobilization or repositioning systems must often be combined with devices capable of decreasing organ motion or accounting for organ motion e.g. respiratory gating. Additionally, all SBRT is performed with at least one form of image guidance to confirm proper patient positioning and tumor localization prior to delivery of each fraction. The ASTRO/ACR Practice Guidelines for SBRT outline the responsibilities and training requirements for personnel involved in the administration of SBRT.

SBRT may be delivered in one to five sessions (fractions). Each fraction requires an identical degree of precision, localization and image guidance. Since the goal of SBRT is to maximize the potency of the radiotherapy by completing an entire course of treatment within an extremely accelerated time frame, any course of radiation treatment extending beyond five fractions is not considered SBRT and is not to be billed using these codes. SBRT is meant to represent a complete course of treatment and not be used as a boost following a conventionally fractionated course of treatment.

[1] ASTRO model policies were developed as a means to efficiently communicate what ASTRO believes to be correct coverage policies for radiation oncology services. The ASTRO model policies do not serve as clinical guidelines and they are subject to periodic review and revision without notice. The ASTRO Model Policies may be reproduced and distributed, without modification, for noncommercial purposes.

American Society for Radiation Oncology (ASTRO)
Stereotactic Body Radiation Therapy (SBRT) Model Coverage Policy

This Model Policy addresses only the CPT codes for SBRT treatment management - 77435, and SBRT treatment delivery -77373, G0339, and G0340.

When billing for SBRT *delivery*, it is not appropriate to bill more than one treatment delivery code on the same day of service, even though some types of delivery may have elements of several modalities (for example, a stereotactic approach with intensity-modulated static beams or arcs). Also, *only one* delivery code is to be billed even if multiple lesions are treated on the same day.

Indications for SBRT:

SBRT is indicated for primary tumors of and tumors metastatic to the **lung, liver, kidney, adrenal gland, or pancreas as well as for pelvic and head&neck tumors that have recurred after primary irradiation** when and only when each of the following criteria are met, and each specifically documented in the medical record. Multiple ICD-9 codes fit this description and they are not listed in detail here.

1. The patient's general medical condition (notably, the performance status) justifies aggressive treatment to a primary cancer or, for the case of metastatic disease, justifies aggressive local therapy to one or more discrete deposits of cancer within the context of efforts to achieve total clearance or clinically beneficial reduction in the patient's overall burden of systemic disease.
2. The tumor burden can be completely targeted with acceptable risk to critical normal structures.

Other Neoplasms:

SBRT is currently under investigation for other indications, including the primary treatment of prostate cancer (ICD-9 code 185). An insurer should cover treatment of these patients entered on IRB approved clinical trials.

Other Indications for SBRT:

For patients with tumors of any type arising in or near previously irradiated regions, SBRT may be appropriate when a high level of precision and accuracy is needed to minimize the risk of injury to surrounding normal tissues. Also, in other cases where a high dose per fraction treatment is indicated SBRT may be appropriate. The necessity should be documented in the medical record.

Limitations:

SBRT is not considered medically necessary under the following circumstances:

1. Treatment unlikely to result in clinical cancer control and/or functional improvement.
2. The tumor burden cannot be completely targeted with acceptable risk to critical normal structures.

American Society for Radiation Oncology (ASTRO)
Stereotactic Body Radiation Therapy (SBRT) Model Coverage Policy

3. Patients with poor performance status (Karnofsky Performance Status **less than 40 or Eastern Cooperative Oncology Group (ECOG) Status of 3 or worse)** - see Karnofsky Performance Status and ECOG Status below.

Karnofsky Performance Scale (Perez and Brady, p 225)
100 Normal; no complaints, no evidence of disease
90 Able to carry on normal activity; minor signs or symptoms of disease
80 Normal activity with effort; some signs or symptoms of disease
70 Cares for self; unable to carry on normal activity or to do active work
60 Requires occasional assistance but is able to care for most needs
50 Requires considerable assistance and frequent medical care
40 Disabled; requires special care and assistance
30 Severely disabled; hospitalization is indicated although death not imminent
20 Very sick; hospitalization necessary; active supportive treatment is necessary
10 Moribund, fatal processes progressing rapidly
0 Dead

ECOG PERFORMANCE STATUS*	
Grade	**ECOG**
0	Fully active, able to carry on all pre-disease performance without restriction
1	Restricted in physically strenuous activity but ambulatory and able to carry out work of a light or sedentary nature, e.g., light house work, office work
2	Ambulatory and capable of all self care but unable to carry out any work activities. Up and about more than 50% of waking hours
3	Capable of only limited self care, confined to bed or chair more than 50% of waking hours
4	Completely disabled. Cannot carry on any self care. Totally confined to bed or chair
5	Dead

Eastern Cooperative Oncology Group, Robert Comis M.D., Group Chair.

* As published in Am. J. Clin. Oncol.:
Oken, M.M., Creech, R.H., Tormey, D.C., Horton, J., Davis, T.E., McFadden, E.T., Carbone, P.P.: Toxicity And Response Criteria Of The Eastern Cooperative Oncology Group. Am J Clin Oncol 5:649-655, 1982.

American Society for Radiation Oncology (ASTRO)
Stereotactic Body Radiation Therapy (SBRT) Model Coverage Policy

CPT/HCPCS Codes

77435 Stereotactic body radiation therapy, treatment management, per treatment course, to 1 or more lesions, including image guidance, entire course not to exceed 5 fractions

This code will be paid only once per course of treatment and should not be reported in conjunction with any other treatment management codes (77427-77432).

The same physician should not report both the stereotactic radiosurgery services (63620, 63621) and radiation treatment management (77435). .

77373 Stereotactic body radiation therapy, treatment delivery, per fraction to 1 or more lesions, including image guidance, entire course not to exceed 5 fractions

This code should not be reported in conjunction with any other treatment delivery codes e.g. 77401-77416, 77418.

G0339 Image-guided robotic linear accelerator-based stereotactic radiosurgery, complete course of therapy in one session, or first session of fractionated treatment

G0340 Image-guided robotic linear accelerator-based stereotactic radiosurgery, delivery including collimator changes and custom plugging, fractionated treatment, all lesions, per session, second through fifth sessions, maximum five sessions per course of treatment

CPT 77373, G0339 and G0340 will be paid **only once per day of treatment regardless of the number of sessions or lesions.**

The CPT codes discussed in this Model Policy are applicable to all diagnoses listed in the ASTRO SRS Model Policy, a companion document to the SBRT model policy.

ICD-9 Codes that Support Medical Necessity

Note: Diagnosis codes are based on the current ICD-9-CM codes that are effective at the time of Model Policy publication. Any updates to ICD-9-CM codes will be reviewed by ASTRO, and coverage should not be presumed until the results of such review have been published/posted. These ICD-9-CM codes support medical necessity under this Model Policy:

Diagnosis	ICD-9 Code(s)	comment
Primary lung cancer	**162.2, 162.3, 162.4, 162.5, 162.8, 162.9**	
Thoracic lymph nodes	**196.1**	
Lung metastasis	**197.0**	
Primary liver or bile duct cancer	**155.0, 155.1, 155.2**	
Liver metastasis	**197.7**	
Kidney cancer or metastasis	**189.0, 189.1, 198.0**	
Adrenal Gland primary or metastasis	**194.0, 194.6, 198.7**	
Primary Pancreas cancer	**157.0, 157.1, 157.2, 157.3,**	

American Society for Radiation Oncology (ASTRO)
Stereotactic Body Radiation Therapy (SBRT) Model Coverage Policy

Diagnosis	ICD-9 Code(s)	comment
	157.4, 157.8, 157.9	
Pelvic cancer (rectal, gynecologic)	**multiple ICD-9 codes, 990***	recurrent after prior conventionally fractionated RT
Head & Neck cancer, multiple primary sites	**140.0 through 146.8, inclusive of numbers between, 990***	recurrent after prior conventionally fractionated RT

***990** EFFECTS OF RADIATION UNSPECIFIED

ICD-9-CM 990 may only be used where prior radiation therapy to the site is the governing factor necessitating SBRT in lieu of other radiotherapy. An ICD-9-CM code for the anatomic diagnosis must also be used.

General Information

Documentation Requirements

The patient's record must support the necessity and frequency of treatment. Medical records should include not only the standard history and physical but also the patient's functional status and a description of current performance status (Karnofsky Performance Status or ECOG Performance Status). See Karnofsky Performance Status or ECOG Performance Status listed under Indications and Limitation of Coverage and/or Medical Necessity above. A radiation oncologist must evaluate the clinical and technical aspects of the treatment, and document this evaluation as well as the resulting management decisions. Documentation of the technical aspects of treatment planning and delivery should include details of target dose and relevant dose-limiting normal structures. Documentation should include the date and the current treatment dose. All documentation must be available upon request of the insurer. For Medicare claims, the HCPCS/CPT code(s) may be subject to Correct Coding Initiative (CCI) edits. This policy does not take precedence over CCI edits. Please refer to the CCI for correct coding guidelines and specific applicable code combinations prior to billing Medicare.

American Society for Radiation Oncology (ASTRO)
Stereotactic Body Radiation Therapy (SBRT) Model Coverage Policy

SBRT References

General

1. Benedict SH, Yenice KM, Followill D, et al. Stereotactic body radiation therapy: The report of AAPM Task Group 101. Med. Phys. 37, 4078 (2010); doi:10.1118/1.3438081

2. Chang,R, Timmerman,R. Stereotactic Body Radiation Therapy A Comprehensive Review. American Journal of Clinical Oncology 2007 Dec: 30 (6): 637-644.

3. Halperin, E.C., Perez, C.A., Brady. L.W.. Principles and Practice of Radiation Therapy 5th ed. Lippincott Williams & Wilkins 2007

4. Kavanagh BD and Timmerman RD (Eds.) Stereotactic Body Radiation Therapy, Philadelphia, Lippincott Williams & Wilkins, 2005.

5. Lo S, Fakiris A, Chang E, Mayr N, Wang J, Papiez L, Teh B, McGarry R, Cardenes H, Timmerman R Stereotactic body radiation therapy: a novel treatment modality. Nat Rev Clin Oncol. 2010 Jan;7(1):44-54. Epub 2009 Dec 8.

6. Martin A, Gaya A, Stereotactic Body Radiotherapy: A Review. Clin Oncol (R Coll Radiol). 2010 Jan 19. [Epub ahead of print] (doi:10.1016/j.clon.2009.12.003)

7. Milano MT, Katz A, Muhs, AG et al. A prospective pilot study of curative-intent stereotactic body radiation therapy in patients with 5 or fewer oligometastatic lesions. Cancer. 2008 Feb 1; 112(3): 650-58.

8. Potters L, Kavanagh B, Galvin JM, Hevezi JM, Janjan NA, Larson DA, Mehta MP, Ryu S, Steinberg M, Timmerman R, Welsh JS, Rosenthal SA. American Society for Therapeutic Radiology and Oncology (ASTRO) and American College of Radiology (ACR) practice guideline for the performance of stereotactic body radiation therapy. Int J Radiat Oncol Biol Phys. 2010 Feb 1;76(2):326-32

9. Timmerman, R, Kavanagh, B, Cho, L, Papiez, L, Xing, L. Stereotactic Body Radiation Therapy in Multiple Organ Sites. Journal of Clinical Oncology 2007 March 10, 25 (8): 947-952.

Liver

1. Choi BO, Choi IB, Jang HS, Kang YN, Jang JS, Bae SH, Yoon SK, Chai GY, Kang KM. Stereotactic body radiation therapy with or without transarterial chemoembolization for patients with primary hepatocellular carcinoma: preliminary analysis. BMC Cancer. 2008 Nov 27; 8:351.

2. Katz AW, Carey-Sampson M, Muhs AG, Milano MT, Schell MC, Okunieff P. Hypofractionated stereotactic body radiation therapy (SBRT) for limited hepatic metastases. Int J Radiat Oncol Biol Phys. 2007 Mar 1;67(3):793-8.

3. Kavanagh BD, Schefter TE, Cardenes HR, Stieber VW, Raben D, Timmerman RD, McCarter MD, Burri S, Nedzi LA, Sawyer TE, Gaspar LE. Interim analysis of a prospective phase I/II trial of SBRT for liver metastases. Acta Oncol. 2006; 45(7):848-55.

4. Lee MT, Kim JJ, Dinniwell R, et al. Phase I study of individualized stereotactic body radiotherapy for liver metastases. J Clin Oncol 2009;27:1585–1591.

5. McCammon R, Schefter TE, Gaspar LE, Zaemisch R, Gravdahl D, Kavanagh B. Observation of a dose-control relationship for lung and liver tumors after stereotactic body radiation therapy. Int J Radiat Oncol Biol Phys. 2009 Jan 1;73(1):112-8.

6. Méndez Romero A, Wunderink W, Hussain SM, De Pooter JA, Heijmen BJ, Nowak PC, Nuyttens JJ, Brandwijk RP, Verhoef C, Ijzermans JN, Levendag PC. Stereotactic body radiation therapy for primary and metastatic liver tumors: A single institution phase i-ii study. Acta Oncol. 2006;45(7):831-7.

7. Méndez Romero A, Wunderink W, van Os RM, Nowak PJ, Heijmen BJ, Nuyttens JJ, Brandwijk RP, Verhoef C, Ijzermans JN, Levendag PC. Quality of life after stereotactic body radiation therapy for primary and metastatic liver tumors. Int J Radiat Oncol Biol Phys. 2008 Apr 1;70(5):1447-52.

8. Rusthoven KE, Kavanagh BD, Cardenes H, et al. Multi-institutional phase I/II trial of stereotactic body radiation therapy for liver metastases. J Clin Oncol 2009;27:1579–1584.

9. Rusthoven KE, Kavanagh BD, Cardenes H, Stieber VW, Burri SH, Feigenberg SJ, Chidel MA, Pugh TJ, Franklin W, Kane M, Gaspar LE, Schefter TE. Multi-institutional phase I/II trial of stereotactic body radiation therapy for liver metastases. J Clin Oncol. 2009 Apr 1;27(10):1572-8.

10. Schefter TE, Kavanagh BD, Timmerman RD, Cardenes HR, Baron A, Gaspar LE. A phase I trial of stereotactic body radiation therapy (SBRT) for liver metastases. Int J Radiat Oncol Biol Phys. 2005 Aug 1;62(5):1371-8.

11. Tse RV, Hawkins M, Lockwood G, Kim JJ, Cummings B, Knox J, Sherman M, Dawson LA. Phase I study of individualized stereotactic body radiotherapy for hepatocellular carcinoma and intrahepatic cholangiocarcinoma. J Clin Oncol. 2008 Feb 1;26(4):657-64.

Lung

1. Collins BT, Vahdat S, Erickson K, et al. Radical cyberknife radiosurgery with tumor tracking: an effective treatment for inoperable small peripheral stage I non-small cell lung cancer. J Hematol Oncol 2009;2:1.

2. Banki F, Luketich JD, Chen H, Christie N, Pennathur A. Stereotactic radiosurgery for lung cancer. Minerva Chir. 2009 Dec;64(6):589-98.

3. Baumann P, Nyman J, Hoyer M, et al. Outcome in a prospective phase II trial of medically inoperable stage I non-small-cell lung cancer patients treated with stereotactic body radiotherapy. J Clin Oncol 2009;27(20):3290–3296.

4. Baumann P, Nyman J, Hoyer M, Gagliardi G, Lax I, Wennberg B, Drugge N, Ekberg L, Friesland S, Johansson KA, Lund JS, Morhed E, Nilsson K, Levin N, Paludan M, Sederholm C, Traberg A, Wittgren L, Lewensohn R. Stereotactic body radiotherapy for medically inoperable patients with stage I non-small cell lung cancer - a first report of toxicity related to COPD/CVD in a non-randomized prospective phase II study. Radiother Oncol. 2008 Sep;88(3):359-67.

5. Baumann P, Nyman J, Lax I, Friesland S, Hoyer M, Rehn Ericsson S, Johansson KA, Ekberg L, Morhed E, Paludan M, Wittgren L, Blomgren H, Lewensohn R. Factors important for efficacy of stereotactic body radiotherapy of medically inoperable stage I lung cancer. A retrospective analysis of patients treated in the Nordic countries. Acta Oncol. 2006;45(7):787-95.

6. Chang JY, Balter PA, Dong L, et al. Stereotactic body radiation therapy in centrally and superiorly located stage I or isolated recurrent non-small-cell lung cancer. Int J Radiat Oncol Biol Phys 2008;72(4):967–971.

7. Chang JY, Balter PA, Dong L, Yang Q, Liao Z, Jeter M, Bucci MK, McAleer MF, Mehran RJ, Roth JA, Komaki R. Stereotactic body radiation therapy in centrally and superiorly located stage I or isolated recurrent non-small-cell lung cancer. Int J Radiat Oncol Biol Phys. 2008 Nov 15;72(4):967-71.

8. Chen Y, Guo W, Lu Y, Zou B. Dose-individualized stereotactic body radiotherapy for T1-3N0 non-small cell lung cancer: long-term results and efficacy of adjuvant chemotherapy. Radiother Oncol. 2008 Sep;88(3):351-8.

9. Coons D, Gokale A, Burton A, Heron D, Ozhasoglu C, Christie N. Fractionated stereotactic body radiation therapy in the treatment of primary, recurrent, and metastatic lung tumors: the role of positron emission tomography/computed tomography-based treatment planning. Clin Lung Cancer 2008; 9(4):217-221.

10. Fakiris, A. J. et al. Stereotactic body radiation therapy for early-stage non-small-cell lung carcinoma: four-year results of a prospective phase II study. Int. J. Radiat. Oncol. Biol. Phys. 2009; 75, 677–682.

11. Fritz P, Kraus HJ, Blaschke T, Mühlnickel W, Strauch K, Engel-Riedel W, Chemaissani A, Stoelben E. Stereotactic, high single-dose irradiation of stage I non-small cell lung cancer (NSCLC) using four-dimensional CT scans for treatment planning. Lung Cancer. 2008 May;60(2):193-9.

12. Guckenberger M, Wulf J, Mueller G, Krieger T, Baier K, Gabor M, Richter A, Wilbert J, Flentje M. Response Relationship for Image-Guided Stereotactic Body Radiotherapy of Pulmonary Tumors: Relevance of 4d Dose Calculation. Int J Radiat Oncol Biol Phys. 2009 Feb 1;73(2):442-8. Epub 2008 Nov 5.

13. Henderson M, McGarry R, Yiannoutsos C, Fakiris A, Hoopes D, Williams M, Timmerman R. Baseline pulmonary function as a predictor for survival and decline in pulmonary function over time in patients undergoing stereotactic body radiotherapy for the treatment of stage I non-small-cell lung cancer. Int J Radiat Oncol Biol Phys. 2008 Oct 1;72(2):404-9.

14. Hiraoka M, Matsuo Y, Nagata Y. Stereotactic body radiation therapy (SBRT) for early-stage lung cancer. Cancer Radiother. 2007 Jan-Feb;11(1-2):32-5.

15. Joyner M, Salter BJ, Papanikolaou N, Fuss M. Stereotactic body radiation therapy for centrally located lung lesions. Acta Oncol. 2006;45(7):802-7.

16. Koto M, Takai Y, Ogawa Y, Matsushita H, Takeda K, Takahashi C, Britton KR, Jingu K, Takai K, Mitsuya M, Nemoto K, Yamada S. A phase II study on stereotactic body radiotherapy for stage I non-small cell lung cancer. Radiother Oncol. 2007 Dec;85(3):429-34.

17. McCammon R, Schefter TE, Gaspar LE, Zaemisch R, Gravdahl D, Kavanagh B. Observation of a dose-control relationship for lung and liver tumors after stereotactic body radiation therapy. Int J Radiat Oncol Biol Phys. 2009 Jan 1;73(1):112-8.

18. McGarry RC, Papiez L, Williams M, Whitford T, Timmerman RD. Stereotactic body radiation therapy of early-stage non-small-cell lung carcinoma: phase I study. Int J Radiat Oncol Biol Phys. 2005 Nov 15;63(4):1010-5.

19. Norihisa Y, Nagata Y, Takayama K, Matsuo Y, Sakamoto T, Sakamoto M, Mizowaki T, Yano S, Hiraoka M. Stereotactic body radiotherapy for oligometastatic lung tumors. Int J Radiat Oncol Biol Phys. 2008 Oct 1;72(2):398-403.

20. Okunieff P, Petersen AL, Philip A, Milano MT, Katz AW, Boros L, Schell MC. Stereotactic Body Radiation Therapy (SBRT) for lung metastases. Acta Oncol. 2006; 45(7):808-17.

21. Pennathur A, Luketick J, Heron D, Schuchert M, Burton S, et. al. Stereotactic radiosurgery for the treatment of lung neoplasm: experience in 100 consecutive patients. Ann Thorac Surg 2009; 88:1594-1600,

22. Rusthoven KE, Kavanagh BD, Burri SH, Chen C, Cardenes H, Chidel MA, Pugh TJ, Kane M, Gaspar LE, Schefter TE. Multi-institutional phase I/II trial of stereotactic body radiation therapy for lung metastases. J Clin Oncol. 2009 Apr 1;27(10):1579-84

23. Salazar OM, Sandhu TS, Lattin PB, Chang JH, Lee CK, Groshko GA, Lattin CJ. Once-weekly, high-dose stereotactic body radiotherapy for lung cancer: 6-year analysis of 60

early-stage, 42 locally advanced, and 7 metastatic lung cancers. Int J Radiat Oncol Biol Phys. 2008 Nov 1;72(3):707-15

24. Schefter TE, Kavanagh BD, Raben D, et al. A Phase I trial of SBRT for Lung Metastases. I Schefter TE, Kavanagh BD, Raben D, et al Int J Radiat Oncol Biol Phys. 2006;66(4 Suppl):S120-7.

25. Scorsetti M, Navarria P, Facoetti A, Lattuada P, Urso G, Mirandola A, Ferraroli GM, Alloisio M, Ravasi G. Effectiveness of stereotactic body radiotherapy in the treatment of inoperable early-stage lung cancer. Anticancer Res. 2007 Sep-Oct;27(5B):3615-9.

26. Senan S, Lagerwaard F. Stereotactic radiotherapy for stage I lung cancer: Current results and new developments. Cancer Radiother. 2010 Feb 25. [Epub ahead of print]

27. Sonke, J. J. et al. Frameless stereotactic body radiotherapy for lung cancer using four dimensional cone beam CT guidance. Int. J. Radiat. Oncol. Biol. Phys. 2009; 74, 567–574.

28. Takeda A, Sanuki N, Kunieda E, Ohashi T, Oku Y, Takeda T, Shigematsu N, Kubo A. Stereotactic Body Radiotherapy for Primary Lung Cancer at a Dose of 50 Gy Total in Five Fractions to the Periphery of the Planning Target Volume Calculated Using a Superposition Algorithm. Int J Radiat Oncol Biol Phys. 2008 Nov 4. [Epub ahead of print]

29. van der Voort van Zyp NC, Prevost J-B, Hoogeman MS, et al. Stereotactic radiotherapy with real-time tumor tracking for non-small cell lung cancer: clinical outcome. Radiother Oncol 2009;91(3):296–300.

30. van der Voort van Zyp NC, van der Holt B, van Klaveren RJ, Pattynama P, Maat A, Nuyttens JJ. Stereotactic body radiotherapy using real-time tumor tracking in octogenarians with non-small cell lung cancer. Lung Cancer. 2010 Jan 6. [Epub ahead of print]

31. Zimmermann F, Wulf J, Lax I, Nagata Y, Timmerman RD, Stojkovski I, Jeremic B.Stereotactic Body Radiation Therapy for Early Non-Small Cell Lung Cancer. Front Radiat Ther Oncol. 2010;42:94-114. Epub 2009 Nov 24.

Pancreas

1. Chang DT, Schellenberg D, Shen J, Kim J, Goodman KA, Fisher GA, Ford JM, Desser T, Quon A, Koong AC. Stereotactic radiotherapy for unresectable adenocarcinoma of the pancreas. Cancer. 2009 Feb 1;115(3):665-72.

2. Mahadevan A, Jain S, Goldstein M, Miksad R, Pleskow D, Sawhney M, Brennan D, Callery M, Vollmer C. Stereotactic Body Radiotherapy and Gemcitabine for Locally Advanced Pancreatic Cancer. Int J Radiat Oncol Biol Phys. 2010 Feb 18. [Epub ahead of print]

3. Rwigema J, Parihk S, Heron D, et al. Stereotactic body radiotherapy in the treatment of advanced adenocarcinoma of the pancreas. Am J Clin Oncol 2010, DOI10.1097/COC.0b013e3181d270b4, Article In Press.

4. Schellenberg D, Goodman KA, Lee F, et al. Gemcitabine chemotherapy and single-fraction stereotactic body radiotherapy for locally advanced pancreatic cancer. Int J Radiat Oncol Biol Phys 2008;72:678–686.

5. Schellenberg D, Quon A, Yuriko Minn A et al. ^{18}Fluorodeoxyglucose PET is prognostic of progression-free and overall survival in locally advanced pancreas cancer treated with stereotactic radiotherapy. Int. J. Radiat Oncol Biol Phys. 2010 Aug 1; 77(5): 1420- 1425.

Prostate

1. King CR, Brooks JD, Gill H, et al. Stereotactic body radiotherapy for localized prostate cancer: interim results of a prospective phase II clinical trial. Int J Radiat Oncol Biol Phys 2009;73(4):1043–1048.

2. Katz AJ, Santoro M, Ashley R, Diblasio F, Witten M. Stereotactic body radiotherapy for organ-confined prostate cancer. BMC Urol. 2010 Feb 1;10(1):1. [Epub ahead of print]

3. Madsen BL, Hsi RA, Pham HT, Fowler JF, Esagui L, Corman J. Stereotactic hypofractionated accurate radiotherapy of the prostate (SHARP), 33.5 Gy in five fractions for localized disease: first clinical trial results. Int J Radiat Oncol Biol Phys. 2007 Mar 15;67(4):1099-105.

Spine

1. Chang EL, Shiu AS, Lii MF, Rhines LD, Mendel E, Mahajan A, Weinberg JS, Mathews LA, Brown BW, Maor MH, Cox JD. Phase I clinical evaluation of near-simultaneous computed tomographic image-guided stereotactic body radiotherapy for spinal metastases. Int J Radiat Oncol Biol Phys. 2004 Aug 1;59(5):1288-94.

2. Chang EL, Shiu AS, Mendel E, Mathews LA, Mahajan A, Allen PK, Weinberg JS, Brown BW, Wang XS, Woo SY, Cleeland C, Maor MH, Rhines LD. Phase I/II study of stereotactic body radiotherapy for spinal metastasis and its pattern of failure. J Neurosurg Spine. 2007 Aug;7(2):151-60.

3. Choi CY, Adler JR, Gibbs IC, Chang SD, Jackson PS, Minn AY, Lieberson RE, Soltys SG. Stereotactic Radiosurgery for Treatment of Spinal Metastases Recurring in Close Proximity to Previously Irradiated Spinal Cord. Int J Radiat Oncol Biol Phys. 2010 Feb 2. [Epub ahead of print]

4. Gagnon GJ, Nasr NM, Liao JJ, et al. Treatment of spinal tumors using CyberKnife fractionated stereotactic radiosurgery: pain and quality of life assessment after treatment in 200 patients. Neurosurgery 2009;64(2):297–306.

5. Haley M, Gerszten P. Stereotactic Radiosurgery in the Management of Cancer Pain, Current Pain & Headache Reports 2009, 13:277–281

6. Janjan N, Lutz S, Bedwinek J, et al.Therapeutic Guidelines for the Treatment of Bone Metastasis: A Report from the American College of Radiology Appropriateness Criteria Expert Panel on Radiation Oncology Journal of Palliative Medicine. May 2009, 12(5): 417-426.

7. Nelson JW, Yoo DS, Sampson JH, et al. Stereotactic body radiotherapy for lesions of the spine and paraspinal regions. Int J Radiat Oncol Biol Phys 2009;73(5):1369–1375.

8. Papatheofanis F, Williams E, , Chang S. Cost-utility analysis of the cyberknife system For metastatic spinal tumors. Neurosurgery, 2009 ; 64 (2) A73-A82 (supplement)

9. Parikh S, Heron D. Fractionated radiosurgical management of intramedullary spinal cord metastasis: A case report and review of the literature. Clinical Neurology and Neurosurgery (2009 – Article in Press

10. Sahgal A, Ames C, Chou D, Ma L, Huang K, Xu W, Chin C, Weinberg V, Chuang C, Weinstein P, Larson DA. Stereotactic Body Radiotherapy Is Effective Salvage Therapy for Patients with Prior Radiation of Spinal Metastases. Int J Radiat Oncol Biol Phys. 71, 652–665 (2008). Epub 2008 Dec 16.

Head and Neck

1. Chen HH, Tsai ST, Wang MS, Wu YH, Hsueh WT, Yang MW, Yeh IC, Lin JC. Experience in fractionated stereotactic body radiation therapy boost for newly diagnosed nasopharyngeal carcinoma. Int J Radiat Oncol Biol Phys. 2006 Dec 1;66(5):1408-14.

2. Kawaguchi K, Sato K, et al. Stereotactic radiosurgery may contribute to overall survival for patients with recurrent head and neck carcinoma. Radiation Oncology 2010; 5(51)

3. Rwiegema J, Heron D, Ferris R, Gibson R, et al. Fraactionated stereotactic body radiation therapy in the treatment of previously-irradiated recurrent head and neck carcinoma. Updated report of the University of Pittsburgh experience. Am J Clin Oncol 2009 Epub ahead of print]

4. Unger KR, Lominska CE, Deeken JF, Davidson BJ, Newkirk KA, Gagnon GJ, Hwang J, Slack RS, Noone AM, Harter KW. Fractionated Stereotactic Radiosurgery for Reirradiation of Head-and-Neck Cancer. Int J Radiat Oncol Biol Phys. 2010 Jan 5. [Epub ahead of print]

Kidney

1. Svedman C, Karlsson K, Rutkowska E, Sandström P, Blomgren H, Lax I, Wersäll P. Stereotactic body radiotherapy of primary and metastatic renal lesions for patients with only one functioning kidney. Acta Oncol. 2008;47(8):1578-83.

American Society for Radiation Oncology (ASTRO)
Stereotactic Body Radiation Therapy (SBRT) Model Coverage Policy

Breast

1. Milano MT, Zhang H, Metcalfe SK, Muhs AG, Okunieff P. Oligometastatic breast cancer treated with curative-intent stereotactic body radiation therapy. Breast Cancer Res Treat. 2009 Jun;115(3):601-8. Epub 2008 Aug 22.

Pelvic

1. Choi C, Cho C, Yoo S, Kim M, Yang K, Yoo H, Seo Y, Kang J, Lee D, Lee K, Lee E, Rhu S, Choi S, Kim M, Kim B. Image-guided Stereotactic Body Radiation Therapy in Patients with Isolated Para-aortic Lymph Node Metastases from Uterine Cervical and Corpus Cancer. Int J Radiat Oncol Biol Phys. 2009 May 1;74(1):147-53. Epub 2008 Nov 5.

2. Kim MS, Choi C, Yoo S, Cho C, Seo Y, Ji Y, Lee D, Hwang D, Moon S, Kim MS, Kang H. Stereotactic body radiation therapy in patients with pelvic recurrence from rectal carcinoma. Jpn J Clin Oncol. 2008 Oct;38(10):695-700.

APPENDIX B. REFERENCES AND ATTACHMENTS SUBMITTED BY ELEKTA

Reference List: The Gamma Knife and the Treatment of Metastatic Brain Tumors (1989-2/2012)

1. Yamamoto, M., T. Kawabe, and B.E. Barfod, How many metastases can be treated with radiosurgery? Prog Neurol Surg, 2012. 25: p. 261-72.

2. Patel, T.R., et al., Implications of Identifying Additional Cerebral Metastases during Gamma Knife Radiosurgery. Int J Surg Oncol, 2012. 2012: p. 748284.

3. Kondziolka, D., et al., Gamma knife radiosurgery of other brain metastases. Prog Neurol Surg, 2012. 25: p. 190-200.

4. Chung, H.T. and D.G. Kim, Modern radiosurgery equipment for treating brain metastases. Prog Neurol Surg, 2012. 25: p. 236-47.

5. Yoo, T.W.P., E. S.; Kwon do, H.; Kim, C. J., Gamma knife radiosurgery for brainstem metastasis. J Korean Neurosurg Soc, 2011. 50(4): p. 299-303.

6. Yang, H.C.K., H.; Lunsford, L. D.; Niranjan, A.; Flickinger, J. C.; Kondziolka, D., What factors predict the response of larger brain metastases to radiosurgery? Neurosurgery, 2011. 68(3): p. 682-90; discussion 690.

7. Yamamoto, M., et al., Subclassification of Recursive Partitioning Analysis Class II Patients with Brain Metastases Treated Radiosurgically. International Journal of Radiation Oncology, Biology, Physics, 2011.

8. Wegner, R.E.O., A. C.; Kondziolka, D.; Niranjan, A.; Lundsford, L. D.; Flickinger, J. C., Stereotactic radiosurgery for patients with brain metastases from small cell lung cancer. International Journal of Radiation Oncology, Biology, Physics, 2011. 81(3): p. e21-7.

9. Skeie, B.S.S., G. O.; Enger, P. O.; Ganz, J. C.; Heggdal, J. I.; Ystevik, B.; Hatteland, S.; Parr, E.; Pedersen, P. H., Gamma knife surgery in brain melanomas: absence of extracranial metastases and tumor volume strongest indicators of prolonged survival. World Neurosurg, 2011. 75(5-6): p. 684-91; discussion 598-603.

10. Skeie, B.S.E., P. O.; Ganz, J. C.; Skeie, G. O.; Parr, E.; Hatteland, S.; Ystevik, B.; Heggdal, J. I.; Pedersen, P. H., Gamma Knife Surgery of Colorectal Brain Metastases: A High Prescription Dose of 25 Gy May Improve Growth Control. World Neurosurg, 2011.

11. Simonova, G.L., R., [Significance of radiosurgery in the treatment of brain metastases]. Casopis Lekaru Ceskych, 2011. 150(4-5): p. 273-7.

12. Sheehan, J.P.Y., C. P.; Nguyen, J.; Rainey, J. A.; Dassoulas, K.; Schlesinger, D. J., Timing and risk factors for new brain metastasis formation in patients initially

treated only with Gamma Knife surgery. Clinical article. Journal of Neurosurgery, 2011. 114(3): p. 763-8.

13. Rush, S.E., R. E.; Morsi, A.; Mehta, N.; Spriet, J.; Narayana, A.; Donahue, B.; Parker, E. C.; Golfinos, J. G., Incidence, timing, and treatment of new brain metastases after Gamma Knife surgery for limited brain disease: the case for reducing the use of whole-brain radiation therapy. Journal of Neurosurgery, 2011. 115(1): p. 37-48.

14. Rauch, P.J.P., H. S.; Knisely, J. P.; Chiang, V. L.; Vortmeyer, A. O., Delayed Radiation-Induced Vasculitic Leukoencephalopathy. International Journal of Radiation Oncology, Biology, Physics, 2011.

15. Park, Y.S.C., J. H.; Chang, J. W.; Park, Y. G., The efficacy of gamma knife radiosurgery for advanced gastric cancer with brain metastases. Journal of Neuro-Oncology, 2011. 103(3): p. 513-21.

16. Paek, S.H.S., Y. D.; Chung, H. T.; Kim, D. G.; Cho, Z. H., Clinical application of 7.0 T magnetic resonance images in Gamma Knife radiosurgery for a patient with brain metastases. Journal of Korean Medical Science, 2011. 26(6): p. 839-43.

17. Motta, M.D.V., A.; Attuati, L.; Picozzi, P.; Perna, L.; Franzin, A.; Bolognesi, A.; Cozzarini, C.; Calandrino, R.; Mortini, P.; di Muzio, N., Gamma knife radiosurgery for treatment of cerebral metastases from non-small-cell lung cancer. International Journal of Radiation Oncology, Biology, Physics, 2011. 81(4): p. e463-8.

18. Matsunaga, S.S., T.; Kawahara, N.; Suenaga, J.; Inomori, S.; Fujino, H., Gamma Knife surgery for brain metastases from colorectal cancer. Clinical article. Journal of Neurosurgery, 2011. 114(3): p. 782-9.

19. Ma, L.P., P.; Wang, B.; Descovich, M.; Chuang, C.; Barani, I. J.; Kunwar, S.; Shrieve, D. C.; Sahgal, A.; Larson, D. A., Apparatus dependence of normal brain tissue dose in stereotactic radiosurgery for multiple brain metastases. Journal of Neurosurgery, 2011. 114(6): p. 1580-4.

20. Lee, C.K.L., S. R.; Cho, J. M.; Yang, K. A.; Kim, S. H., Therapeutic effect of gamma knife radiosurgery for multiple brain metastases. J Korean Neurosurg Soc, 2011. 50(3): p. 179-84.

21. Jo, K.W.K., D. S.; Lim do, H.; Ahn, Y. C.; Nam, D. H.; Lee, J. I., The role of radiosurgery in patients with brain metastasis from small cell lung carcinoma. J Korean Neurosurg Soc, 2011. 50(2): p. 99-102.

22. Hayashi, M., et al., "Donut's Shape" Radiosurgical Treatment Planning for Large Cystic Metastatic Brain Tumors. Minimally Invasive Neurosurgery, 2011. 54(5-6): p. 286-9.

23. Hanssens, P.K., B.; Yeo, T. T.; Chou, N.; Beute, G., Detection of brain micrometastases by high-resolution stereotactic magnetic resonance imaging and

its impact on the timing of and risk for distant recurrences. Journal of Neurosurgery, 2011. 115(3): p. 499-504.

24. Hanssens, P., et al., Salvage treatment of distant recurrent brain metastases with Gamma Knife surgery. Acta Neurochirurgica, 2011.

25. Elliott, R.E.R., S. C.; Morsi, A.; Mehta, N.; Spriet, J.; Narayana, A.; Donahue, B.; Parker, E. C.; Golfinos, J. G., Local control of newly diagnosed and distally recurrent, low-volume brain metastases with fixed-dose (20 gy) gamma knife radiosurgery. Neurosurgery, 2011. 68(4): p. 921-31; discussion 931.

26. Elaimy, A.L.M., A. R.; Lamoreaux, W. T.; Fairbanks, R. K.; Demakas, J. J.; Cooke, B. S.; Peressini, B. J.; Holbrook, J. T.; Lee, C. M., Multimodality treatment of brain metastases: an institutional survival analysis of 275 patients. World J Surg Oncol, 2011. 9: p. 69.

27. Yokouchi, H.N., H.; Ide, Y.; Okada, K.; Yanagisawa, T.; Mukai, R.; Ota, H.; Maruyama, K.; Murata, K.; Kinuta, M.; Tamai, M.; Miyao, Y.; Mori, H., [Two cases of lung cancer patients with postoperative brain metastases obtaining long-term survival after gamma knife radiosurgery]. Gan to Kagaku Ryoho, 2010. 37(12): p. 2738-40.

28. Xu, D.L., D.; Zhang, Z.; Zhang, Y.; Li, Y.; Liu, X.; Jia, Q.; Zheng, L.; Song, G., Gamma Knife surgery in the management of orbital tumors. Journal of Neurosurgery, 2010. 113 Suppl: p. 34-8.

29. Woo, H.J.H., S. K.; Park, S. H.; Hwang, J. H.; Hamm, I. S., Factors related to the local treatment failure of gamma knife surgery for metastatic brain tumors. Acta Neurochirurgica, 2010. 152(11): p. 1909-14.

30. Tsutsumi, S.Y., Y.; Oizumi, H.; Ito, M., Chondrosarcoma with atypical clinical presentation treated by gamma knife radiosurgery for multiple brain metastases--case report. Neurologia Medico-Chirurgica, 2010. 50(6): p. 502-5.

31. Takura, T.H., M.; Muragaki, Y.; Iseki, H.; Uetsuka, Y., [Study on medical economic evaluation methods for metastatic brain tumors therapy]. No Shinkei Geka. Neurological Surgery, 2010. 38(7): p. 629-37.

32. Shuto, T.M., S.; Suenaga, J.; Inomori, S.; Fujino, H., Treatment strategy for metastatic brain tumors from renal cell carcinoma: selection of gamma knife surgery or craniotomy for control of growth and peritumoral edema. Journal of Neuro-Oncology, 2010. 98(2): p. 169-75.

33. Serizawa, T.Y., M.; Sato, Y.; Higuchi, Y.; Nagano, O.; Kawabe, T.; Matsuda, S.; Ono, J.; Saeki, N.; Hatano, M.; Hirai, T., Gamma Knife surgery as sole treatment for multiple brain metastases: 2-center retrospective review of 1508 cases meeting the inclusion criteria of the JLGK0901 multi-institutional prospective study. Journal of Neurosurgery, 2010. 113 Suppl: p. 48-52.

34. Serizawa, T.H., T.; Nagano, O.; Higuchi, Y.; Matsuda, S.; Ono, J.; Saeki, N., Gamma knife surgery for 1-10 brain metastases without prophylactic whole-brain radiation therapy: analysis of cases meeting the Japanese prospective multi-institute study (JLGK0901) inclusion criteria. Journal of Neuro-Oncology, 2010. 98(2): p. 163-7.

35. Register, S.C., J. W.; Chaudhury, A. R.; Lo, S. S., Pathologic complete response of a solitary melanoma brain metastasis after local ablative radiation therapy: case report. Med Oncol, 2010. 27(4): p. 1208-11.

36. Peev, N.A.H., Y.; Hirai, T.; Nishiyama, Y.; Nagahisa, S.; Kanno, T.; Sano, H., Delayed surgical resections of brain metastases after gamma knife radiosurgery. Neurosurgical Review, 2010. 33(3): p. 349-57; discussion 357.

37. Niranjan, A.K., H.; Khan, A.; Kim, I. Y.; Kondziolka, D.; Flickinger, J. C.; Lunsford, L. D., Radiosurgery for brain metastases from unknown primary cancers. International Journal of Radiation Oncology, Biology, Physics, 2010. 77(5): p. 1457-62.

38. Nagai, A.S., Y.; Mori, Y.; Hashizume, C.; Hagiwara, M.; Kobayashi, T., Increases in the number of brain metastases detected at frame-fixed, thin-slice MRI for gamma knife surgery planning. Neuro Oncol, 2010. 12(11): p. 1187-92.

39. Miranda, E.R.P., E. L.; Silva, B. C.; De Marco, L.; Sarquis, M. S., Papillary thyroid carcinoma with brain metastases: an unusual 10-year-survival case. Thyroid, 2010. 20(6): p. 657-61.

40. Matsunaga, S.S., T.; Kawahara, N.; Suenaga, J.; Inomori, S.; Fujino, H., Gamma Knife surgery for metastatic brain tumors from primary breast cancer: treatment indication based on number of tumors and breast cancer phenotype. Journal of Neurosurgery, 2010. 113 Suppl: p. 65-72.

41. Koga, T.S., M.; Saito, N., Role of gamma knife radiosurgery in neurosurgery: past and future perspectives. Neurologia Medico-Chirurgica, 2010. 50(9): p. 737-48.

42. Knisely, J.P.Y., M.; Gross, C. P.; Castrucci, W. A.; Jokura, H.; Chiang, V. L., Radiosurgery alone for 5 or more brain metastases: expert opinion survey. Journal of Neurosurgery, 2010. 113 Suppl: p. 84-9.

43. Kalani, M.Y.F., A. S.; Kalani, M. A.; Sanai, N.; Brachman, D.; McBride, H. L.; Shetter, A. G.; Smith, K. A., Gamma Knife surgery combined with resection for treatment of a single brain metastasis: preliminary results. Journal of Neurosurgery, 2010. 113 Suppl: p. 90-6.

44. Javalkar, V.C., R.; Ampil, F.; Ahmed, O.; Shi, R.; Nanda, A., The Louisiana State University experience in the management of single small cerebellar metastasis. Neurosurgery, 2010. 67(6): p. 1515-22.

45. Jagannathan, J.B., T. D.; Schlesinger, D.; Yen, C. P.; Shaffrey, M. E.; Laws, E. R., Jr.; Sheehan, J. P., Clinical and pathological characteristics of brain metastasis resected after failed radiosurgery. Neurosurgery, 2010. 66(1): p. 208-17.

46. Hwang, S.W.A., M. M.; Hale, A.; Eisenberg, R. L.; Dvorak, T.; Yao, K.; Pfannl, R.; Mignano, J.; Zhu, J. J.; Price, L. L.; Strauss, G. M.; Wu, J. K., Adjuvant Gamma Knife radiosurgeryfollowing surgical resection of brain metastases: a 9-year retrospective cohort study. Journal of Neuro-Oncology, 2010. 98(1): p. 77-82.

47. Huang, C.F.C., S. Y.; Wu, M. F.; Tu, H. T.; Liu, W. S.; Chuang, J. C., Apparent diffusion coefficients for evaluation of the response of brain tumors treated by Gamma Knife surgery. Journal of Neurosurgery, 2010. 113 Suppl: p. 97-104.

48. Hormozi, A.K.G., M. R.; Hosseini, S. N., Unusual presentation of peripheral primitive neuroectodermal tumor of the maxilla. Journal of Craniofacial Surgery, 2010. 21(6): p. 1761-3.

49. Frazier, J.L.B., S.; Kapor, S.; Vellimana, A.; Gandhi, R.; Carson, K. A.; Shokek, O.; Lim, M.; Kleinberg, L.; Rigamonti, D., Stereotactic radiosurgery in the management of brain metastases: an institutional retrospective analysis of survival. International Journal of Radiation Oncology, Biology, Physics, 2010. 76(5): p. 1486-92.

50. Flannery, T.K., H.; Niranjan, A.; Monaco, E. A., 3rd; Flickinger, J. C.; Kofler, J.; Lunsford, L. D.; Kondziolka, D., Gamma knife radiosurgery as a therapeutic strategy for intracranial sarcomatous metastases. International Journal of Radiation Oncology, Biology, Physics, 2010. 76(2): p. 513-9.

51. Flannery, T.K., H.; Niranjan, A.; Monaco, E. A., 3rd; Flickinger, J. C.; Lunsford, L. D.; Kondziolka, D., Stereotactic radiosurgery as a therapeutic strategy for intracranial metastatic prostate carcinoma. Journal of Neuro-Oncology, 2010. 96(3): p. 369-74.

52. Elliott, R.E.R., S.; Morsi, A.; Mehta, N.; Spriet, J.; Narayana, A.; Donahue, B.; Parker, E. C.; Golfinos, J. G., Neurological complications and symptom resolution following Gamma Knife surgery for brain metastases 2 cm or smaller in relation to eloquent cortices. Journal of Neurosurgery, 2010. 113 Suppl: p. 53-64.

53. Dillman, R.O.N., A. A.; Williams, S. T.; Kim, R. B.; Hafer, R. L.; Coleman, C. L.; Wang, P. C.; Duma, C. M.; Chen, P. V.; Selvan, S. R.; Cornforth, A. N.; DePriest, C., Durable complete response of refractory, progressing metastatic melanoma after treatment with a patient-specific vaccine. Cancer Biother Radiopharm, 2010. 25(5): p. 553-7.

54. Dea, N.B., M.; Kenny, B.; Fortin, D.; Mathieu, D., Safety and efficacy of Gamma Knifesurgery for brain metastases in eloquent locations. Journal of Neurosurgery, 2010. 113 Suppl: p. 79-83.

55. Clarke, J.W.R., S.; McGregor, J. M.; Grecula, J. C.; Mayr, N. A.; Wang, J. Z.; Li, K.; Gupta, N.; Kendra, K. L.; Olencki, T. E.; Cavaliere, R.; Sarkar, A.; Lo, S. S.,

Stereotactic radiosurgery with or without whole brain radiotherapy for patients with a single radioresistant brain metastasis. American Journal of Clinical Oncology, 2010. 33(1): p. 70-4.

56. Chiou, S.M., Validity of the graded prognostic assessment-derived index to predict brainmetastatic patients' survival after Gamma Knife radiosurgery. International Journal of Radiation Oncology, Biology, Physics, 2010. 78(4): p. 1156-62.

57. Chang, W.S.K., H. Y.; Chang, J. W.; Park, Y. G.; Chang, J. H., Analysis of radiosurgical results in patients with brain metastases according to the number of brain lesions: is stereotactic radiosurgery effective for multiple brain metastases? Journal of Neurosurgery, 2010. 113 Suppl: p. 73-8.

58. Basina, B.R.O., C.; Roy, D. K.; Yen, C. P.; Schlesinger, D.; Nagayama, K.; Sheehan, J. P., Radiation dose and incidence of new metastasis in the anterior temporal lobe structures of radiosurgically treated patients. Journal of Neurosurgery, 2010. 112(1): p. 122-9.

59. Abacioglu, U.C., H.; Atasoy, B. M.; Abdulloev, T.; Akgun, Z.; Kilic, T., Gamma knife radiosurgery in non small cell lung cancer patients with brain metastases: treatment results and prognostic factors. J BUON, 2010. 15(2): p. 274-80.

60. Yamamoto, M.B., B. E.; Urakawa, Y., Gamma knife radiosurgery for brain metastases of non-lung cancer origin: focusing on multiple brain lesions. Prog Neurol Surg, 2009. 22: p.154-69.

61. Wowra, B.M., A.; Tonn, J. C., Quality of radiosurgery for single brain metastases with respect to treatment technology: a matched-pair analysis. Journal of Neuro-Oncology, 2009. 94(1): p. 69-77.

62. Sin, A.H.C., R. J.; Vannemreddy, P.; Nanda, A., Gamma Knife stereotactic radiosurgery for intracranial metastases from conventionally radioresistant primary cancers: outcome analysis of survival and control of brain disease. Southern Medical Journal, 2009. 102(1): p. 42-4.

63. Serizawa, T., Metastatic brain tumors: lung cancer. Prog Neurol Surg, 2009. 22: p. 142- 53.

64. Regis, J.T., M.; Guillot, C.; Yomo, S.; Muraciolle, X.; Nagaje, M.; Arka, Y.; Porcheron, D., Radiosurgery with the world's first fully robotized Leksell Gamma Knife PerfeXion in clinical use: a 200-patient prospective, randomized, controlled comparison with the Gamma Knife 4C. Neurosurgery, 2009. 64(2): p. 346-55; discussion 355-6.

65. Ratner, E.S.T., E.; O'Malley, D. M.; McAlpine, J.; Rutherford, T. J.; Azodi, M.; Higgins, S. A.; Schwartz, P. E., Brain metastases in epithelial ovarian and primary peritoneal carcinoma. Int J Gynecol Cancer, 2009. 19(5): p. 856-9.

66. Park, W.H.J., I. S.; Kim, C. J.; Kwon do, H., Gamma knife radiosurgery after stereotactic aspiration for large cystic brain metastases. J Korean Neurosurg Soc, 2009. 46(4): p. 360-4.

67. Park, S.H.H., S. K.; Kang, D. H.; Lee, S. H.; Park, J.; Hwang, J. H.; Hamm, I. S.; Park, Y. M., Gamma knife radiosurgery for multiple brain metastases from lung cancer. J Clin Neurosci, 2009. 16(5): p. 626-9.

68. Niranjan, A.N., J., Jr.; Bhatnagar, J.; Flickinger, J. C.; Kondziolka, D.; Lunsford, L. D., Efficiency and dose planning comparisons between the Perfexion and 4C Leksell Gamma Knife units. Stereotactic and Functional Neurosurgery, 2009. 87(3): p. 191-8.

69. Navarro-Martin, A.M., A.; Manders, M.; Ducharme, E.; Chen, P.; Grills, I., Gamma Knife radiosurgery as a primary treatment option for solitary brain metastases from ovarian carcinoma. Clin Transl Oncol, 2009. 11(5): p. 326-8.

70. Nagano, H.N., S.; Shuto, T.; Asada, H.; Inomori, S., Dose selection for optimal treatment results and avoidance of complications. Prog Neurol Surg, 2009. 22: p. 11-9.

71. Muller-Riemenschneider, F.S., C.; Bockelbrink, A.; Ernst, I.; Vauth, C.; Willich, S. N.; von der Schulenburg, J. M., Medical and health economic assessment of radiosurgery for the treatment of brain metastasis. GMS Health Technol Assess, 2009. 5: p. Doc03.

72. Matsuda, R.M., Y.; Takeshima, Y.; Kimura, R.; Iida, J.; Nakamura, M.; Mishima, H.; Park, Y. S.; Hirabayashi, H.; Nakase, H.; Sakai, T., [A case of brain metastasis of renal pelvic carcinoma]. No Shinkei Geka. Neurological Surgery, 2009. 37(2): p. 179-82.

73. Lorenzoni, J.G.D., D.; Massager, N.; Desmedt, F.; Simon, S.; Van Houtte, P.; Brotchi, J.; Levivier, M., Brain stem metastases treated with radiosurgery: prognostic factors of survival and life expectancy estimation. Surgical Neurology, 2009. 71(2): p. 188-95; discussion 195, 195-6.

74. Krishnamurthy, S.N.-M., A.; Maitz, A., Gamma Knife radiosurgery for occipital condyle metastasis. Clin Transl Oncol, 2009. 11(9): p. 622-4.

75. Kim, I.Y.K., D.; Niranjan, A.; Flickinger, J. C.; Lunsford, L. D., Gamma knife radiosurgery for metastatic brain tumors from thyroid cancer. Journal of Neuro-Oncology, 2009. 93(3): p. 355-9.

76. Kased, N.B., D. K.; McDermott, M. W.; Nakamura, J. L.; Huang, K.; Berger, M. S.; Wara, W. M.; Sneed, P. K., Gamma Knife radiosurgery for brain metastases from primary breast cancer. International Journal of Radiation Oncology, Biology, Physics, 2009. 75(4): p. 1132-40.

77. Karlsson, B.H., P.; Wolff, R.; Soderman, M.; Lindquist, C.; Beute, G., Thirty years' experience with Gamma Knife surgery for metastases to the brain. Journal of Neurosurgery, 2009. 111(3): p. 449-57.

78. Kano, H.N., A.; Kondziolka, D.; Flickinger, J. C.; Lunsford, L. D., Stereotactic radiosurgery for pituitary metastases. Surgical Neurology, 2009. 72(3): p. 248-55; discussion 255-6.

79. Jagannathan, J.Y., C. P.; Ray, D. K.; Schlesinger, D.; Oskouian, R. J.; Pouratian, N.; Shaffrey, M. E.; Larner, J.; Sheehan, J. P., Gamma Knife radiosurgery to the surgical cavity following resection of brain metastases. Journal of Neurosurgery, 2009. 111(3): p. 431-8.

80. Ishikawa, E.Y., M.; Saito, A.; Kujiraoka, Y.; Iijima, T.; Akutsu, H.; Matsumura, A., Delayed cyst formation after gamma knife radiosurgery for brain metastases. Neurosurgery, 2009. 65(4): p. 689-94; discussion 694-5.

81. Higaki, N.S., I.; Hayashi, N.; Nakano, K.; Murakami, M.; Hayashida, H.; Kan, K.; Ichihara, T.; Aizawa, N.; Saito, N.; Niju, T.; Ikeda, T.; Sakon, M., [Advanced lung cancer with mediastinal lymph node metastasis and recurrence of brain metastasis completely responsive to combination chemotherapy and gamma knife radiosurgery--a case report]. Gan to Kagaku Ryoho, 2009. 36(12): p. 2111-3.

82. Eom, K.S.K., D. W.; Kim, T. Y., Diffuse craniospinal metastases of intraventricular rhabdoid papillary meningioma with glial fibrillary acidic protein expression: a case report. Clinical Neurology and Neurosurgery, 2009. 111(7): p. 619-23.

83. Da Silva, A.N.N., K.; Schlesinger, D.; Sheehan, J. P., Early brain tumor metastasis reduction following Gamma Knife surgery. Journal of Neurosurgery, 2009. 110(3): p. 547-52.

84. Da Silva, A.N.N., K.; Schlesinger, D. J.; Sheehan, J. P., Gamma Knife surgery for brain metastases from gastrointestinal cancer. Journal of Neurosurgery, 2009. 111(3): p. 423- 30.

85. Choi, H.J.C., B. C.; Sohn, J. H.; Shin, S. J.; Kim, S. H.; Kim, J. H.; Yoo, N. C., Brain metastases from hepatocellular carcinoma: prognostic factors and outcome: brain metastasis from HCC. Journal of Neuro-Oncology, 2009. 91(3): p. 307-13.

86. Stern, R.L.P., J. R.; Pappas, C. T.; Boggan, J. E.; Chen, A. Y., The option of Linac-based radiosurgery in a Gamma Knife radiosurgery center. Clinical Neurology and Neurosurgery, 2008. 110(10): p. 968-72.

87. Shuto, T.M., S.; Inomori, S.; Fujino, H., Efficacy of gamma knife surgery for control of peritumoral oedema associated with metastatic brain tumours. Journal of Neurology, Neurosurgery and Psychiatry, 2008. 79(9): p. 1061-5.

88. Serizawa, T.Y., M.; Nagano, O.; Higuchi, Y.; Matsuda, S.; Ono, J.; Iwadate, Y.; Saeki, N., Gamma Knife surgery for metastatic brain tumors. Journal of Neurosurgery, 2008. 109 Suppl: p. 118-21.

89. Seo, Y.S.C., T. W.; Kim, I. Y.; Bom, H. S.; Min, J. J., Enhanced detectability of recurrent brain tumor using glucose-loading F-18 FDG PET. Clinical Nuclear Medicine, 2008. 33(1): p. 32-3.

90. Sawrie, S.M.G., B. L.; Spencer, S. A.; Nordal, R. A.; Meredith, R. F.; Markert, J. M.; Cloud, G. A.; Fiveash, J. B., Predictors of distant brain recurrence for patients with newly diagnosed brain metastases treated with stereotactic radiosurgery alone. International Journal of Radiation Oncology, Biology, Physics, 2008. 70(1): p. 181-6.

91. Saito, R.K., T.; Watanabe, M.; Jokura, H.; Shibuya, M.; Nakazato, Y.; Tominaga, T., Lowgrade fibromyxoid sarcoma of intracranial origin. Journal of Neurosurgery, 2008. 108(4): p. 798-802.

92. Redmond, A.J.D., M. L.; Hebert, R.; Moliterno, J. A.; Desai, R.; Knisely, J. P.; Chiang, V. L., Gamma Knife surgery for the treatment of melanoma metastases: the effect of intratumoral hemorrhage on survival. Journal of Neurosurgery, 2008. 109 Suppl: p. 99- 105.

93. Powell, J.W.C., C. T.; Shah, H. R.; Canute, G. W.; Hodge, C. J.; Bassano, D. A.; Liu, L.; Mitchell, L.; Hahn, S. S., Gamma Knife surgery in the management of radioresistant brain metastases in high-risk patients with melanoma, renal cell carcinoma, and sarcoma. Journal of Neurosurgery, 2008. 109 Suppl: p. 122-8.

94. Pan, H.C.S., M. H.; Chen, C. C.; Chen, C. J.; Lee, C. H.; Sheehan, J., Neuroimaging and quality-of-life outcomes in patients with brain metastasis and peritumoral edema who undergo Gamma Knife surgery. Journal of Neurosurgery, 2008. 109 Suppl: p. 90-8.

95. Pan, D.H.K., Y. H.; Guo, W. Y.; Chung, W. Y.; Wu, H. M.; Liu, K. D.; Chang, Y. C.; Wang, L. W.; Wong, T. T., Gamma Knife surgery for cerebral arteriovenous malformations in children: a 13-year experience. J Neurosurg Pediatr, 2008. 1(4): p. 296-304.

96. Muacevic, A.W., B.; Siefert, A.; Tonn, J. C.; Steiger, H. J.; Kreth, F. W., Microsurgery plus whole brain irradiation versus Gamma Knife surgery alone for treatment of single metastases to the brain: a randomized controlled multicentre phase III trial. Journal of Neuro-Oncology, 2008. 87(3): p. 299-307.

97. Kased, N.H., K.; Nakamura, J. L.; Sahgal, A.; Larson, D. A.; McDermott, M. W.; Sneed, P. K., Gamma knife radiosurgery for brainstem metastases: the UCSF experience. Journal of Neuro-Oncology, 2008. 86(2): p. 195-205.

98. Iwai, Y.Y., K.; Yasui, T., Boost radiosurgery for treatment of brain metastases after surgical resections. Surgical Neurology, 2008. 69(2): p. 181-6; discussion 186.

99. Germanwala, A.V.M., J. C.; Tomycz, N. D.; Niranjan, A.; Flickinger, J. C.; Kondziolka, D.; Lunsford, L. D., Boost Gamma Knife surgery during multimodality management of adult medulloblastoma. Journal of Neurosurgery, 2008. 108(2): p. 204-9.

100. Franzin, A.V., A.; Picozzi, P.; Serra, C.; Snider, S.; Gioia, L.; Ferrari da Passano, C.; Bolognesi, A.; Giovanelli, M., Stereotactic drainage and Gamma Knife radiosurgery of cystic brain metastasis. Journal of Neurosurgery, 2008. 109(2): p. 259-67.

101. Flannery, T.W.S., M.; Regine, W. F.; Chin, L. S.; Krasna, M. J.; Shehata, M. K.; Edelman, M. J.; Kremer, M.; Patchell, R. A.; Kwok, Y., Long-term survival in patients with synchronous, solitary brain metastasis from non-small-cell lung cancer treated with radiosurgery. International Journal of Radiation Oncology, Biology, Physics, 2008. 72(1): p. 19-23.

102. Anderson, W.S.M., L. E.; Ford, E.; Rigamonti, D., Fatal case of intracerebral hemorrhage during gamma knife treatment for metastases. Clinical Neurology and Neurosurgery, 2008. 110(8): p. 838-42.

103. Yamamoto, M., Radiosurgery for metastatic brain tumors. Prog Neurol Surg, 2007. 20: p. 106-28.

104. Szeifert, G.T.K., D.; Atteberry, D. S.; Salmon, I.; Rorive, S.; Levivier, M.; Lunsford, L. D., Radiosurgical pathology of brain tumors: metastases, schwannomas, meningiomas, astrocytomas, hemangioblastomas. Prog Neurol Surg, 2007. 20: p. 91-105.

105. Mathieu, D.K., D.; Cooper, P. B.; Flickinger, J. C.; Niranjan, A.; Agarwala, S.; Kirkwood, J.; Lunsford, L. D., Gamma knife radiosurgery in the management of malignant melanoma brain metastases. Neurosurgery, 2007. 60(3): p. 471-81; discussion 481-2.

106. Kolla, S.B.H., A. K., An unusual case of transitional cell carcinoma of renal pelvis presenting with brain metastases. International Urology and Nephrology, 2007. 39(3): p. 747-50.

107. Friehs, G.M.P., M. C.; Goldman, M. A.; Zerris, V. A.; Noren, G.; Sampath, P., Stereotactic radiosurgery for functional disorders. Neurosurg Focus, 2007. 23(6): p. E3.

108. Chernov, M.H., M.; Izawa, M.; Nakaya, K.; Ono, Y.; Usukura, M.; Yoshida, S.; Kato, K.; Muragaki, Y.; Nakamura, R.; Iseki, H.; Hori, T.; Takakura, K., Metabolic characteristics of intracranial metastases, detected by single-voxel proton magnetic resonance spectroscopy, are seemingly not predictive for tumor response to gamma knife radiosurgery. Minimally Invasive Neurosurgery, 2007. 50(4): p. 233-8.

109. Brown Iii, J.V.E., H. D.; Kim, R.; Micha, J. P.; Rettenmaier, M. A.; Mattison, J. A.; Goldstein, B. H., Rapid manifestation of CNS metastatic disease in a cervical carcinoma patient: a case report. Oncology, 2007. 73(3-4): p. 273-6.

110. Bhatnagar, A.K.K., D.; Lunsford, L. D.; Flickinger, J. C., Recursive partitioning analysis of prognostic factors for patients with four or more intracranial metastases treated with radiosurgery. Technol Cancer Res Treat, 2007. 6(3): p. 153-60.

111. Ahn, J.Y.C., J. H.; Kim, S. H.; Lee, K. S., Pleomorphic adenocarcinoma of the lacrimal gland with multiple intracranial and spinal metastases. World J Surg Oncol, 2007. 5: p. 29.

112. Yoshinaga, Y.E., S.; Iwasaki, A.; Shirakusa, T., Surgical treatment for primary non-small cell lung cancer with synchronous brain metastases. Kyobu geka. The Japanese journal of thoracic surgery, 2006. 59(1): p. 41-5.

113. Yen, C.P.S., Jason; Patterson, Greg; Steiner, Ladislau, Gamma Knife surger, for metastatic brainstem tumors. Journal of neurosurgery, 2006. 105(2): p. 213-219.

114. van Eck, A.T.H., G. A., Gamma Knife surgery for multiple brain metastases from a malignant schwannoma of the penis. Journal of Neurosurgery, 2006. 105 Suppl: p. 238- 40.

115. Truong, M.T.S., Clair Eric G.; Donahue, Bernadine R.; Rush, Stephen C.; Miller, Douglas C.; Formenti, Silvia C.; Knopp, Edmond A.; Han, Kerry; Golfinos, John G., Results of surgical resection for progression of brain metastases previously treated by gamma knife radiosurgery. Neurosurgery, 2006. 59(1): p. 86-97.

116. Shuto, T.I., Shigeo; Fujino, Hideyo; Nagano, Hisato, Gamma knife surgery for metastatic brain tumors from renal cell carcinoma. Journal of neurosurgery, 2006. 105(4): p. 555- 60.

117. Perks, J.R.L., T.; Hall, W. H.; Chen, A. Y., Clinical impact of magnetic resonance imaging on Gamma Knife surgery for brain metastases. Journal of Neurosurgery, 2006. 105 Suppl: p. 69-74.

118. Nakaya, K.H., M.; Izawa, M.; Ochiai, T.; Hori, T.; Takakura, K., How soon will the patient with metastasis return for radiosurgery? Journal of Neurosurgery, 2006. 105 Suppl: p. 82-5.

119. Mori, Y.K., T.; Shibamoto, Y., Stereotactic radiosurgery for metastatic tumors in the pituitary gland and the cavernous sinus. Journal of Neurosurgery, 2006. 105 Suppl: p. 37-42.

120. Mizumatsu, S.N., Takushi; Sakai, Kyoji; Goto, Masaki; Sugatani, Hiroshi; Higashi, Toru, A case of brain metastasis from gastric cancer involving bilateral middle cerebellar peduncles. No shinkei geka. Neurological surgery, 2006. 34(9): p. 955-60.

121. Kong, D.S.L., Jung Il; Nam, Do Hyun; Park, Kwan; Kim, Jong Hyun; Kim, Jhin Gook; Park, Jun O.; Park, Keunchil, Prognosis of non-small cell lung cancer with synchronous brain metastases treated with gamma knife radiosurgery. Journal of Korean medical science, 2006. 21(3): p. 527-32.

122. Kitayama, Y.Y., Yousuke; Okamoto, Nobuhiro, A case of effective paclitaxel therapy for gastric cancer with brain metastasis. Gan to kagaku ryoho. Cancer & chemotherapy, 2006. 33(7): p. 981-4.

123. Kim, P.K.E., T. L.; Stieber, V. W.; McMullen, K. P.; Shaw, E. G.; McCoy, T. P.; D'Agostino, R. B.; Bourland, J. D.; DeGuzman, A. F.; Ekstrand, K. E.; Raber, M. R.; Tatter, S. B., Gamma Knife surgery targeting the resection cavity of brain metastasis that has progressed after whole-brain radiotherapy. Journal of Neurosurgery, 2006. 105 Suppl: p. 75-8.

124. Katsurago, N.S., Y.; Hashizume, M.; Miyasaka, Y., Long-term survival following multimodality treatment of metachronous metastases parotid gland, adrenal gland, brain and mediastinal lymph node after resection of non-small cell lung cancer; report of a case. Kyobu geka. The Japanese journal of thoracic surgery, 2006. 59(2): p. 168-71.

125. Izawa, M.C., M.; Hayashi, M.; Kubota, Y.; Kasuya, H.; Hori, T., Fatal intratumoral hemorrhage immediately after gamma knife radiosurgery for brain metastases: case report. Minimally invasive neurosurgery : MIN, 2006. 49(4): p. 251-4.

126. Goldman, M.B., J. L.; Rogg, J. M.; Noren, G., Utility of apparent diffusion coefficient in predicting the outcome of Gamma Knife-treated brain metastases prior to changes in tumor volume: a preliminary study. Journal of Neurosurgery, 2006. 105 Suppl: p. 175-82.

127. Fuentes, S.D., Christine; Metellus, Philippe; Peragut, Jean Claude; Grisoli, François; Regis, Jean, Brainstem metastases: management using gamma knife radiosurgery. Neurosurgery, 2006. 58(1): p. 37-42.

128. Douglas, J.G.G., R., A simple treatment planning strategy for patients with multiple metastases treated with Gamma Knife surgery. Journal of Neurosurgery, 2006. 105 Suppl: p. 2-4.

129. Chun, P.Y.S., J.; Patterson, G.; Steiner, L., Gamma Knife surgery for metastatic brainstem tumors. Journal of neurosurgery, 2006. 105(2): p. 213-219.

130. Christopoulou, A.R., Spyros; Kingsley, Derek; Paddick, Ian; Lindquist, Christer, Integration of gamma knife surgery in the management of cerebral metastases from melanoma. Melanoma research, 2006. 16(1): p. 51-7.

131. Chernov, M.F.H., M.; Izawa, M.; Usukura, M.; Yoshida, S.; Ono, Y.; Muragaki, Y.; Kubo, O.; Hori, T.; Takakura, K., Multivoxel proton MRS for differentiation of radiation-induced necrosis and tumor recurrence after gamma knife radiosurgery for brain metastases. Brain tumor pathology, 2006. 23(1): p. 19-27.

132. Bhatnagar, A.K.F., John C.; Kondziolka, Douglas; Lunsford, L. Dade, Stereotactic radiosurgery for four or more intracranial metastases. International Journal of Radiation Oncology Biology Physics, 2006. 64(3): p. 898-903.

133. Yu, C.P.C., Joel Y. C.; Chan, Josie F. K.; Leung, Samuel C. L.; Ho, Robert T. K., Prolonged survival in a subgroup of patients with brain metastases treated by gamma knife surgery. Journal of neurosurgery, 2005. 102: p. 262-5.

134. Varlotto, J.M.F., John C.; Niranjan, Ajay; Bhatnagar, Ajay; Kondziolka, Douglas; Lunsford, L. Dade, The impact of whole-brain radiation therapy on the long-term control and morbidity of patients surviving more than one year after gamma knife radiosurgery for brain metastases. International Journal of Radiation Oncology Biology Physics, 2005. 62(4): p. 1125-32.

135. Takada, T.Y., Yoshiteru; Uno, Masahiro; Komeda, Hisao; Fujimoto, Yoshinori, Synergetic responses after administration of interleukin-2 and interferon-alpha combined with gamma knife radiosurgery in a patient with multiple lung and brain metastases: A case report. Acta Urologica Japonica, 2005. 51(6): p. 381-384.

136. Szeifert, G.T.S., Isabelle; Rorive, Sandrine; Massager, Nicolas; Devriendt, Daniel; Simon, Stephan; Brotchi, Jacques; Levivier, Marc, Does gamma knife surgery stimulate cellular immune response to metastatic brain tumors? A histopathological and immunohistochemical study. Journal of neurosurgery, 2005. 102: p. 180-4.

137. Sheehan, J.K., Douglas; Flickinger, John; Lunsford, L. Dade, Radiosurgery for patients with recurrent small cell lung carcinoma metastatic to the brain: outcomes and prognostic factors. Journal of neurosurgery, 2005. 102: p. 247-54.

138. Serizawa, T.S., N.; Higuchi, Y.; Ono, J.; Iuchi, T.; Nagano, O.; Yamaura, A. Gamma knife surgery for brain metastases: indications for and limitations of a local treatment protocol. 2005 Date created: 2005/06/22/]; 7:[721-6].

139. Serizawa, T.S., Naokatsu; Higuchi, Yosmhinori; Ono, Junichi; Matsuda, Shinji; Sato, Makoto; Yanagisawa, Masamichi; Iuchi, Toshihiko; Nagano, Osamu; Yamaura, Akira, Diagnostic value of thallium-201 chloride single-photon emission computerized tomography in differentiating tumor recurrence from radiation injury after gamma knife surgery for metastatic brain tumors. Journal of neurosurgery, 2005. 102: p. 266-71.

140. Sadatomo, T.Y., Kiyoshi; Migita, Keisuke; Taniguchi, Eiji; Kodama, Yasunori; Kurisu, Kaoru, Solitary brain metastasis from renal cell carcinoma 15 years after nephrectomy: case report. Neurologia medico-chirurgica, 2005. 45(8): p. 423-7.

141. Pan, H.C.S., Jason; Stroila, Matei; Steiner, Melita; Steiner, Ladislau, Gamma knife surgery for brain metastases from lung cancer. Journal of neurosurgery, 2005. 102: p. 128-33.

142. Nicolato, A.R., A.; Foroni, R.; Manno, P.; Alessandrini, F.; Sava, T.; Lupidi, F.; Leone, P.; Maluta, S.; Cetto, G. L.; Gerosa, M., Gamma knife radiosurgery in brain metastases from testicular tumors. Medical oncology, 2005. 22(1): p. 45-56.

143. Narita, Y., Mangement of brain metastases based on EBM. Gan to kagaku ryoho, 2005. 32(4): p. 463-7.

144. Nam, T.K.L., Jung Il; Jung, Young Jo; Im, Yong Seok; An, Hee Ye; Nam, Do Hyun; Park, Kwan; Kim, Jong Hyun, Gamma knife surgery for brain metastases in patients harboring four or more lesions: survival and prognostic factors. Journal of neurosurgery, 2005. 102: p. 147-50.

145. Mondani, M.N., A.; Tuniz, F.; Lupidi, F.; Longhi, M.; Foroni, R.; Zanotti, B.; Gerosa, M.; Skrap, M., Combined approach to cerebral metastatic lesions: Surgery and Gamma Knife treatment. Rivista Medica, 2005. 11(1-2): p. 85-92.

146. Mindermann, T., Tumor recurrence and survival following gamma knife surgery for brain metastases. Journal of neurosurgery, 2005. 102: p. 287-8.

147. Meling, T.R.H., Eirik; Unsgård, Geirmund; Nakstad, Per Hjalmar; Wester, Knut, Brain metastases in adults. Tidsskrift for den Norske Laegeforening, 2005. 125(16): p. 2179-82.

148. Lippitz, B., Gamma Knife radiosurgery in the minimal invasive treatment of brain metastases: The state-of-the-art. Rivista Medica, 2005. 11(1-2): p. 31-37.

149. Koc, M.M., John; Grecula, John; Bauer, Constance J.; Gupta, Nilendu; Gahbauer, Reinhard A., Gamma Knife radiosurgery for intracranial metastatic melanoma: an analysis of survival and prognostic factors. Journal of neuro-oncology, 2005. 71(3): p. 307-13.

150. Higashidani, Y.T., S.; Yokoyana, Y.; Yamada, T.; Onishi, T.; Onishi, S., Small cell carcinoma of the esophagus with metastasis to the brain: A case report. Esophagus, 2005. 2(2): p. 97-102.

151. Goyal, S.P., Dheerendra; Harrell, Frank, Jr.; Matsumoto, Julie; Rich, Tyvin; Steiner, Ladislau, Gamma knife surgery for the treatment of intracranial metastases from breast cancer. Journal of neurosurgery, 2005. 103(2): p. 218-23.

152. Gerosa, M.N., Antonio; Foroni, Roberto; Tomazzoli, Laura; Bricolo, Albino, Analysis of long-term outcomes and prognostic factors in patients with non-small cell lung cancer brain metastases treated by gamma knife radiosurgery. Journal of neurosurgery, 2005. 102: p. 75-80.

153. Chernov, M.H., M.; Izawa, M.; Ochiai, T.; Usukura, M.; Abe, K.; Ono, Y.; Muragaki, Y.; Kubo, O.; Hori, T.; Takakura, K., Differentiation of the radiation-induced necrosis and tumor recurrence after gamma knife radiosurgery for brain metastases: importance of multi-voxel proton MRS. Minimally invasive neurosurgery : MIN, 2005. 48(4): p. 228-34.

154. Yoshida, S.M., K. The role of surgery in the treatment of brain metastasis: a retrospective review. 2004 Date created: 2004/07/15/ Date completed: 2005/01/05/]; 8:[767-70].

155. Yamamoto, K.O., Shirei; Inoue, Hiromi; Kudoh, Kazuya; Kita, Tsunekazu; Kikuchi, Yoshihiro, Chronic administration of single weekly paclitaxel in heavily pretreated ovarian cancer patients. Current medicinal chemistry, 2004. 11(4): p. 425-8.

156. Wowra, B.M., Alexander; Jess, Hempen Anja; Tonn, Jörg Christian, Safety and efficacy of outpatient gamma knife radiosurgery for multiple cerebral metastases. Expert review of neurotherapeutics, 2004. 4(4): p. 673-9.

157. Van, E.A.T.C.J.U., F.; Baltzer, J.; Horstmann, G. A., Gamma Knife Radiosurgery and Neurosurgical Treatment Management for Breast Cancer Patients with Brain Metastases. Geburtshilfe und Frauenheilkunde, 2004. 64(1): p. 63-69.

158. Stone, A.C., Jay; Koenig, Karen L.; Golfinos, John G.; Oratz, Ruth, A comparison of survival rates for treatment of melanoma metastatic to the brain. Cancer investigation, 2004. 22(4): p. 492-7.

159. Shuto, T.F., H.; Inomori, S.; Nagano, H. Repeated gamma knife radiosurgery for multiple metastatic brain tumours. 2004 Date created: 2004/09/01/ Date completed: 2004/12/22/]; 9:[989-93].

160. Radbill, A.E.F., John F.; Falkenberg, Elizabeth T.; Guthrie, Barton L.; Young, Paul E.; Meleth, Sreelatha; Markert, James M., Initial treatment of melanoma brain metastases using gamma knife radiosurgery. Cancer, 2004. 101(4): p. 825-833.

161. Lorenzoni, J.D., Daniel; Massager, Nicolas; David, Phillippe; Ruíz, Salvador; Vanderlinden, Bruno; Van, Houtte Paul; Brotchi, Jacques; Levivier, Marc, Radiosurgery for treatment of brain metastases: estimation of patient eligibility using three stratification systems. International Journal of Radiation Oncology Biology Physics, 2004. 60(1): p. 218-24.

162. Lippitz, B.E.K., T.; Hautanen, K.; Ritzling, M.; Rähn, T.; Ulfarsson, E.; Boethius, J., Gamma knife radiosurgery for patients with multiple cerebral metastases. Acta neurochirurgica. Supplement, 2004. 91: p. 79-87.

163. Lippitz, B., Gamma knife surgery improves the treatment of intracranial tumors. Läkartidningen, 2004. 101(40): p. 3078-80.

164. Jawahar, A.M., Ronnie E.; Minagar, Alireza; Shukla, Deepti; Zhang, John H.; Willis, Brian K.; Ampil, Federico; Nanda, Anil, Gamma knife surgery in the management of brain metastases from lung carcinoma: a retrospective analysis of survival, local tumor control, and freedom from new brain metastasis. Journal of neurosurgery, 2004. 100(5): p. 842-7.

165. Jawahar, A.A., Federico; Wielbaecher, Christina; Hartman, Golda H.; Zhang, John H.; Nanda, Anil, Management strategies for patients with brain metastases: has radiosurgery made a difference? Southern medical journal, 2004. 97(3): p. 254-8.

166. Jagannathan, J.P., Joshua H.; Balsara, Karl; Hudes, Richard; Chin, Lawrence S., Long-term survival after gamma knife radiosurgery for primary and metastatic brain tumors. American journal of clinical oncology, 2004. 27(5): p. 441-4.

167. Iwai, Y.Y., K.; Honda, Y.; Matsusaka, Y., Radiosurgery for Pituitary Metastases. Neurologia medico-chirurgica, 2004. 44(3): p. 112-116.

168. Datta, R.J., Ajay; Ampil, Federico L.; Shi, Runhua; Nanda, Anil; D'Agostino, Horacio, Survival in relation to radiotherapeutic modality for brain metastasis: whole brain irradiation vs gamma knife radiosurgery. American journal of clinical oncology, 2004. 27(4): p. 420-4.

169. Chernov, M.F.H., Motohiro; Izawa, Masahiro; Abe, Kayoko; Usukura, Masao; Ono, Yuko; Kubo, Osami; Hori, Tomokatsu, Early metabolic changes in metastatic brain tumors after Gamma Knife radiosurgery: 1H-MRS study. Brain tumor pathology, 2004. 21(2): p. 63-7.

170. Varlotto, J.M.F., John C.; Niranjan, Ajay; Bhatnagar, Ajay K.; Kondziolka, Douglas; Lunsford, L. Dale, Analysis of tumor control and toxicity in patients who have survived at least one year after radiosurgery for brain metastases. International Journal of Radiation Oncology Biology Physics, 2003. 57(2): p. 452-64.

171. Shuto, T.F., H.; Asada, H.; Inomori, S.; Nagano, H., Gamma knife radiosurgery for metastatic tumours in the brain stem. Acta Neurochirurgica, 2003. 145(9): p. 755-60.

172. Sheehan, J.P.S., Ming Hsi; Kondziolka, Douglas; Flickinger, John; Lunsford, L. Dade, Radiosurgery in patients with renal cell carcinoma metastasis to the brain: long-term outcomes and prognostic factors influencing survival and local tumor control. Journal of neurosurgery, 2003. 98(2): p. 342-9.

173. Serizawa, T.O., J.; Iuchi, T.; Matsuda, S.; Sato, M.; Odaki, M.; Hirai, S.; Osato, K.; Saeki, N.; Yamaura, A., Gamma knife radiosurgery for metastatic brain tumors from lung cancer. Japanese Journal of Neurosurgery, 2003. 12(1): p. 3-9.

174. McWilliams, R.R.G., Caterina; Hay, Ian D.; Atkinson, John L.; Stafford, Scott L.; Buckner, Jan C., Management of brain metastases from thyroid carcinoma: a study of 16 pathologically confirmed cases over 25 years. Cancer, 2003. 98(2): p. 356-62.

175. Kaido, T.U., Hirotsugu; Hirao, Yoshihiko; Uranishi, Ryunosuke; Nishi, Noriyuki; Sakaki, Toshisuke, Brain metastases from urachal carcinoma. Journal of clinical neuroscience, 2003. 10(6): p. 703-5.

176. Flannery, T.W.S., Mohan; Kwok, Young; Koffman, Bradley H.; Amin, Pradip P.; Chin, Lawrence S.; Nicol, Bradley; Fowler, Zack; Young, A. Byron; Regine, William F., Gamma knife stereotactic radiosurgery for synchronous versus metachronous solitary brain metastases from non-small cell lung cancer. Lung cancer, 2003. 42(3): p. 327-33.

177. Belohlávek, O.S., Gabriela; Kantorová, Iva; Novotn³, Josef, Jr.; Liscák, Roman. Brain metastases after stereotactic radiosurgery using the Leksell gamma knife: can FDG PET help to differentiate radionecrosis from tumour progression? 2003 Date created: 2002/12/16/ Date completed: 2003/08/01/ Date revised: 2004/11/17/]; 1:[96-100].

178. Yu, C.C., Joseph C. T.; Apuzzo, Michael L. J.; O'Day, Steven; Giannotta, Steven L.; Weber, Jeffrey S.; Petrovich, Zbigniew, Metastatic melanoma to the brain: prognostic factors after gamma knife radiosurgery. International Journal of Radiation Oncology Biology Physics, 2002. 52(5): p. 1277-87.

179. Yamamoto, M.I., Mitsunobu; Nishio, Shin ichi; Urakawa, Yoichi, Gamma Knife radiosurgery for numerous brain metastases: is this a safe treatment? International Journal of Radiation Oncology Biology Physics, 2002. 53(5): p. 1279-83.

180. Wowra, B.S., Michael; Muacevic, Alexander; Kreth, Friedrich Wilhelm; Mack, Andreas; Hofstetter, Alfons, Repeated gamma knife surgery for multiple brain metastases from renal cell carcinoma. Journal of neurosurgery, 2002. 97(4): p. 785-93.

181. Vesagas, T.S.A., Jose A.; Mercado, Eduardo R.; Mariano, Manuel M., Gamma knife radiosurgery and brain metastases: local control, survival, and quality of life. Journal of neurosurgery, 2002. 97(5Suppl): p. 507-10.

182. Takami, T.O., Kenji; Tsuyuguchi, Naohiro; Mao, Ying; Inoue, Yuichi; Wakasa, Kenichi; Hara, Mitsuhiro, Cavernous sinus metastasis from thyroid papillary adenocarcinoma. Journal of clinical neuroscience, 2002. 9(5): p. 598-600.

183. Siebels, M.O., R.; Buchner, A.; Zaak, D.; Mack, A.; Petrides, P. E.; Hofstetter, A.; Wowra, B., (Outpatient radiosurgery in 58 patients with intracerebral metastases from renal cell carcinoma: 5-Year results.). Urologe A, 2002. 41(5): p. 482-488.

184. Sheehan, J.P.S., Ming Hsi; Kondziolka, Douglas; Flickinger, John; Lunsford, L. Dade, Radiosurgery for non-small cell lung carcinoma metastatic to the brain: long-term outcomes and prognostic factors influencing patient survival time and local tumor control. Journal of neurosurgery, 2002. 97(6): p. 1276-81.

185. Serizawa, T.O., Junichi; Iichi, Toshihiko; Matsuda, Shinji; Sato, Makoto; Odaki, Masaru; Hirai, Shinji; Osato, Katsunobu; Saeki, Naokatsu; Yamaura, Akira, Gamma knife radiosurgery for metastatic brain tumors from lung cancer: a comparison between small cell and non-small cell carcinoma. Journal of neurosurgery, 2002. 97(5Suppl): p. 484-8.

186. Regine, W.F., The radiation oncologist's perspective on stereotactic radiosurgery. Technology in cancer research & treatment, 2002. 1(1): p. 43-9.

187. Petrovich, Z.Y., Cheng; Giannotta, Steven L.; O'Day, Steven; Apuzzo, Michael L. J., Survival and pattern of failure in brain metastasis treated with stereotactic gamma knife radiosurgery. Journal of neurosurgery, 2002. 97(5Suppl): p. 499-506.

188. Mahajan, A.B., Jonathan; Tsai, Jen San, Carcinomatous meningitis: are surgeryand gamma knife radiosurgery treatment risk factors? Journal of neurosurgery, 2002. 97(5Suppl): p. 441-4.

189. Levin, K.J.Y., Emad F.; Sloan, Andrew E.; Patel, Rajiv; Zabad, Rana K.; Zamorano, Lucia,Gamma knife radiosurgery in patients with advanced breast cancer undergoing bone marrow transplant. Journal of neurosurgery, 2002. 97(5Suppl): p. 663-5.

190. Jawahar, A.W., Brian K.; Smith, Donald R.; Ampil, Federico; Datta, Ratna; Nanda, Anil,Gamma knife radiosurgery for brain metastases: do patients benefit from adjuvant external-beam radiotherapy? An 18-month comparative analysis. Stereotactic and functional neurosurgery, 2002. 79(3-4): p. 262-71.

191. Hernandez, L.Z., Lucia; Sloan, Andrew; Fontanesi, James; Lo, Simon; Levin, Kenneth; Li, Qinghang; Diaz, Fernando, Gamma knife radiosurgery for renal cell carcinoma brain metastases. Journal of neurosurgery, 2002. 97(5Suppl): p. 489-93.

192. Habermann, W.Z., U.; Groell, R.; Wolf, G.; Stammberger, H.; Sutter, B.; Pendl, G., Combination of surgery and gamma knife radiosurgery--a therapeutic option for patients with tumors of nasal cavity or paranasal sinuses infiltrating the skull base. Acta otorhinolaryngologica Italica, 2002. 22(2): p. 74-9.

193. Gerosa, M.N., Antonio; Foroni, Roberto; Zanotti, Bruno; Tomazzoli, Laura; Miscusi, Massimo; Alessandrini, Franco; Bricolo, Albino, Gamma knife radiosurgery for brain metastases: a primary therapeutic option. Journal of neurosurgery, 2002. 97(5Suppl): p. 515-24.

194. DiBiase, S.J.C., Lawrence S.; Ma, Lijun, Influence of gamma knife radiosurgery on the quality of life in patients with brain metastases. American journal of clinical oncology, 2002. 25(2): p. 131-4.

195. Bhatnagar, A.H., Dwight E.; Kondziolka, Douglas; Lunsford, L. Dade; Flickinger, John C., Analysis of repeat stereotactic radiosurgery for progressive primary and metastatic CNS tumors. International Journal of Radiation Oncology Biology Physics, 2002. 53(3): p. 527- 32.

196. Amendola, B.E.W., Aizik; Coy, Sammier; Amendola, Marco A., Radiosurgery as palliation for brain metastases: a retrospective review of 72 patients harboring multiple lesions at presentation. Journal of neurosurgery, 2002. 97(5Suppl): p. 511-4.

197. Yamanaka, K.I., Y.; Nakajima, H.; Yasui, T.; Komiyama, M.; Nishikawa, M.; Morikawa, T.; Kishi, H.; Negoro, S.; Tada, H.; Tanaka, M., Treatment for brain metastasis from lung cancer in the era of radiosurgery. No shinkei geka, 2001. 29(7): p. 617-23.

198. Siegfried, J.W., G.; Scheib, S.; Haller, D.; Landolt, A. M.; Lomax, N. J.; Mindermann, T.; Schubiger, O.; Wichmann, W., Palliative treatment of brain metastases with gamma knife. Therapeutische Umschau. Revue thérapeutique, 2001. 58(7): p. 413-8.

199. Serizawa, T.O., J.; Odaki, M.; Hirai, S.; Sato, M.; Matsuda, S.; Yanagisawa, M.; Maru, S.; Iwase, T.; Sato, M., Differentiation between tumor recurrence and radiation injury after gamma knife radiosurgery for metastatic brain tumors: Value of serial thallium-201 chloride SPECT. Japanese Journal of Neurosurgery, 2001. 10(11): p. 726-732.

200. Serizawa, T.I., T.; Oho, J.; Osato, K., Gamma knife radiosurgery for multiple brain metastases from non-small cell lung cancer - Comparison with whole brain radiation therapy. Japanese Journal of Lung Cancer, 2001. 41(2): p. 123-129.

201. Park, Y.G.C., J. Y.; Chang, J. W.; Chung, S. S., Gamma knife radiosurgery for metastatic brain tumors. Stereotactic and functional neurosurgery, 2001. 76(3-4): p. 201-3.

202. Neves, S.M., P. R.; Wanschitz, J.; Rudnay, A. C.; Drlicek, M.; Czech, T.; Wüstinger, C.; Budka, H., Pseudogliomatous growth pattern of anaplastic small cell carcinomas metastatic to the brain. Clinical neuropathology, 2001. 20(1): p. 38-42.

203. Minami, H.K., K.; Watanabe, Y.; Sakakura, T.; Ito, T.; Kawamura, M.; Nakatani, T.; Kishimoto, T., Complete remission of brain metastases from prostate cancer by gamma knife radiosurgery: a case report. Hinyokika kiyo, 2001. 47(5): p. 333-6.

204. Huang, M.C.L., L. S.; Ho, D. M.; Cheng, H.; Chung, W. Y.; Huang, C. I.; Hsiao, C. Y.; Pan, D. H., A metastatic pituitary carcinoid tumor successfully treated with gamma knife radiosurgery. Zhonghua yi xue za zhi, 2001. 64(7): p. 414-8.

205. Boran, B.O.K., T.; Peker, S.; Sengöz, M.; Erdivanli, B.; Pamir, N., Gamma knife radiosurgery in the management of brain metastases. Turkish Neurosurgery, 2001. 11(1- 2): p. 9-17.

206. Terahara, A.M., T.; Kubo, T.; Aoki, Y.; Ohtomo, K., Analysis of dose distribution in gamma knife radiosurgery for multiple targets. International Journal of Radiation Oncology Biology Physics, 2000. 47(5): p. 1431-4.

207. Suzuki, S.O., J.; Nishio, S.; Nishiye, E.; Fukui, M., Gamma knife radiosurgery for simultaneous multiple metastatic brain tumors. Journal of neurosurgery, 2000. 93(Suppl 3): p. 30-1.

208. Simonová, G.L., R.; Novotn³, J., Jr.; Novotn³, J., Solitary brain metastases treated with theLeksell gamma knife: prognostic factors for patients. Radiotherapy and oncology, 2000. 57(2): p. 207-13.

209. Serizawa, T.I., T.; Ono, J.; Matsuda, S.; Osato, K.; Ushikubo, O.; Odaki, M., How effective is the gamma knife treatment for multiple metastatic brain tumors? Analysis of cases with non-small cell carcinoma. Japanese Journal of Neurosurgery, 2000. 9(11): p. 725- 730.

210. Serizawa, T.I., T.; Ono, J.; Saeki, N.; Osato, K.; Odaki, M.; Ushikubo, O.; Hirai, S.; Sato, M.; Matsuda, S., Gamma knife treatment for multiple metastatic brain tumors compared with whole-brain radiation therapy. Journal of neurosurgery, 2000. 93(Suppl 3): p. 32-6.

211. Sansur, C.A.C., L. S.; Ames, J. W.; Banegura, A. T.; Aggarwal, S.; Ballesteros, M.; Amin, P.; Simard, J. M.; Eisenberg, H., Gamma knife radiosurgery for the treatment of brain metastases. Stereotactic and functional neurosurgery, 2000. 74(1): p. 37-51.

212. Nakagawa, K.T., M.; Terahara, A.; Aoki, Y.; Sasaki, T.; Kurita, H.; Shin, M.; Kawamoto, S.; Kirino, T.; Otomo, K., A single institutional outcome analysis of Gamma Knife radiosurgery for single or multiple brain metastases. Clinical neurology and neurosurgery, 2000. 102(4): p. 227-232.

213. Kim, D.G.C., H. T.; Gwak, H. S.; Paek, S. H.; Jung, H. W.; Han, D. H., Gamma knife radiosurgery for brain metastases: prognostic factors for survival and local control. Journal of neurosurgery, 2000. 93(Suppl 3): p. 23-9.

214. Gursky, J.T.R., T. A.; Black, J. L., ECT administration in a patient after craniotomy and gamma knife surgery: a case report and review. The journal of ECT, 2000. 16(3): p. 295- 9.

215. Fujita, A.F., S.; Takabatake, H.; Tagaki, S.; Sekine, K., Combination chemotherapy of cisplatin, ifosfamide, and irinotecan with rhG-CSF support in patients with brain metastases from non-small cell lung cancer. Oncology, 2000. 59(4): p. 291-5.

216. Firlik, K.S.K., D.; Flickinger, J. C.; Lunsford, L. D., Stereotactic radiosurgery for brain metastases from breast cancer. Annals of surgical oncology, 2000. 7(5): p. 333-8.

217. Chen, J.C.P., Z.; O'Day, S.; Morton, D.; Essner, R.; Giannotta, S. L.; Yu, C.; Apuzzo, M. L., Stereotactic radiosurgery in the treatment of metastatic disease to the brain. Neurosurgery, 2000. 47(2): p. 268-79.

218. Cha, S.T.J., R.; Mathiesen, R. A.; Suh, R.; Shahinian, H. K., Cerebellopontine angle metastasis from papillary carcinoma of the thyroid: case report and literature review. Surgical Neurology, 2000. 54(4): p. 320-6.

219. Amendola, B.E.W., A. L.; Coy, S. R.; Amendola, M.; Bloch, L., Brain metastases in renal cell carcinoma: management with gamma knife radiosurgery. The cancer journal, 2000. 6(6): p. 372-6.

220. Amendola, B.E.W., A. L.; Coy, S. R.; Amendola, M.; Bloch, L., Gamma knife radiosurgery in the treatment of patients with single and multiple brain metastases from carcinoma of the breast. The cancer journal, 2000. 6(2): p. 88-92.

221. Yamanaka, K.I., Y.; Yasui, T.; Nakajima, H.; Komiyama, M.; Nishikawa, M.; Morikawa, T.; Kishi, H., Gamma Knife radiosurgery for metastatic brain tumor: the usefulness of repeated Gamma Knife radiosurgery for recurrent cases. Stereotactic and functional neurosurgery, 1999. 72(Suppl 1): p. 73-80.

222. Yamanaka, K., Prognostic factors for brain metastasis from lung cancer after gamma knife radiosurgery. Osaka city medical journal, 1999. 45(1): p. 45-59.

223. Schoeggl, A.K., K.; Ertl, A.; Reddy, M.; Bavinzski, G.; Schneider, B., Prognostic factor analysis for multiple brain metastases after gamma knife radiosurgery: results in 97 patients. Journal of neuro-oncology, 1999. 42(2): p. 169-75.

224. Sansur, A., ; Banequra,; Aggarwal,; Ballesteros,; Amin,; Chin,, Gamma Knife Radiosurgery for Treatment of Brain Metastases (Meeting abstract). Departments of Radiation Oncology and Neurological Surgery, University of Maryland School of Medicine, Baltimore, MD. English. NOTNLM. 19991001., 1999.

225. Peterson, A.M.M., C. C.; Evanson, E. J.; Flickinger, J. C.; Kondziolka, D., MR imaging response of brain metastases after gamma knife stereotactic radiosurgery. Radiology, 1999. 211(3): p. 807-14.

226. Muacevic, A.K., F. W.; Horstmann, G. A.; Schmid, Elsaesser R.; Wowra, B.; Steiger, H. J.; Reulen, H. J., Surgery and radiotherapy compared with gamma knife radiosurgery in the treatment of solitary cerebral metastases of small diameter. Journal of neurosurgery, 1999. 91(1): p. 35-43.

227. Lavine, S.D.P., Z.; Cohen, Gadol A. A.; Masri, L. S.; Morton, D. L.; O'Day, S. J.; Essner, R.; Zelman, V.; Yu, C.; Luxton, G.; Apuzzo, M. L., Gamma knife radiosurgery for metastatic melanoma: an analysis of survival, outcome, and complications. Neurosurgery, 1999. 44(1): p. 59-64.

228. Kubota, Y.T., H.; Sato, N.; Naito, H.; Uehara, T., Complete remission of brain metastasis from transitional cell carcinoma of the bladder by M-VAC chemotherapy and gamma knife radiosurgery: A case report. Japanese Journal of Clinical Urology, 1999. 53(3): p. 251-253.

229. Iwai, Y.Y., K., Gamma Knife radiosurgery for skull base metastasis and invasion. Stereotactic and functional neurosurgery, 1999. 72(SUPPL. 1): p. 81-87.

230. Young, R.F., The role of the gamma knife in the treatment of malignant primary and metastatic brain tumors. CA: a cancer journal for clinicians, 1998. 48(3): p. 177-88.

231. Yang, C.C.J.T., J.; Wu, X.; Markoe, A., Dose volume histogram analysis of the gamma knife radiosurgery treating twenty-five metastatic intracranial tumors. Stereotactic and functional neurosurgery, 1998. 70(SUPPL. 1): p. 41-49.

232. Seung, S.K.S., P. K.; McDermott, M. W.; Shu, H. K.; Leong, S. P.; Chang, S.; Petti, P. L.; Smith, V.; Verhey, L. J.; Wara, W. M.; Phillips, T. L.; Larson, D. A., Gamma knife radiosurgery for malignant melanoma brain metastases. The cancer journal from Scientific American, 1998. 4(2): p. 103-9.

233. Schoeggl, A.K., K.; Ertl, A.; Dieckmann, K.; Saringer, W.; Koos, W. T., Gamma-knife radiosurgery for brain metastases of renal cell carcinoma: Results in 23 patients. Acta Neurochirurgica, 1998. 140(6): p. 549-555.

234. Pan, H.C.C., W. Y.; Guo, W. Y.; Chang, Y. C.; Shiau, C. Y.; Wang, L. W.; Liu, R. S.; Ngo, F. Q.; Lee, L. S., Effects of gamma knife radiosurgery for brain tumors: clinical evaluation. Zhonghua yi xue za zhi, 1998. 61(7): p. 397-407.

235. Nicolato, A.F., P.; Foroni, R.; Zanotti, B.; Piovan, E.; Alfieri, A.; Gerosa, M., Minimally invasive neurosurgery. Part II: Stereotactic gamma knife radiosurgery in solitary/single intracranial metastasis. Rivista Medica, 1998. 4(3): p. 121-133.

236. Linzer, D.L., S. M.; Villalobos, H.; Raub, W., Jr.; Wu, X.; Ting, J.; Berti, A.; Landy, H.; Markoe, A. M., Gamma knife radiosurgery for large volume brain tumors: An analysis of acute and chronic toxicity. Stereotactic and functional neurosurgery, 1998. 70(SUPPL. 1): p. 11-18.

237. Tago, M.A., Y.; Nakagawa, K.; Terahara, A.; Onogi, Y.; Hasezawa, K.; Toyoda, K.; Sasaki, Y.; Kurita, H.; Murayama, S., Gamma knife radiosurgery for metastatic brain tumors: neuropathological report of two autopsy cases and review of literatures. Nippon Igaku Hoshasen Gakkai zasshi, 1997. 57(3): p. 119-26.

238. Park, Y.G.K., E. Y.; Chang, J. W.; Chung, S. S., Volume changes following gamma knife radiosurgery of intracranial tumors. Surgical Neurology, 1997. 48(5): p. 488-93.

239. Ma, Z.H., Y.; Liu, Y., Gamma knife treatment of brain metastatic tumors. Hunan yi ke da xue xue bao, 1997. 22(1): p. 63-5.

240. Liscak, R.S., G.; Vladyka, V.; Novotny, J., Jr., Radiosurgery for brain metastases of breast carcinoma. Prakticky Lekar, 1997. 77(9): p. 447-450.

241. Karlsson, B.E., K.; Kihlström, L.; Grane, P., Tumor seeding following stereotactic biopsy of brain metastases Report of two cases. Journal of neurosurgery, 1997. 87(2): p. 327-30.

242. Gerosa, M.N., A.; Severi, F.; Ferraresi, P.; Masotto, B.; Barone, G.; Foroni, R.; Piovan, E.; Pasoli, A.; Bricolo, A., Gamma knife radiosurgery for intracranial metastases: From tumor control to increased survival. Stereotactic and functional neurosurgery, 1997. 66(SUPPL. 1): p. 184-192.

243. Baardsen, R.L., John Ludvig; Wester, Knut; Pedersen, Paal Henning, Gamma knife radiosurgery of intracranial metastases. Tidsskrift for den Norske Laegeforening, 1997. 117(11): p. 1591-1595.

244. Yoshino, E.O., Y.; Imahori, Y.; Higuchi, T.; Furuya, S.; Naruse, S.; Mori, T.; Suzuki, K.; Yamaki, T.; Ueda, S.; Tsuzuki, T.; Takai, S., Irradiation effects on the metabolism of metastatic brain tumors: analysis by positron emission tomography and 1H-magnetic resonance spectroscopy. Stereotactic and functional neurosurgery, 1996. 66(Suppl 1): p. 240-59.

245. Tanaka, T.K., T.; Kida, Y.; Oyama, H.; Niwa, M., The results of gamma knife radiosurgery for malignant skull base tumors. No shinkei geka, 1996. 24(3): p. 235-9.

246. Tago, M.A., Y.; Terahara, A.; Nakagawa, K.; Sasaki, Y.; Kurita, H.; Kawamoto, S.; Murayama, S., Gamma Knife radiosurgery for brain stem metastases: two autopsy cases. Stereotactic and functional neurosurgery, 1996. 66(Suppl 1): p. 225-30.

247. Gerosa, M.N., A.; Severi, F.; Ferraresi, P.; Masotto, B.; Barone, G.; Foroni, R.; Piovan, E.; Pasoli, A.; Bricolo, A., Gamma Knife radiosurgery for intracranial metastases: from local tumor control to increased survival. Stereotactic and functional neurosurgery, 1996. 66(Suppl 1): p. 184-92.

248. Fukuoka, S.S., Y.; Takanashi, M.; Takahashi, S.; Suematsu, K.; Nakamura, J., Radiosurgery of brain metastases with the Gamma Knife. Stereotactic and functional neurosurgery, 1996. 66(Suppl 1): p. 193-200.

249. Whang, C.J.K., Y., Gamma knife radiosurgery for malignant tumors. Journal of Korean medical science, 1995. 10(5): p. 379-87.

250. Simonová, G.N., J.; Novotn³, J., Jr.; Vladyka, V.; Liscák, R., Fractionated stereotaxic radiotherapy with the Leksell gamma knife. Casopís lékaru ceskych, 1995. 134(17): p. 547-54.

251. Morikawa, T.T., K.; Fujino, H.; Fukumura, M.; Kimura, M.; Furuie, H.; Nagano, N.; Kakuta, Y.; Tashiro, Y., Stereotactic radiosurgery with the gamma knife for brain metastases in patients with lung cancer. Nihon Kyobu Shikkan Gakkai zasshi, 1995. 33(1): p. 44-50.

252. Gerosa, M.A.N., A.; Berlucchi, S.; Piovan, E.; Zampieri, P. G.; Pasoli, A.; Foroni, R.; Giri, M. G.; Marchini, G.; Babighian, S.; et al.,, Gamma Knife radiosurgery of primary and metastatic malignant brain tumors, a preliminary report. Stereotactic and functional neurosurgery, 1995. 64(Suppl 1): p. 56-66.

253. Rand, J., ; Copcutt,; Melbye,; Levenick,, Metastatic neoplasms of the brain treated by the Leksell Gamma Knife (Meeting abstract). Neurosciences Inst., Hosp. of the Good Samaritan, Los Angeles, CA. English. NOTNLM. 19940201., 1994.

254. Mogard, J.K., L.; Ericson, K.; Karlsson, B.; Guo, W. Y.; Stone, Elander S., Recurrent tumor vs radiation effects after gamma knife radiosurgery of intracerebral metastases: diagnosis with PET-FDG. Journal of computer assisted tomography, 1994. 18(2): p. 177- 81.

255. Karlsson, B.K., L.; Lindquist, C., Medical controversy: Is Gamma Knife surgery the treatment of choice for cerebral metastases? FORUM - Trends in Experimental and Clinical Medicine, 1994. 4(4): p. 396-402.

256. Jokura, H.T., K.; Kayama, T.; Yoshimoto, T., Gamma knife radiosurgery of a series of only minimally selected metastatic brain tumours. Acta neurochirurgica. Supplement, 1994. 62: p. 77-82.

257. Flickinger, J.C.K., D.; Lunsford, L. D.; Coffey, R. J.; Goodman, M. L.; Shaw, E. G.; Hudgins, W. R.; Weiner, R.; Harsh, G. R. th; Sneed, P. K.; et al.,, A multi-institutional experience with stereotactic radiosurgery for solitary brain metastasis. International Journal of Radiation Oncology Biology Physics, 1994. 28(4): p. 797-802.

258. Berk, H.W.L., J. M.; Spaulding, C.; Agarwal, S. K.; Scott, M. R.; Steiner, L., Extracranial absorbed doses with Gamma Knife radiosurgery. Stereotactic and functional neurosurgery, 1993. 61(Suppl 1): p. 164-72.

259. Kihlström, L.K., B.; Lindquist, C.; Norén, G.; Rähn, T., Gamma knife surgery for cerebral metastasis. Acta neurochirurgica. Supplementum, 1991. 52: p. 87-9.

260. Lindquist, C., Gamma knife surgery for recurrent solitary metastasis of a cerebral hypernephroma: case report. Neurosurgery, 1989. 25(5): p. 802-4.

ELEKTA

Addendum A – ASTRO Brain Mets Guidelines

See separate attachment.

ARTICLE IN PRESS

Practical Radiation Oncology (2013) xx, xxx–xxx

pro

www.practicalradonc.org

Special Article

Radiotherapeutic and surgical management for newly diagnosed brain metastasis(es): An American Society for Radiation Oncology evidence-based guideline

May N. Tsao MD[a,*], Dirk Rades MD[b], Andrew Wirth MD[c], Simon S. Lo MD[d], Brita L. Danielson MD[e], Laurie E. Gaspar MD, MBA[f], Paul W. Sperduto MD, MPP[g], Michael A. Vogelbaum MD, PhD[h], Jeffrey D. Radawski MD[i], Jian Z. Wang PhD[n], Michael T. Gillin PhD[j], Najeeb Mohideen MD[k], Carol A. Hahn MD[l], Eric L. Chang MD[m]

[a]*Department of Radiation Oncology, University of Toronto, Odette Cancer Centre, Toronto, Ontario, Canada*
[b]*Department of Radiation Oncology, University Hospital Schleswig-Holstein, Luebeck, Germany (ESTRO representative)*
[c]*Peter MacCallum Cancer Center, Trans Tasman Radiation Oncology Group (TROG), East Melbourne, Australia*
[d]*Department of Radiation Oncology, Case Western Reserve University, University Hospitals Case Medical Center, Cleveland, Ohio*
[e]*Department of Radiation Oncology, Cross Cancer Institute, University of Alberta, Edmonton, Canada (CARO representative)*
[f]*Department of Radiation Oncology, University of Colorado, Aurora, Colorado*
[g]*University of Minnesota Gamma Knife Center and Minneapolis Radiation Oncology, Minneapolis, Minnesota*
[h]*Department of Neurological Surgery, Cleveland Clinic, Cleveland, Ohio*
[i]*Department of Radiation Oncology, Ohio State University, Columbus, Ohio*
[j]*Department of Radiation Oncology, M.D. Anderson Cancer Center, Houston, Texas*
[k]*Department of Radiation Oncology, Northwest Community Hospital, Arlington Heights, Illinois*
[l]*Department of Radiation Oncology, Duke University Medical School, Durham, North Carolina*
[m]*Department of Radiation Oncology, University of Southern California Keck School of Medicine, Los Angeles, California*
[n]*Department of Radiation Oncology, Ohio State University, Columbus, Ohio (deceased)*

Received 27 October 2011; revised 9 December 2011; accepted 15 December 2011

ELEKTA

Addendum B – Neuro Guidelines

See separate attachment.

J Neurooncol (2010) 96:45–68
DOI 10.1007/s11060-009-0073-4

INVITED MANUSCRIPT

The role of stereotactic radiosurgery in the management of patients with newly diagnosed brain metastases: a systematic review and evidence-based clinical practice guideline

Mark E. Linskey · David W. Andrews · Anthony L. Asher · Stuart H. Burri · Douglas Kondziolka · Paula D. Robinson · Mario Ammirati · Charles S. Cobbs · Laurie E. Gaspar · Jay S. Loeffler · Michael McDermott · Minesh P. Mehta · Tom Mikkelsen · Jeffrey J. Olson · Nina A. Paleologos · Roy A. Patchell · Timothy C. Ryken · Steven N. Kalkanis

Received: 7 September 2009 / Accepted: 8 November 2009 / Published online: 4 December 2009
© The Author(s) 2009. This article is published with open access at Springerlink.com

Abstract

Question

Should patients with newly-diagnosed metastatic brain tumors undergo stereotactic radiosurgery (SRS) compared with other treatment modalities?

Target population

These recommendations apply to adults with newly diagnosed solid brain metastases amenable to SRS; lesions amenable to SRS are typically defined as measuring less than 3 cm in maximum diameter and producing minimal (less than 1 cm of midline shift) mass effect.

Recommendations

SRS plus WBRT vs. WBRT alone

Level 1 Single-dose SRS along with WBRT leads to significantly longer patient survival compared with WBRT alone for patients with single metastatic brain tumors who have a KPS ≥ 70.

Level 2 Single-dose SRS along with WBRT is superior in terms of local tumor control and maintaining functional status when compared to WBRT alone for patients with 1–4 metastatic brain tumors who have a KPS ≥ 70.

Level 3 Single-dose SRS along with WBRT may lead to significantly longer patient survival than WBRT alone for patients with 2–3 metastatic brain tumors.

Level 4 There is class III evidence demonstrating that single-dose SRS along with WBRT is superior to WBRT alone for improving patient survival for patients with single or multiple brain metastases and a KPS < 70.

SRS plus WBRT vs. SRS alone

Level 2 Single-dose SRS alone may provide an equivalent survival advantage for patients with brain metastases compared with WBRT + single-dose SRS. There is conflicting class I and II evidence regarding the risk of both local and distant recurrence when SRS is used in isolation, and class I evidence demonstrates a lower risk of distant recurrence with WBRT; thus, regular careful surveillance is warranted for patients treated with SRS alone in order to provide early identification of local and distant recurrences so that salvage therapy can be initiated at the soonest possible time.

Surgical Resection plus WBRT vs. SRS ± WBRT

Level 2 Surgical resection plus WBRT, vs. SRS plus WBRT, both represent effective treatment strategies, resulting in relatively equal survival rates. SRS has not been assessed from an evidence-based standpoint for larger lesions (>3 cm) or for those causing significant mass effect (>1 cm midline shift). Level 3: Underpowered class I evidence along with the preponderance of conflicting class II evidence suggests that SRS alone may provide equivalent functional and survival outcomes compared with resection + WBRT for patients with single brain metastases, so long as ready detection of distant site failure and salvage SRS are possible.

SRS alone vs. WBRT alone

Level 3 While both single-dose SRS and WBRT are effective for treating patients with brain metastases, single-dose SRS alone appears to be superior to WBRT alone for patients with up to three metastatic brain tumors in terms of patient survival advantage.

M. E. Linskey
Department of Neurosurgery, University of California-Irvine Medical Center, Orange, CA, USA

D. W. Andrews
Department of Neurosurgery, Thomas Jefferson University, Philadelphia, PA, USA

ELEKTA

Addendum C – Tsao, M., W. Xu, and A. Sahgal, A meta-analysis evaluating stereotactic radiosurgery, whole-brain radiotherapy, or both for patients presenting with a limited number of brain metastases. Cancer, 2011.

See separate attachment.

Original Article

A Meta-Analysis Evaluating Stereotactic Radiosurgery, Whole-Brain Radiotherapy, or Both for Patients Presenting with a Limited Number of Brain Metastases

May Tsao, MD[1], Wei Xu, PhD[2], and Arjun Sahgal, MD[3,4]

BACKGROUND: To perform a meta-analysis on newly diagnosed brain metastases patients treated with whole-brain radiotherapy (WBRT) and stereotactic radiosurgery (SRS) boost versus WBRT alone, or in patients treated with SRS alone versus WBRT and SRS boost. **METHODS:** The meta-analysis primary outcomes were overall survival (OS), local control (LC), and distant brain control (DBC); secondary outcomes were neurocognition, quality of life (QOL), and toxicity. Using published Kaplan-Meier curves, results were pooled using hazard ratios (HR). **RESULTS:** Two RCTs reported on WBRT and SRS boost versus WBRT alone. For multiple brain metastases (2-4 tumors) we conclude no difference in OS, and LC significantly favored WBRT plus SRS boost. Three RCTs reported on SRS alone versus WBRT plus SRS boost (1-4 tumors). There was no difference in OS despite both LC and DBC significantly favoring WBRT plus SRS boost. Although secondary endpoints could not be pooled for meta-analysis, those RCTs evaluating SRS alone conclude better neurocognition using the validated Hopkins Verbal Learning Test, no adverse risk in deteriorating Mini-Mental State Exam scores or in maintaining performance status, and fewer late toxicities. We conclude insufficient data for QOL outcomes. **CONCLUSIONS:** For selected patients, we conclude no OS benefit for WBRT plus SRS boost compared with SRS alone. Although additional WBRT improves DBC and LC, SRS alone should be considered a routine treatment option due to favorable neurocognitive outcomes, less risk of late side effects, and does not adversely affect the patients performance status. Cancer 2011;000:000–000. © 2011 American Cancer Society.

KEYWORDS: brain metastases, stereotactic radiosurgery, whole brain radiotherapy, meta-analysis, neurocognition.

INTRODUCTION

Treatment options for selected patients with good prognosis (eg, Karnofsky performance status [KPS] at least 70% or World Health Organization (WHO) performance status of 0-2 and controlled or quiescent extracranial disease[1,2]) have evolved over the last few decades. Whole brain radiation (WBRT)[3] and steroids were the standard of care before the development of stereotactic radiosurgery (SRS). As SRS developed into a safe and focal high dose treatment for brain metastasis[4] to optimize local control, the first question to be tested was the use of SRS as a "boost" to WBRT.[5,6] Two randomized controlled trials (RCTs) were conducted and concluded significant improvements in local control secondary to boost SRS,[5,6] and 1 study reported a modest overall survival (OS) benefit for patients with only a single brain metastasis.[5]

The question then evolved to test SRS alone with the intent to spare patients the side effects of WBRT, notably neurocognition. The landmark RCT was reported in 2006 by Aoyama et al,[7] where patients with 1 to 4 brain metastases were randomized to SRS alone or WBRT and SRS boost. Although WBRT and SRS boost resulted in a modest gain in local control and a lower incidence of new brain metastases, no OS difference was observed (this trial was initially powered for OS; however, halted at the interim analysis with sufficient power to detect a significant difference in brain tumor recurrence rates). It is only recently that 2 RCTs[8,9] have been reported comparing SRS alone to WBRT and SRS boost to further our understanding of the treatment options and expand our knowledge beyond the Aoyama study.[7] However, these 2

Corresponding author: Arjun Sahgal, MD, Department of Radiation Oncology, Sunnybrook Health Sciences Centre, 2075 Bayview Avenue, Toronto, Ontario M4N 3M5, Canada; Fax (416) 480-6101; Arjun.Sahgal@sunnybrook.ca

[1]Department of Radiation Oncology, Odette Cancer Centre, Sunnybrook Health Sciences Centre, Toronto, Ontario, Canada; [2]Department of Biostatistics, University Health Network, Toronto, Ontario, Canada; [3]Department of Radiation Oncology, Princess Margaret Hospital, Toronto, Ontario, Canada; [4]University of Toronto, Toronto, Ontario, Canada

DOI: 10.1002/cncr.26305, **Received:** July 11, 2011; **Revised:** August 1, 2011; **Accepted:** August 1, 2011; **Published online** in Wiley Online Library (wileyonlinelibrary.com)

ELEKTA

Addendum D – Apparatus dependence of normal brain tissue dose in stereotactic radiosurgery for multiple brain metastases

See separate attachment.

See the corresponding editorial. DOI: 10.3171/2010.12.JNS102034.

DOI: 10.3171/2011.1.JNS101056

Apparatus dependence of normal brain tissue dose in stereotactic radiosurgery for multiple brain metastases

Technical note

Lijun Ma, Ph.D.,[1] Paula Petti, Ph.D.,[2] Brian Wang, Ph.D.,[1] Martina Descovich, Ph.D.,[1] Cynthia Chuang, Ph.D.,[1] Igor J. Barani, M.D.,[1] Sandeep Kunwar, M.D.,[1] Dennis C. Shrieve, M.D., Ph.D.,[3] Arjun Sahgal, M.D.,[4] and David A. Larson, M.D., Ph.D.[1,2]

[1]*Department of Radiation Oncology, University of California, San Francisco;* [2]*Washington Fremont Hospital Gamma Knife Center, Fremont, California;* [3]*Department of Radiation Oncology, University of Utah, Salt Lake City, Utah; and* [4]*Department of Radiation Oncology, Sunnybrook Odette Cancer Centre, Princess Margaret Hospital, University of Toronto, Ontario, Canada*

Object. Technical improvements in commercially available radiosurgery platforms have made it practical to treat a large number of intracranial targets. The goal of this study was to investigate whether the dose to normal brain when planning radiosurgery to multiple targets is apparatus dependent.

Methods. The authors selected a single case involving a patient with 12 metastatic lesions widely distributed throughout the brain as visualized on contrast-enhanced CT. Target volumes and critical normal structures were delineated with Leksell Gamma Knife Perfexion software. The imaging studies including the delineated contours were digitally exported into the CyberKnife and Novalis multileaf collimator–based planning systems for treatment planning using identical target dose goals and dose-volume constraints. Subsets of target combinations (3, 6, 9, or 12 targets) were planned separately to investigate the relationship of number of targets and radiosurgery platform to the dose to normal brain.

Results. Despite similar target dose coverage and dose to normal structures, the dose to normal brain was strongly apparatus dependent. A nonlinear increase in dose to normal brain volumes with increasing number of targets was also noted.

Conclusions. The dose delivered to normal brain is strongly dependent on the radiosurgery platform. How general this conclusion is and whether apparatus dependent differences are related to differences in hardware design or differences in dose-planning algorithms deserve further investigation. *(DOI: 10.3171/2011.1.JNS101056)*

Key Words • Gamma Knife • CyberKnife • Novalis • stereotactic radiosurgery • treatment planning • brain metastasis

Stereotactic radiosurgery, with or without WBRT, is commonly used in the treatment of patients with a limited number of metastatic brain tumors. The clinical role of radiosurgery in patients with more than 4 or 5 brain metastases has not been established. Nevertheless, given the technical developments in SRS apparatuses in recent years, it is now practical to treat such patients with SRS with any of several various radiosurgery platforms, including Leksell Gamma Knife Perfexion (Elekta), CyberKnife (Accuray), and Novalis (BrainLab AG).

Perfexion uses a new sector-based collimator design with collimators that can be activated rapidly to permit a large combination of beam apertures at the isocenter, resulting in reduced procedure times and highly conformal dose distributions for both individual and multiple targets.[5,8] The CyberKnife and Novalis multileaf collimator–based systems have had marked technical improvements applicable to the treatment of multiple targets.[9,10,12] In particular, there has been a several-fold increase in machine output and the speed of changing beam directions (CyberKnife) or individual multileaf-collimator leaf motions (Novalis). For treatment of a large number of brain lesions these technical features can be particularly beneficial.

For each of these technologies, there has been clinical concern regarding the dose to normal brain. For example, some studies have reported a possible relationship between normal brain volumes, such as the 10- or 12-Gy volume, and treatment-related toxicity,[13] and we have previously reported the possible need for target dose reductions in patients with multiple metastases treated with

Abbreviations used in this paper: SRS = stereotactic radiosurgery; WBRT = whole brain radiation therapy.

Addendum E – Excerpt from Regence BCBS Medical Policy on Stereotactic Radiosurgery

(http://blue.regence.com/trgmedpol/surgery/sur16.html)

Medical Policy

Introduction | Table of Contents | Recent Updates | Contact Medical Policy Staff

Surgery Section - Stereotactic Radiosurgery and Stereotactic Body Radiation Therapy

Topic: Stereotactic Radiosurgery and Stereotactic Body Radiation Therapy
Section: Surgery
Effective Date: 01/01/2012

Date of Origin: 01/1996

Policy No: 16

POLICY/CRITERIA

I. Stereotactic radiosurgery (SRS) and stereotactic body radiation therapy (SBRT) using Gamma Knife®, LINAC, Cyberknife®, BrainLAB Novalis®, or TomoTherapy® units may be considered **medically necessary** for the following indications:
   A. Intracranial arteriovenous malformations
   B. Acoustic neuromas (also known as Vestibular Schwannomas)
   C. Pituitary adenomas
   D. Non-resectable, residual, or recurrent meningiomas
   E. Solitary or multiple brain metastases in patients who meet both of the following:
      1. Karnofsky performance score ≥70 (or an ECOG score ≤2); AND
      2. Life expectancy >6 months.
   F. Primary malignancies of the CNS, including but not limited to high-grade gliomas (initial treatment or treatment of recurrence)
   G. Spinal or vertebral body tumors (metastatic or primary) in patients who have received prior radiation therapy
   H. Trigeminal neuralgia (also known as tic douloureux) refractory to medical management
   I. Stage 1 non-small cell lung cancer (NSCLC) when the patient is an unsuitable candidate for surgical resection.
      1. Stage 1 NSCLC is defined by the following clinical stage groupings: [1]
         a. T1, N0, M0
         b. T2, N0, M0
   J. Lung metastases when all of the following criteria are met:
      1. Life expectancy >6 months
      2. Karnofsky performance score ≥70
      3. Adequate lung function
      4. Locally controlled primary tumor
      5. ≤3 metastatic lung lesions (oligometastases)
      6. Targeted tumor diameter ≤5cm
      7. Clinical records from a cardiothoracic surgeon document at least one of the following:
         a. The tumor is not resectable; or
         b. The patient is not a good surgical candidate.
      8. No other metastatic disease

II. Stereotactic radiosurgery and stereotactic body radiation therapy are considered **investigational** for all other indications including but not limited to:
   A. Functional disorders other than trigeminal neuralgia
   B. Epilepsy
   C. Chronic pain
   D. Treatment of extracranial sites (e.g. prostate, ovaries), except for the cases of spinal tumors, stage 1 non-small cell lung cancer, and lung metastases as noted above
   E. Refractory symptoms of essential tremor or Parkinson's disease

APPENDIX C. ATTACHMENTS SUBMITTED BY VARIAN MEDICAL SYSTEMS

SRS AND SBRT BIBLIOGRAPHY

CLINICAL AND TECHNICAL JOURNAL PUBLICATIONS 2000 THROUGH DECEMBER 2010

WHERE VARIAN LINACS WERE USED FOR SRS & SBRT OR VARIAN USER'S-DEVELOPED ENABLING TECHNIQUES ARE USED IN SRS & SBRT

BRAIN TUMORS – BENIGN

Benign Meningioma & Other Benign Tumors [20]

Korah MP, Nowlan AW, Johnstone PA, Crocker IR. Radiation Therapy Alone for Imaging-Defined Meningiomas. *Int J Radiat Oncol Biol Phys.* 2010 Jan 1;76(1):181-6. *Emory University, Atlanta*

Golanov AV, Cherekaev VA, Serova NK, Pronin IN, Gorlachev GE, Kotel'nikova TM, Podoprigora AE, Kudriavtseva PA, Galkin MV [Linear accelerator-based stereotactic radiation treatment of patients with medial middle fossa meningiomas] *Zh Vopr Neirokhir Im N N Burdenko.* 2010 Jan-Mar;(1):13-8. Russian.

Anker CJ, Shrieve DC. Basic principles of radiobiology applied to radiosurgery and radiotherapy of benign skull base tumors. *Otolaryngol Clin North Am.* 2009 Aug;42(4):601-21. *University of Utah, Salt Lake City*

Kimball MM, Friedman WA, Foote KD, Bova FJ, Chi YY. Linear Accelerator Radiosurgery for Cavernous Sinus Meningiomas. *Stereotact Funct Neurosurg.* 2009 Feb 27;87(2):120-127. *University of Florida, Gainsville*

Fogliata A, Clivio A, Nicolini G, Vanetti E, Cozzi L. Intensity modulation with photons for benign intracranial tumours: a planning comparison of volumetric single arc, helical arc and fixed gantry techniques. *Radiother Oncol.* 2008 Dec;89(3):254-62. *Oncology Institute of Southern Switzerland, Bellinzona, Switzerland.*

Girvigian MR, Chen JC, Rahimian J, Miller MJ, Tome M. Comparison of early complications for patients with convexity and parasagittal meningiomas treated with either stereotactic radiosurgery or fractionated stereotactic radiotherapy. *Neurosurgery*. 2008 May;62(5 Suppl):A19-27. *Southern California Permanente Medical Group and Kaiser Foundation, Los Angeles*

Hamm KD, Gross MW, Fahrig A, Surber G, Henzel M, Kleinert G, Grabenbauer GG, Engenhart-Cabillic R. Stereotactic radiotherapy for the treatment of nonacoustic schwannomas. *Neurosurgery*. 2008 May;62(5 Suppl):A29-36 *Helios Klinikum Erfurt, Erfurt, Germany*

Kan P, Liu JK, Wendland MM, Shrieve D, Jensen RL. Peritumoral edema after stereotactic radiosurgery for intracranial meningiomas and molecular factors that predict its development. *J Neurooncol*. 2007 May;83(1):33-8. *University of Utah, Salt Lake City*

Ernst-Stecken A, Lambrecht U, Mueller R, Ganslandt O, Sauer R, Grabenbauer G. Dose escalation in large anterior skull-base tumors by means of IMRT. First experience with the Novalis system. *Strahlenther Onkol*. 2006 Mar;182(3):183-9. *University Hospital of Erlangen-Nuremberg, Erlangen, DE*

Shrieve DC, Hazard L, Boucher K, Jensen RL. Dose fractionation in stereotactic radiotherapy for parasellar meningiomas: radiobiological considerations of efficacy and optic nerve tolerance. *J Neurosurg*. 2004 Nov;101 Suppl 3:390-5. *University of Utah, Salt Lake City*

Baumert BG, Villà S, Studer G, Mirimanoff RO, Davis JB, Landau K, Ducrey N, Arruga J, Lambin P, Pica A. Early improvements in vision after fractionated stereotactic radiotherapy for primary optic nerve sheath meningioma. *Radiother Oncol.* 2004 Aug;72(2):169-74. *University Hospital Zurich, SW.*

Selch MT, Ahn E, Laskari A, Lee SP, Agazaryan N, Solberg TD, Cabatan-Awang C, Frighetto L, Desalles AA. Stereotactic radiotherapy for treatment of cavernous sinus meningiomas. *Int J Radiat Oncol Biol Phys.* 2004 May 1;59(1):101-11. *UCLA, Los Angeles*

Biswas T, Sandhu AP, Singh DP, Schell MC, Maciunas RJ, Bakos RS, Muhs AG, Okunieff P. Low-dose radiosurgery for benign intracranial lesions. *Am J Clin Oncol.* 2003 Aug;26(4):325-31. *University of Rochester Medical Center, Rochester, NY*

Torres RC, Frighetto L, De Salles AA, Goss B, Medin P, Solberg T, Ford JM, Selch M. Radiosurgery and stereotactic radiotherapy for intracranial meningiomas. *Neurosurg Focus*. 2003 May 15;14(5):e5. *UCLA, Los Angeles*

Liu JK, Forman S, Moorthy CR, Benzil DL. Update on treatment modalities for optic nerve sheath meningiomas. *Neurosurg Focus.* 2003 May 15;14(5):e7, *University of Utah, Salt Lake City* Spiegelmann R, Nissim O, Menhel J,

Alezra D, Pfeffer MR. Linear accelerator radiosurgery for meningiomas in and around the cavernous sinus. *Neurosurgery*. 2002 Dec;51(6):1373-79; discussion 1379-80. *The Chaim Sheba Medical Center, Tel Hashomer, IS*

Andrews DW, Faroozan R, Yang BP, Hudes RS, Werner-Wasik M, Kim SM, Sergott RC, Savino PJ, Shields J, Shields C, Downes MB, Simeone FA, Goldman HW, Curran WJ Jr. Fractionated stereotactic radiotherapy for the treatment of optic nerve sheath meningiomas: preliminary observations of 33 optic nerves in 30 patients with historical comparison to observation with or without prior surgery. *Neurosurgery*. 2002 Oct;51(4):890-902; discussion 903-4. *Thomas Jefferson University, Philadelphia*

Villavicencio AT, Black PM, Shrieve DC, Fallon MP, Alexander E, Loeffler JS. Linac radiosurgery for skull base meningiomas. *Acta Neurochir (Wien).* 2001 Nov;143(11):1141-52. *Brigham and Women's Hospital, Boston*

De Salles AA, Frighetto L, Grande CV, Solberg TD, Cabatan-Awang C, Selch MT, Wallace R, Ford J. Radiosurgery and stereotactic radiation therapy of skull base meningiomas: proposal of a grading system. *Stereotact Funct Neurosurg*. 2001;76(3-4):218-29. *UCLA, Los Angeles*

Shafron DH, Friedman WA, Buatti JM, Bova FJ, Mendenhall WM. Linac radiosurgery for benign meningiomas. *Int J Radiat Oncol Biol Phys.* 1999 Jan 15;43(2):321-7. *University of Florida, Gainesville*

BRAIN TUMORS – BENIGN

Vestibular Schwannoma (Acoustic Neuroma) [22]

Kopp C, Fauser C, Müller A, Astner ST, Jacob V, Lumenta C, Meyer B, Tonn JC, Molls M, Grosu AL. Stereotactic Fractionated Radiotherapy and LINAC Radiosurgery in the Treatment of Vestibular Schwannoma- Report About Both Stereotactic Methods From a Single Institution. *Int J Radiat Oncol Biol Phys.* 2010 Aug 12. *Technische Universität München, Munich,* [Epub ahead of print]

Bassim MK, Berliner KI, Fisher LM, Brackmann DE, Friedman RA. Radiation therapy for the treatment of vestibular schwannoma: a critical evaluation of the state of the literature. *Otol Neurotol*. 2010 Jun;31(4):567- 73. Review. *American University of Beirut, Beirut,*

Hsu PW, Chang CN, Lee ST, Huang YC, Chen HC, Wang CC, Hsu YH, Tseng CK, Chen YL, Wei KC. Outcomes of 75 patients over 12 years treated for acoustic neuromas with linear accelerator-based radiosurgery. *J Clin Neurosci.* 2010 May;17(5):556-60. *Chang Gung University, Kweishan, Taoyuan, TW*

Lin YC, Wang CC, Wai YY, Wan YL, Ng SH, Chen YL, Liu HL, Wang JJ. Significant Temporal Evolution of Diffusion Anisotropy for Evaluating Early Response to Radiosurgery in Patients with Vestibular Schwannoma: Findings from Functional Diffusion Maps. *AJNR Am J Neuroradiol*. 2010 Feb;31(2):269-74. *Chang Gung University, Taiwan, Republic of China*.

Lagerwaard FJ, Meijer OW, van der Hoorn EA, Verbakel WF, Slotman BJ, Senan S. Volumetric modulated arc radiotherapy for vestibular schwannomas. *Int J Radiat Oncol Biol Phys*. 2009 Jun 1;74(2):610-5. *VU University Medical Center, Amsterdam*

Andrews DW, Werner-Wasik M, Den RB, Paek SH, Downes-Phillips B, Willcox TO, Bednarz G, Maltenfort M, Evans JJ, Curran WJ Jr. Toward dose optimization for fractionated stereotactic radiotherapy for acoustic neuromas: comparison of two dose cohorts. *Int J Radiat Oncol Biol Phys*. 2009 Jun 1;74(2):419-26. *Thomas Jefferson University, Philadelphia*

Friedman WA. Linear accelerator radiosurgery for vestibular schwannomas. *Prog Neurol Surg.* 2008;21:228- 37. *University of Florida, Gainesville*

Kuo YH, Roos D, Brophy BP. Linear accelerator radiosurgery for treatment of vestibular schwannomas in neurofibromatosis 2. *J Clin Neurosci*. 2008 Jul;15(7):744-8., *Royal Adelaide Hospital, North Terrace, Adelaide, AU*

Meijer OW, Vandertop WP, Lagerwaard FJ, Slotman BJ. Linear accelerator-based stereotactic radiosurgery for bilateral vestibular schwannomas in patients with neurofibromatosis type 2. *Neurosurgery*. 2008 May;62(5 Suppl):A37-43, *VU University Medical Center, Amsterdam*

Beegle RD, Friedman WA, Bova FJ. Effect of treatment plan quality on outcomes after radiosurgery for vestibular schwannoma. *J Neurosurg*. 2007 Nov;107(5):913-6 *University of Florida, Gainesville*.

Radu A, Pica A, Villemure JG, Maire R. [Indications and results of stereotactic radiosurgery with LINAC for the treatment of acoustic neuromas: preliminary results] *Ann Otolaryngol Chir Cervicofac.* 2007 Jul;124(3):110-4. *CHU Vaudois, Lausanne*

Friedman WA, Bradshaw P, Myers A, Bova FJ. Linear accelerator radiosurgery for vestibular schwannomas. *J Neurosurg*. 2006 Nov;105(5):657-61. *University of Florida, Gainesville*

Selch MT, Pedroso A, Lee SP, Solberg TD, Agazaryan N, Cabatan-Awang C, DeSalles AA. Stereotactic radiotherapy for the treatment of acoustic neuromas. *J Neurosurg*. 2004 Nov;101 Suppl 3:362-72. *UCLA, Los Angeles*

Surber G, Hamm K, Kleinert G. Significance of different conformity indices for evaluation of radiosurgery treatment plans for vestibular schwannomas. *J Neurosurg.* 2004 Nov;101 Suppl 3:334-40. *Helios Klinikum Erfurt, Germany*

Isodosimetric comparison of photon stereotactic radiosurgery techniques (gamma knife vs. micromultileaf collimator linear accelerator) for acoustic neuroma--and potential clinical importance. *Int J Radiat Oncol Biol Phys.* 2003 Dec 1;57(5):1450-9. *St. Bartholomew's Hospital, London*

Meijer OW, Vandertop WP, Baayen JC, Slotman BJ. Single-fraction vs. fractionated linac-based stereotactic radiosurgery for vestibular schwannoma: a single-institution study. *Int J Radiat Oncol Biol Phys.* 2003 Aug 1;56(5):1390-6. *VU University Medical Center, Amsterdam*

Friedman WA, Foote KD. Linear accelerator-based radiosurgery for vestibular schwannoma, *Neurosurg Focus*. 2003 May 15;14(5):e2. *University of Florida, Gainesville*

Foote KD, Friedman WA, Buatti JM, Meeks SL, Bova FJ, Kubilis PS. Analysis of risk factors associated with radiosurgery for vestibular schwannoma. *J Neurosurg*. 2001 Sep;95(3):440-9. *University of Florida, Gainesville*

Andrews DW, Suarez O, Goldman HW, Downes MB, Bednarz G, Corn BW, Werner-Wasik M, Rosenstock J, Curran WJ Jr. Stereotactic radiosurgery and fractionated stereotactic radiotherapy for the treatment of acoustic schwannomas: comparative observations of 125 patients treated at one institution. *Int J Radiat Oncol Biol Phys.* 2001 Aug 1;50(5):1265-78.*Thomas Jefferson University, Philadelphia.*

Spiegelmann R, Lidar Z, Gofman J, Alezra D, Hadani M, Pfeffer R. Linear accelerator radiosurgery for vestibular schwannoma. *J Neurosurg*. 2001 Jan;94(1):7-13. *The Chaim Sheba Medical Center, Tel Hashomer, IS.*

Meeks SL, Buatti JM, Foote KD, Friedman WA, Bova FJ. Calculation of cranial nerve complication probability for acoustic neuroma radiosurgery. *Int J Radiat Oncol Biol Phys.* 2000 Jun 1;47(3):597-602. *University of Florida, Gainesville*

Mabanta SR, Buatti JM, Friedman WA, Meeks SL, Mendenhall WM, Bova FJ. Linear accelerator radiosurgery for nonacoustic schwannomas. *Int J Radiat Oncol Biol Phys.* 1999 Feb 1;43(3):545-8. *University of Florida, Gainesville*

BRAIN TUMORS – BENIGN

Pituitary Adenoma, Craniopharyngioma and Cushing's Disease [10]

Yang I, Kim W, De Salles A, Bergsneider M. A systematic analysis of disease control in acromegaly treated with radiosurgery. *Neurosurg Focus.* 2010 Oct;29(4):E13, *University of California, Los Angeles, California*

Ramakrishna N. The role of fractionated radiotherapy and stereotactic radiosurgery for pituitary adenomas. *Nat Clin Pract Endocrinol Metab.* 2008 Mar;4(3):138-9. *Brigham and Women's Hospital – Harvard University, Boston*

McClelland S 3rd, Higgins PD, Gerbi BJ, Orner JB, Hall WA. Fractionated stereotactic radiotherapy for pituitary adenomas following microsurgical resection: safety and efficacy. *Technol Cancer Res Treat.* 2007 Jun;6(3):177-80. *University of Minnesota Medical School, Minneapolis*

Devisetty K, Chen LF, Chmura SJ. Evolving use of radiotherapy and radiosurgery in the treatment of pituitary adenomas. *Expert Rev Anticancer Ther.* 2006 Sep;6 Suppl 9:S93-8. Review*. University of Chicago, Chicago, IL*

Selch MT, Gorgulho A, Lee SP, Mattozo C, Solberg TD, Agazaryan N, Desalles AA, Stereotactic radiotherapyfor the treatment of pituitary adenomas. *Minim Invasive Neurosurg*. 2006 Jun;49(3):150-5. Jun;49(3):150-5. *UCLA, Los Angeles*

Colin P, Jovenin N, Delemer B, Caron J, Grulet H, Hecart AC, Lukas C, Bazin A, Bernard MH, Scherpereel B, Peruzzi P, Nakib I, Redon C, Rousseaux P. Treatment of pituitary adenomas by fractionated stereotactic radiotherapy: a prospective study of 110 patients. *Int J Radiat Oncol Biol Phys*. 2005 Jun 1;62(2):333-41. *Polyclinique Courlancy, Reims, FR*

Devin JK, Allen GS, Cmelak AJ, Duggan DM, Blevins LS. The efficacy of linear accelerator radiosurgery in the management of patients with Cushing's disease. *Stereotact Funct Neurosurg*. 2004;82(5-6):254-62. *Vanderbilt University School of Medicine, Nashville*

Swords FM, Allan CA, Plowman PN, Sibtain A, Evanson J, Chew SL, Grossman AB, Besser GM, Monson JP. Stereotactic radiosurgery XVI: a treatment for previously irradiated pituitary adenomas. *J Clin Endocrinol Metab.* 2003 Nov;88(11):5334-40. *St. Bartholomew's and The Royal London School of Medicine, London. United Kingdom.*

Liu JK, Schmidt MH, MacDonald JD, Jensen RL, Couldwell WT. Hypophysial transposition (hypophysopexy) for radiosurgical treatment of pituitary tumors involving the cavernous sinus. Technical note. *Neurosurg Focus.* 2003 May 15;14(5):e11. *University of Utah, Salt Lake City*

Selch MT, DeSalles AA, Wade M, Lee SP, Solberg TD, Wallace RE, Ford JM, Rubino G, Cabatan-Awang C, Withers HR. Initial clinical results of stereotactic radiotherapy for the treatment of craniopharyngiomas. *Technol Cancer Res Treat*. 2002 Feb;1(1):51-9. *UCLA, Los Angeles*

BRAIN TUMORS – MALIGNANT & METASTATIC

Glioma / Glioblastoma / Malignant Meningioma [16]

Fields EC, Damek D, Gaspar LE, Liu AK, Kavanagh BD, Waziri A, Lillehei K, Chen C. Phase I Dose Escalation Trial of Vandetanib With Fractionated Radiosurgery in Patients With Recurrent Malignant Gliomas. *Int J Radiat Oncol Biol Phys.* 2010 Oct 29. *University of Colorado, Aurora* [Epub ahead of print]

Shaffer R, Nichol AM, Vollans E, Fong M, Nakano S, Moiseenko V, Schmuland M, Ma R, McKenzie M, Otto K. A Comparison of Volumetric Modulated Arc Therapy and Conventional Intensity-Modulated Radiotherapy for Frontal and Temporal High-Grade Gliomas. *Int J Radiat Oncol Biol Phys.* 2010 Mar 15;76(4):1177-84. *BC Cancer Agency, Vancouver, British Columbia*

Gutin PH, Iwamoto FM, Beal K, Mohile NA, Karimi S, Hou BL, Lymberis S, Yamada Y, Chang J, Abrey LE. Safety and efficacy of bevacizumab with hypofractionated stereotactic irradiation for recurrent malignant gliomas. *Int J Radiat Oncol Biol Phys.* 2009 Sep 1;75(1):156-63. *Memorial Sloan-Kettering Cancer Center, New York, NY*

Schwer AL, Kavanagh BD, McCammon R, Gaspar LE, Kleinschmidt-De Masters BK, Stuhr K, Chen C. Radiographic and Histopathologic Observations After Combined EGFR Inhibition and Hypofractionated Stereotactic Radiosurgery in Patients with Recurrent Malignant Gliomas. *Int J Radiat Oncol Biol Phys*. 2009 Apr 1;73(5):1352-7. *University of Colorado Denver, Aurora, CO*

Biswas T, Okunieff P, Schell MC, Smudzin T, Pilcher WH, Bakos RS, Vates GE, Walter KA, Wensel A, Korones DN, Milano MT. Stereotactic radiosurgery for glioblastoma: retrospective analysis. *Radiat Oncol.* 2009 Mar 17;4(1):11. *University of Rochester, Rochester, NY*

Krishnan AP, Asher IM, Davis D, Okunieff P, O'Dell WG. Evidence that MR diffusion tensor imaging (tractography) predicts the natural history of regional progression in patients irradiated conformally for primary brain tumors. *Int J Radiat Oncol Biol Phys.* 2008 Aug 1;71(5):1553-62. *University of Rochester, Rochester, NY*

Swinson BM, Friedman WA. Linear accelerator stereotactic radiosurgery for metastatic brain tumors: 17 years of experience at the University of Florida. *Neurosurgery*. 2008 May;62(5):1018-31; discussion 1031-2. *University of Florida, Gainesville*

Mattozo CA, De Salles AA, Klement IA, Gorgulho A, McArthur D, Ford JM, Agazaryan N, Kelly DF, Selch MT. Stereotactic radiation treatment for recurrent nonbenign meningiomas. *J Neurosurg*. 2007 May;106(5):846-54. *UCLA, Los Angeles*

Han SR, Yoon SW, Yee GT, Choi CY, Sohn MJ, Lee DJ, Whang CJ. Novalis radiosurgery of optic gliomas in children: preliminary report. *Pediatr Neurosurg*. 2007;43(4):251-7. *Inje University, Goyang, KR*

Ernst-Stecken A, Ganslandt O, Lambrecht U, Sauer R, Grabenbauer G. Survival and quality of life after hypofractionated stereotactic radiotherapy for recurrent malignant glioma. *J Neurooncol*. 2007 Feb;81(3):287- 94. *University of Erlangen, Erlangen, Germany*

Lo SS, Chang EL, Sloan AE. Role of stereotactic radiosurgery and fractionated stereotactic radiotherapy in the management of intracranial ependymoma. *Expert Rev Neurother*. 2006 Apr;6(4):501-7. *MD Anderson Cancer Center, Houston*

Ulm AJ 3rd, Friedman WA, Bradshaw P, Foote KD, Bova FJ. Radiosurgery in the treatment of malignant gliomas: the University of Florida experience. *Neurosurgery*. 2005 Sep;57(3):512-7; discussion 512-7. *University of Florida, Gainesville*

Mahajan A, McCutcheon IE, Suki D, Chang EL, Hassenbusch SJ, Weinberg JS, Shiu A, Maor MH, Woo SY. Case-control study of stereotactic radiosurgery for recurrent glioblastoma multiforme. *J Neurosurg.* 2005 Aug;103(2):210-7. *MD Anderson Cancer Center, Houston*

Ulm AJ 3rd, Friedman WA, Bradshaw P, Foote KD, Bova FJ. Radiosurgery in the treatment of malignant gliomas: the University of Florida experience. *Neurosurgery*. 2005 Sep;57(3):512-7; discussion 512-7. *University of Florida, Gainesville*

Souhami L, Seiferheld W, Brachman D, Podgorsak EB, Werner-Wasik M, Lustig R, Schultz CJ, Sause W, Okunieff P, Buckner J, Zamorano L, Mehta MP, Curran WJ Jr. Randomized comparison of stereotactic radiosurgery followed by conventional radiotherapy with carmustine to conventional radiotherapy with carmustine for patients with glioblastoma multiforme: report of Radiation Therapy Oncology Group 93-05 protocol. *Int J Radiat Oncol Biol Phys.* 2004 Nov 1;60(3):853-60. *McGill University, Montreal*

Buatti JM, Friedman WA, Meeks SL, Bova FJ. RTOG 90-05: the real conclusion. *Int J Radiat Oncol Biol Phys.* 2000 May 1;47(2):269-71. *University of Florida, Gainesville*

BRAIN TUMORS – MALIGNANT & METASTATIC

Metastatic Disease [37]

Kelly PJ, Lin YB, Yu AY, Alexander BM, Hacker F, Marcus KJ, Weiss SE. Stereotactic Irradiation of the Postoperative Resection Cavity for Brain Metastasis: A Frameless Linear Accelerator-Based Case Series and Review of the Technique. *Int J Radiat Oncol Biol Phys.* 2010 Dec 17. *Dana-Farber/Brigham and Women's*

Cancer Center, Boston [Epub ahead of print] Roberge D, Souhami L. Tumor bed radiosurgery following resection of brain metastases: a review. *Technol Cancer Res Treat*. 2010 Dec;9(6):597-602. *McGill University, Montreal* Stewart

JG, Sawrie SM, Bag A, Han X, Fiveash JB. Management of brain metastases. *Curr Treat Options Neurol*. 2010 Jul;12(4):334-46. *University of Alabama at Birmingham, Birmingham, AL*

Ma Y, Li M, Yin Y, Kong L, Sun X, Lin X, Yu J. Hypofractionated stereotactic radiotherapy for brain metastases: a dosimetric and treatment efficiency comparison between volumetric modulated arc therapy and intensity modulated radiotherapy. *Technol Cancer Res Treat*. 2010 Oct;9(5):499-507. *Shandong Tumor Hospital and Institute, Shandong Province, China.*

Nath SK, Lawson JD, Simpson DR, Vanderspek L, Wang JZ, Alksne JF, Ciacci J, Mundt AJ, Murphy KT. Single-isocenter frameless intensity-modulated stereotactic radiosurgery for simultaneous treatment of multiple brain metastases: clinical experience. *Int J Radiat Oncol Biol Phys.* 2010 Sep 1;78(1):91-7. *UCSD, San Diego, CA*

Hsu F, Carolan H, Nichol A, Cao F, Nuraney N, Lee R, Gete E, Wong F, Schmuland M, Heran M, Otto K. Whole Brain Radiotherapy with Hippocampal Avoidance and Simultaneous Integrated Boost for 1-3 Brain Metastases: A Feasibility Study Using Volumetric Modulated Arc Therapy. *Int J Radiat Oncol Biol Phys.* 2010 Apr;76(5):1480-5 *BC Cancer Agency, Vancouver, British Columbia*

Nath SK, Lawson JD, Wang JZ, Simpson DR, Newman CB, Alksne JF, Mundt AJ, Murphy KT, Opticallyguided frameless linac-based radiosurgery for brain metastases: clinical experience. *J Neurooncol*. 2010 Mar;97(1):67-72. *University of California, San Diego*

Chen JC, Bugoci DM, Girvigian MR, Miller MJ, Arellano A, Rahimian J. Control of brain metastases using frameless image-guided radiosurgery. *Neurosurg Focus.* 2009 Dec;27(6):E6. Review.*Southern California Permanente Medical Group and Kaiser Foundation, Los Angeles*

Gu HW, Sohn MJ, Lee DJ, Lee HR, Lee CH, Whang CJ. Clinical analysis of novalis stereotactic radiosurgery for brain metastases. *J Korean Neurosurg Soc*. 2009 Sep;46(3):245-51. *Inje University College of Medicine, Ilsan Paik Hospital, Goyang, Korea.*

Lagerwaard FJ, van der Hoorn EA, Verbakel WF, Haasbeek CJ, Slotman BJ, Senan S. Whole-Brain Radiotherapy With Simultaneous Integrated Boost to Multiple Brain Metastases Using Volumetric Modulated Arc Therapy. *Int J Radiat Oncol Biol Phys.* 2009 Sep 1;75(1):253-9. *VU University Medical Center, Amsterdam, The Netherlands*

Breneman JC, Steinmetz R, Smith A, Lamba M, Warnick RE. Frameless Image-Guided Intracranial Stereotactic Radiosurgery: Clinical Outcomes for Brain Metastases. *Int J Radiat Oncol Biol Phys*. 2009 . 2009 Jul 1;74(3):702-6 , *Cincinnati Neuroscience Institute, Cincinnati*

Hoefnagels FW, Lagerwaard FJ, Sanchez E, Haasbeek CJ, Knol DL, Slotman BJ, Peter Vandertop W. Radiological progression of cerebral metastases after radiosurgery: assessment of perfusion MRI for differentiating between necrosis and recurrence. *J Neurol.* 2009 Jun;256(6):878-87.*VU University Medical Centre, Amsterdam, The Netherlands*

Samlowski WE, Majer M, Boucher KM, Shrieve AF, Dechet C, Jensen RL, Shrieve DC. Multidisciplinary treatment of brain metastases derived from clear cell renal cancer incorporating stereotactic radiosurgery. *Cancer*. 2008 Nov 1;113(9):2539-48. *University of Utah, Salt Lake City*

Swinson BM, Friedman WA. Linear accelerator stereotactic radiosurgery for metastatic brain tumors: 17 years of experience at the University of Florida. *Neurosurgery*. 2008 May;62(5):1018-32; *University of Florida, Gainesville*

Samlowski WE, Jensen RL, Shrieve DC. Multimodality management of brain metastases in metastatic melanoma patients. *Expert Rev Anticancer Ther.* 2007 Dec;7(12):1699-705. *University of Utah, Salt Lake City*

Fahrig A, Ganslandt O, Lambrecht U, Grabenbauer G, Kleinert G, Sauer R, Hamm K. Hypofractionated Stereotactic Radiotherapy for Brain Metastases : Results from Three Different Dose Concepts. *Strahlenther Onkol.* 2007 Nov;183(11):625-630. *University of Erlangen, Germany*

Akyurek S, Chang EL, Mahajan A, Hassenbusch SJ, Allen PK, Mathews LA, Shiu AS, Maor MH, Woo SY. Stereotactic radiosurgical treatment of cerebral metastases arising from breast cancer. *Am J Clin Oncol*. 2007 Jun;30(3):310-4. *MD Anderson Cancer Center, Houston*

Teh BS, Bloch C, Paulino AC, Shen S, Hinckley L, Baskin D, Butler EB, Amato R. Pathologic complete response in renal cell carcinoma brain metastases treated with stereotactic radiosurgery. *Clin Genitourin Cancer.* 2007 Jun;5(5):334-7. *Baylor College of Medicine – The Methodist Hospital, Houston*

Samlowski WE, Watson GA, Wang M, Rao G, Klimo P Jr, Boucher K, Shrieve DC, Jensen RL. Multimodality treatment of melanoma brain metastases incorporating stereotactic radiosurgery (SRS). *Cancer*. 2007 May 1;109(9):1855-62. *University of Utah, Salt Lake City*

Chang EL, Wefel JS, Maor MH, Hassenbusch SJ 3rd, Mahajan A, Lang FF, Woo SY, Mathews LA, Allen PK, Shiu AS, Meyers CA. A pilot study of neurocognitive function in patients with one to three new brain metastases initially treated with stereotactic radiosurgery alone. *Neurosurgery*. 2007 Feb;60(2):277-83; discussion 283-4. *MD Anderson Cancer Center, Houston*

Narayana A, Chang J, Yenice K, Chan K, Lymberis S, Brennan C, Gutin PH. Hypofractionated stereotactic radiotherapy using intensity-modulated radiotherapy in patients with one or two brain metastases. *Stereotact Funct Neurosurg*. 2007;85(2-3):82-7. *Memorial Sloan-Kettering Cancer Center, New York*

Ernst-Stecken A, Ganslandt O, Lambrecht U, Sauer R, Grabenbauer G. Phase II trial of hypofractionated stereotactic radiotherapy for brain metastases: results and toxicity. *Radiother Oncol*. 2006 Oct;81(1):18-24. *University of Erlangen-Nuremberg, Erlangen, DE*

Bahl G, White G, Alksne J, Vemuri L, Spear MA. Focal radiation therapy of brain metastases after complete surgical resection. *Med Oncol.* 2006;23(3):317-24. *University of California at San Diego*

Doh LS, Amato RJ, Paulino AC, Teh BS. Radiation therapy in the management of brain metastases from renal cell carcinoma. *Oncology* (Williston Park). 2006 May;20(6):603-13; discussion 613, 616, 619-20. *Baylor College of Medicine – The Methodist Hospital, Houston*

Binder D, Temmesfeld-Wollbruck B, Wurm R, Woiciechowsky C, Schaper C, Schurmann D, Suttorp N, BeinertT. [Brain metastases of lung cancer] *Dtsch Med Wochenschr.* 2006 Jan 27;131(4):165-71. *Charité- Universitätsmedizin, Berlin, DE*

Hazard LJ, Jensen RL, Shrieve DC. Role of stereotactic radiosurgery in the treatment of brain metastases. *Am J Clin Oncol*. 2005 Aug;28(4):403-10. *University of Utah, Salt Lake City*

Lo SS, Chang EL, Suh JH. Stereotactic radiosurgery with and without whole-brain radiotherapy for newly diagnosed brain metastases. *Expert Rev Neurother*. 2005 Jul;5(4):487-95. *MD Anderson, Houston*

Fowler BZ, Crocker IR, Johnstone PA. Perineural spread of cutaneous malignancy to the brain: a review of the literature and five patients treated with stereotactic radiotherapy. *Cancer*. 2005 May 15;103(10):2143-53. *Emory University School of Medicine, Atlanta*

Chang EL, Selek U, Hassenbusch SJ 3rd, Maor MH, Allen PK, Mahajan A, Sawaya R, Woo SY. Outcome variation among "radioresistant" brain metastases treated with stereotactic radiosurgery. *Neurosurgery*. 2005 May;56(5):936-45; discussion 936-45. *MD Anderson Cancer Center, Houston*

Ulm AJ, Friedman WA, Bova FJ, Bradshaw P, Amdur RJ, Mendenhall WM. Linear accelerator radiosurgery in the treatment of brain metastases. *Neurosurgery*. 2004 Nov;55(5):1076-85. *University of Florida, Gainesville*

Okunieff P, Schell MC, Ruo R, Hale ER, O'Dell WG, Pilcher W. Long-term management of patients with multiple brain metastases after shaped beam radiosurgery. Case report and review of the literature. *J Neurosurg*. 2004 Nov;101 Suppl 3:406-12. *University of Rochester Medical Center, Rochester, NY*

Selek U, Chang EL, Hassenbusch SJ 3rd, Shiu AS, Lang FF, Allen P, Weinberg J, Sawaya R, Maor MH. Stereotactic radiosurgical treatment in 103 patients for 153 cerebral melanoma metastases. *Int J Radiat Oncol Biol Phys*. 2004 Jul 15;59(4):1097-106. *MD Anderson Cancer Center, Houston*

Chang EL, Hassenbusch SJ 3rd, Shiu AS, Lang FF, Allen PK, Sawaya R, Maor MH. The role of tumor size in the radiosurgical management of patients with ambiguous brain metastases. *Neurosurgery*. 2003 Aug;53(2):272-80; discussion 280-1. *MD Anderson Cancer Center, Houston*

Chitapanarux I, Goss B, Vongtama R, Frighetto L, De Salles A, Selch M, Duick M, Solberg T, Wallace R, Cabatan-Awang C, Ford J. Prospective study of stereotactic radiosurgery without whole brain radiotherapy in patients with four or less brain metastases: incidence of intracranial progression and salvage radiotherapy. *J Neurooncol*. 2003 Jan;61(2):143-9. *UCLA, Los Angeles*

Sanghavi SN, Miranpuri SS, Chappell R, Buatti JM, Sneed PK, Suh JH, Regine WF, Weltman E, King VJ, Goetsch SJ, Breneman JC, Sperduto PW, Scott C, Mabanta S, Mehta MP. Radiosurgery for patients with brain metastases: a multi-institutional analysis, stratified by the RTOG recursive partitioning analysis method. *Int J Radiat Oncol Biol Phys.* 2001 Oct 1;51(2):426-34 *U of Wisconsin, Madison*

Manning MA, Cardinale RM, Benedict SH, Kavanagh BD, Zwicker RD, Amir C, Broaddus WC. Hypofractionated stereotactic radiotherapy as an alternative to radiosurgery for the treatment of patients with brain metastases. *Int J Radiat Oncol Biol Phys.* 2000 Jun 1;47(3):603-8 *UCLA, Los Angeles, CA*

Shaw E, Scott C, Souhami L, Dinapoli R, Kline R, Loeffler J, Farnan N. Single dose radiosurgical treatment of recurrent previously irradiated primary brain tumors and brain metastases: final report of RTOG protocol 90-05. *Int J Radiat Oncol Biol Phys*. 2000 May 1;47(2):291-8. *Wake Forest University, Winston Salem.*

BRAIN – PEDIATRIC [8]

Mirza B, Mønsted A, Harding J, Ohlhues L, Roed H, Juhler M. Stereotactic radiotherapy and radiosurgery in pediatric patients: analysis of indications and outcome. *Childs Nerv Syst.* 2010 Dec;26(12):1785-93. *Rigshospitalet, Copenhagen University Hospital, Copenhagen, DN*

Keshavarzi S, Meltzer H, Ben-Haim S, Benjamin Newman C, D Lawson J, Levy ML, Murphy K. Initial clinical experience with frameless optically guided stereotactic radiosurgery/radiotherapy in pediatric patients. *Childs Nerv Syst*. 2009 Jul;25(7):837-44. *University of California, San Diego, San Diego*

Fogliata A, Yartsev S, Nicolini G, Clivio A, Vanetti E, Wyttenbach R, Bauman G, Cozzi L. On the performances of Intensity Modulated Protons, RapidArc and Helical Tomotherapy for selected paediatric cases. *Radiat Oncol.* 2009 Jan 14;4:2. *Oncology Institute of Southern Switzerland, Bellinzona, SZ*

Buis DR, Dirven CM, Lagerwaard FJ, Mandl ES, Lycklama Ã Nijeholt GJ, Eshghi DS, van den Berg R, Baayen JC, Meijer OW, Slotman BJ, Vandertop WP. Radiosurgery of brain arteriovenous malformations in children. *J Neurol.* 2008 Apr;255(4):551-60.*VU University Medical Center, Amsterdam*

Lo SS, Fakiris AJ, Abdulrahman R, Henderson MA, Chang EL, Suh JH, Timmerman RD. Role of stereotactic radiosurgery and fractionated stereotactic radiotherapy in pediatric brain tumors. *Expert Rev Neurother.* 2008 Jan;8(1):121-32. Review. *Ohio State University Medical Center, Columbus, OH*

Han SR, Yoon SW, Yee GT, Choi CY, Sohn MJ, Lee DJ, Whang CJ. Novalis radiosurgery of optic gliomas in children: preliminary report. *Pediatr Neurosurg*. 2007;43(4):251-7. *Inje University, Goyang, KR*

Loeffler JS, Rossitch E Jr, Siddon R, Moore MR, Rockoff MA, Alexander E 3rd. Role of stereotactic radiosurgery with a linear accelerator in treatment of intracranial arteriovenous malformations and tumors in children. *Pediatrics*. 1990 May;85(5):774-82. *Children's Hospital, Boston*

Benk V, Clark BG, Souhami L, Algan O, Bahary J, Podgorsak EB, Freeman CR. Stereotactic radiation in primary brain tumors in children and adolescents. *Pediatr Neurosurg*. 1999 Aug;31(2):59-64. *McGill University, Montreal, Quebec*

BRAIN – FUNCTIONAL DISEASE

Trigeminal Neuralgia and other Pain [11]

Zahra H, Teh BS, Paulino AC, Yoshor D, Trask T, Baskin D, Butler EB. Stereotactic Radiosurgery for Trigeminal Neuralgia Utilizing the BrainLAB Novalis System. *Technol Cancer Res Treat.* 2009 Dec;8(6):407-12. Technol Cancer Res Treat. 2009 Dec;8(6):407-12. *Baylor College of Medicine, Houston*

Chen JC, Greathouse HE, Girvigian MR, Miller MJ, Liu A, Rahimian J. Prognostic factors for radiosurgery treatment of trigeminal neuralgia. *Neurosurgery*. 2008 May;62(5 Suppl):A53-61. *Southern California Permanente Medical Group and Kaiser Foundation, Los Angeles*

Pusztaszeri M, Villemure JG, Regli L, Do HP, Pica A. Radiosurgery for trigeminal neuralgia using a linear accelerator with BrainLab system: report on initial experience in Lausanne, Switzerland. *Swiss Med Wkly*. 2007 Dec 1;137(47-48):682-6. *Centre Hospitalier Universitaire Vaudois, Lausanne, SW*

Gorgulho AA, De Salles AA. Impact of radiosurgery on the surgical treatment of trigeminal neuralgia. *Surg Neurol.* 2006 Oct;66(4):350-6. *UCLA, Los Angeles*

Gorgulho A, De Salles AA, McArthur D, Agazaryan N, Medin P, Solberg T, Mattozo C, Ford J, Lee S, Selch MT. Brainstem and trigeminal nerve changes after radiosurgery for trigeminal pain. *Surg Neurol*. 2006 Aug;66(2):127-35; discussion 135., *UCLA, Los Angeles*

Chen JC, Girvigian M, Greathouse H, Miller M, Rahimian J. Treatment of trigeminal neuralgia with linear accelerator radiosurgery: initial results. *J Neurosurg.* 2004 Nov;101 Suppl 3:346-50. *Southern California Permanente Medical Group, Los Angeles*

Rahimian J, Chen JC, Rao AA, Girvigian MR, Miller MJ, Greathouse HE. Geometrical accuracy of the Novalis stereotactic radiosurgery system for trigeminal neuralgia. *J Neurosurg.* 2004 Nov;101 Suppl 3:351-5. *Southern California Permanente Medical Group, Los Angeles*

Frighetto L, De Salles AA, Smith ZA, Goss B, Selch M, Solberg T. Noninvasive linear accelerator radiosurgery as the primary treatment for trigeminal neuralgia. *Neurology*. 2004 Feb 24;62(4):660-2. *UCLA, Los Angeles*

Goss BW, Frighetto L, DeSalles AA, Smith Z, Solberg T, Selch M. Linear accelerator radiosurgery using 90 gray for essential trigeminal neuralgia: results and dose volume histogram analysis. *Neurosurgery*. 2003 Oct;53(4):823-8; discussion 828-30. *UCLA, Los Angeles*

De Salles AA, Frighetto L, Lacan G, Melega W. Radiosurgery can achieve precision needed for functional neurosurgery. *Arch Neurol.* 2003 Oct;60(10):1494-6. *UCLA, Los Angeles*

Smith ZA, De Salles AA, Frighetto L, Goss B, Lee SP, Selch M, Wallace RE, Cabatan-Awang C, Solberg T. Dedicated linear accelerator radiosurgery for the treatment of trigeminal neuralgia. *J Neurosurg*. 2003 Sep;99(3):511-6. *UCLA, Los Angeles*

BRAIN – FUNCTIONAL DISEASE

Arteriovenous Malformations and Cavernomas [23]

Yuki I, Kim RH, Duckwiler G, Jahan R, Tateshima S, Gonzalez N, Gorgulho A, Diaz JL, De Salles AA, Viñuela F. Treatment of brain arteriovenous malformations with high-flow arteriovenous fistulas: risk andcomplications associated with endovascular embolization in multimodality treatment. *J Neurosurg.* 2010 Oct;113(4):715-22.. *UCLA, Los Angeles, CA*

Raffa SJ, Chi YY, Bova FJ, Friedman WA. Validation of the radiosurgery-based arteriovenous malformation score in a large linear accelerator radiosurgery experience. *J Neurosurg.* 2009 Oct;111(4):832-9. *University of Florida, Gainesville*

Hamm KD, Klisch J, Surber G, Kleinert G, Eger C, Aschenbach R. Special aspects of diagnostic imaging for radiosurgery of arteriovenous malformations. *Neurosurgery*. 2008 May;62(5 Suppl):A44-52 *Helios Klinikum Erfurt, Erfurt, Germany*

Veznedaroglu E, Andrews DW, Benitez RP, Downes MB, Werner-Wasik M, Rosenstock J, Curran WJ Jr, Rosenwasser RH. Fractionated stereotactic radiotherapy for the treatment of large arteriovenous malformations with or without previous partial embolization. *Neurosurgery*. 2008 Feb;62 Suppl 2:519-31. *Thomas Jefferson Hospital, Philadelphia*

Moreno-Jimenez S, Celis MA, Larraga-Gutierrez JM, Suarez-Campos Jde J, Garcia-Garduño A, Hernandez-Bojorquez M, Gutiérrez-Aceves GA. Intracranial arteriovenous malformations treated with LINAC-based conformal radiosurgery: validation of the radiosurgery-based arteriovenous malformation score as a predictor of outcome. *Neurol Res.* 2007 Oct;29(7):712-6. *Instituto Nacional de Neurología y Neurocirugía, Tlalpan, México*

Hsu PW, Chang CN, Tseng CK, Wei KC, Wang CC, Chuang CC, Huang YC. Treatment of epileptogenic cavernomas: surgery versus radiosurgery. *Cerebrovasc Dis.* 2007;24(1):116-20, *Chang Gung Memorial Hospital, Tao Yuan, Taiwan, ROC*

Jahan R, Solberg TD, Lee D, Medin P, Tateshima S, De Salles A, Sayre J, Vinters HV, Vinuela F. An arteriovenous malformation model for stereotactic radiosurgery research. *Neurosurgery*. 2007 Jul;61(1):152-9; *UCLA, Los Angeles*

Moreno-Jimenez S, Celis MA, Larraga-Gutierrez JM, de Jesus Suarez-Campos J, Garcia-Garduno A, Hernandez-Bojorquez M. Intracranial arteriovenous malformations treated with linear accelerator-based conformal radiosurgery: clinical outcome and prediction of obliteration. *Surg Neurol*. 2007 May;67(5):487-91; discussion 491-2. *National Institute of Neurology and Neurosurgery, Mexico City, MX*

Cover KS, Lagerwaard FJ, van den Berg R, Buis DR, Slotman BJ. Color intensity projection of digitally subtracted angiography for the visualization of brain arteriovenous malformations. *Neurosurgery*. 2007 Mar;60(3):511-4; discussion 514-5.*VU University Medical Center, Amsterdam*

Buis DR, Lagerwaard FJ, Dirven CM, Barkhof F, Knol DL, van den Berg R, Slotman BJ, Vandertop WP. Delineation of brain AVMs on MR-Angiography for the purpose of stereotactic radiosurgery. *Int J Radiat Oncol Biol Phys.* 2007 Jan 1;67(1):308-16. *VU University Medical Center, Amsterdam*

Huang YC, Tseng CK, Chang CN, Wei KC, Liao CC, Hsu PW. LINAC radiosurgery for intracranial cavernous malformation: 10-year experience. *Clin Neurol Neurosurg.* 2006 Dec;108(8):750-6 *Chang Gung Memorial Hospital, Tao Yuan, Taiwan, ROC*

Moreno-Jiménez S, Celis-López MA, Lárraga-Gutiérrez JM, Herrera-Gómez L, Suárez-Campos JJ, García- Garduño A, Hernández-Bojórquez M. [Intracranial arteriovenous malformations and radiosurgery with LINAC: review article] *Neurocirugia (Astur).* 2006 Aug;17(4):317-23, *Instituto Nacional de Neurología y Neurocirugía MVS, México*

Perks JR, Yang C, Sahrakar K, Pappas C, Hartman J, Kubo H, Chen A. Linear accelerator-based radiosurgery for multiple arteriovenous malformations: case report. *Am J Neuroradiol*. 2005 Aug;26(7):1852-4. *UC Davis Medical Center, Sacramento*

Buis DR, Lagerwaard FJ, Barkhof F, Dirven CM, Lycklama GJ, Meijer OW, van den Berg R, Langendijk HA, Slotman BJ, Vandertop WP. Stereotactic radiosurgery for brain AVMs: role of interobserver variation in target definition on digital subtraction angiography. *Int J Radiat Oncol Biol Phys.* 2005 May 1;62(1):246-52. *VU University Medical Center, Amsterdam*

Scarbrough TJ, Crocker IR, Davis LW, Barro DL, Fowler BZ, Oyesiku NM. Intracranial arteriovenous malformations treated utilizing a linear accelerator-based patient rotator or commercially available radiosurgery system. *Stereotact Funct Neurosurg*. 2005;83(2-3):91-100. *Emory University, Atlanta*

Pedroso AG, De Salles AA, Tajik K, Golish R, Smith Z, Frighetto L, Solberg T, Cabatan-Awang C, Selch MT. Novalis Shaped Beam Radiosurgery of arteriovenous malformations. *J Neurosurg.* 2004 Nov;101 Suppl 3:425-34. *UCLA, Los Angeles*

Zipfel GJ, Bradshaw P, Bova FJ, Friedman WA. Do the morphological characteristics of arteriovenous malformations affect the results of radiosurgery? *J Neurosurg*. 2004 Sep;101(3):393-401. *University of Florida, Gainesville*

Friedman_WA. LINAC radiosurgery for arteriovenous malformations, *Operative Techniques in Neurosurgery*, 6(2) (June), 2003: 83-88, *University of Florida, Gainesville*

Friedman WA, Bova FJ, Bollampally S, Bradshaw P. Analysis of factors predictive of success or complications in arteriovenous malformation radiosurgery. *Neurosurgery*. 2003 Feb;52(2):296-307; discussion 307-8. *University of Florida, Gainesville*

Mobin F, De Salles AA, Abdelaziz O, Cabatan-Awang C, Solberg T, Selch . Stereotactic radiosurgery of cerebral arteriovenous malformations: appearance of perinidal T(2) hyperintensity signal as a predictor of favorable treatment response. *Stereotact Funct Neurosurg*. 1999;73(1-4):50-9. *UCLA, Los Angeles, CA*

Friedman WA, Blatt DL, Bova FJ, Buatti JM, Mendenhall WM, Kubilis PS. The risk of hemorrhage after radiosurgery for arteriovenous malformations. *J Neurosurg*. 1996 Jun;84(6):912-9. *University of Florida, Gainesville.*

Friedman WA, Bova FJ, Mendenhall WM. Linear accelerator radiosurgery for arteriovenous malformations: the relationship of size to outcome. *J Neurosurg.* 1995 Feb;82(2):180-9. *University of Florida, Gainesville.*

Friedman WA, Bova FJ. Linear accelerator radiosurgery for arteriovenous malformations. *J Neurosurg.* 1992 Dec;77(6):832-41. *University of Florida, Gainesville, University of Florida, Gainesville*

BRAIN – FUNCTIONAL DISEASE

BRAIN – Seizure Treatment: Thalamotomy & Corpus Callosotomy [4]

Golanov AV, Kornienko VN, Trunin IuIu, Kostiuchenko VV, Gorlachev GE, Gorelyshev SK, Melikian AG, Khukhlaeva EA, Mazerkina NA, Sorokin VA. [Stereotactic radiosurgery in treatment of patients with hypothalamic hamartomas] *Zh Vopr Neirokhir Im N N Burdenko.* 2010 Jan-Mar;(1):24-9.

Celis MA, Moreno-Jimenez S, Larraga-Gutierrez JM, Alonso-Vanegas MA, Garcia-Garduno OA, Martinez- Juarez IE, Fernandez-Gonzalez MC. Corpus callosotomy using conformal stereotactic radiosurgery. *Childs Nerv Syst.* 2007 Aug;23(8):917-20. *Instituto Nacional de Neurología y Neurocirugía, Tlalpan, México*

Selch MT, Gorgulho A, Mattozo C, Solberg TD, Cabatan-Awang C, DeSalles AA. Linear accelerator stereotactic radiosurgery for the treatment of gelastic seizures due to hypothalamic hamartoma. *Minim Invasive Neurosurg*. 2005 Oct;48(5):310-4. *UCLA, Los Angeles*

Frighetto L, De Salles A, Wallace R, Ford J, Selch M, Cabatan-Awang C, Solberg T. Linear accelerator thalamotomy. *Surg Neurol*. 2004 Aug;62(2):106-13; discussion 113-4. *UCLA, Los Angeles*

SPINE

Spine – Metatatic Spinal Disease, Primary Spine Tumors, Vascular Spine Disease

Sahgal A, Bilsky M, Chang EL, Ma L, Yamada Y, Rhines LD, Létourneau D, Foote M, Yu E, Larson DA, Fehlings MG. Stereotactic body radiotherapy for spinal metastases: current status, with a focus on its application in the postoperative patient. *J Neurosurg Spine*. 2010 Dec 24. *Princess Margaret Hospital;* [Epub ahead of print]

Damast S, Wright J, Bilsky M, Hsu M, Zhang Z, Lovelock M, Cox B, Zatcky J, Yamada Y Impact of Dose on Local Failure Rates after Image-Guided Reirradiation of Recurrent Paraspinal Metastases. *Int J Radiat Oncol Biol Phys.* 2010 Sep 30. *Memorial Sloan-Kettering Cancer Center, NY* [Epub ahead of print]

Ma L, Sahgal A, Cozzi L, Chang E, Shiu A, Letourneau D, Yin FF, Fogliata A, Kaissl W, Hyde D, Laperriere NJ, Shrieve DC, Larson DA. Apparatus-dependent dosimetric differences in spine stereotactic body radiotherapy. *Technol Cancer Res Treat.* 2010 Dec;9(6):563-74. *University of California San Francisco, San Francisco*

Harel R, Angelov L. Spine metastases: Current treatments and future directions. *Eur J Cancer.* 2010 Oct;46(15):2696-707.*Cleveland Clinic Foundation, Cleveland, OH*

Moulding HD, Elder JB, Lis E, Lovelock DM, Zhang Z, Yamada Y, Bilsky MH. Local disease control after decompressive surgery and adjuvant high-dose single-fraction radiosurgery for spine metastases. *J Neurosurg Spine.* 2010 Jul;13(1):87-93. *Memorial Hospital for Cancer and the Allied Diseases, New York*

Zhang P, Happersett L, Yang Y, Yamada Y, Mageras G, Hunt M. Optimization of collimator trajectory in volumetric modulated arc therapy: development and evaluation for paraspinal SBRT. *Int J Radiat Oncol Biol Phys.* 2010 Jun 1;77(2):591-9. *Memorial Sloan-Kettering Cancer Center, New York, NY*

Sahgal A, Ma L, Gibbs I, Gerszten PC, Ryu S, Soltys S, Weinberg V, Wong S, Chang E, Fowler J, Larson DA. Spinal Cord Tolerance for Stereotactic Body Radiotherapy. *Int J Radiat Oncol Biol Phys.* 2010 Jun 1;77(2):548-53. *includes Henry Ford Hospital and MD Anderson Cancer Center*

Ryu S, Rock J, Jain R, Lu M, Anderson J, Jin JY, Rosenblum M, Movsas B, Kim JH. Radiosurgical decompression of metastatic epidural compression. *Cancer*. 2010 May 1;116(9):2250-7. *Henry Ford Hospital, Detroit*

Chang Z, Wang Z, Ma J, O'Daniel JC, Kirkpatrick J, Yin FF. 6D image guidance for spinal non-invasive stereotactic body radiation therapy: Comparison between ExacTrac X-ray 6D with kilo-voltage cone-beam CT. *Radiother Oncol.* 2010 Apr;95(1):116-21 *Duke University Medical Center, Durham, NC*

Itshayek E, Yamada J, Bilsky M, Schmidt M, Shaffrey C, Gerszten P, Polly D, Gokaslan Z, Varga PP, Fisher CG. Timing of surgery and radiotherapy in the management of metastatic spine disease: a systematic review. *Int J Oncol.* 2010 Mar;36(3):533-44. Review. *Hadassah University Hospital, Jerusalem,*

Kirkpatrick JP, van der Kogel AJ, Schultheiss TE Radiation dose-volume effects in the spinal cord. *Int J Radiat Oncol Biol Phys*. 2010 Mar 1;76(3 Suppl):S42-9. Review. *Duke University Medical Center, Durham*

Lo SS, Sahgal A, Wang JZ, Mayr NA, Sloan A, Mendel E, Chang EL. Stereotactic body radiation therapy for spinal metastases. *Discov Med.* 2010 Apr;9(47):289-96 *Ohio State University, Columbus, OH*

Nguyen QN, Shiu AS, Rhines LD, Wang H, Allen PK, Wang XS, Chang EL. Management of Spinal Metastases from Renal Cell Carcinoma Using Stereotactic Body Radiotherapy. *Int J Radiat Oncol Biol Phys.* 2010 Mar 15;76(4):1185-92. *MD Anderson Cancer Center, Houston*

Kuijper IT, Dahele M, Senan S, Verbakel WF. Volumetric modulated arc therapy versus conventional intensity modulated radiation therapy for stereotactic spine radiotherapy: a planning study and early clinical data. *Radiother Oncol.* 2010 Feb;94(2):224-8. *VU University Medical Center, Amsterdam,*

Selch MT, Lin K, Agazaryan N, Tenn S, Gorgulho A, Demarco JJ, Desalles AA. Initial clinical experience with image-guided linear accelerator-based spinal radiosurgery for treatment of benign nerve sheath tumors. *Surg Neurol.* 2009 Dec;72(6):668-74; discussion 674-5. *UCLA, Los Angeles*

Wu QJ, Yoo S, Kirkpatrick JP, Thongphiew D, Yin FF. Volumetric arc intensity-modulated therapy for spine body radiotherapy: comparison with static intensity-modulated treatment. *Int J Radiat Oncol Biol Phys*. 2009 Dec 1;75(5):1596-604, *Duke University Center, Durham*.

Shin DA, Huh R, Chung SS, Rock J, Ryu S. Stereotactic spine radiosurgery for intradural and intramedullary metastasis. *Neurosurg Focus*. 2009 Dec;27(6):E10. *Henry Ford Hospital*

Li S, Liu Y, Chen Q, Jin J. Cord dose specification and validation for stereotactic body radiosurgery of spine. *Med Dosim.* 2009 Winter;34(4):285-92. *Henry Ford Hospital, Detroit*

Parikh S, Heron DE. Fractionated radiosurgical management of intramedullary spinal cord metastasis: A case report and review of the literature. *Clin Neurol Neurosurg*. 2009 Dec;111(10):858-61. *University of Pittsburgh Medical Center, Pittsburgh*

Chawla S, Abu-Aita R, Philip A, Lundquist T, Okunieff P, Milano MT. Stereotactic Radiosurgery for Spinal Metastases: Case Report and Review Of Treatment Options. *Bone*. 2009 Oct;45(4):817-21. *University of Rochester Medical Center, Rochester, NY*

Sohn MJ, Lee DJ, Jeon SR, Khang SK. Spinal radiosurgical treatment for thoracic epidural cavernous hemangioma presenting as radiculomyelopathy: technical case report. *Neurosurgery*. 2009 Jun;64(6):E1202-3, *Inje University Ilsan Paik Hospital, Goyang City, Korea*

Sohn MJ, Lee DJ, Yoon SW, Lee HR, Hwang YJ. The effective application of segmental image fusion in spinal radiosurgery for improved targeting of spinal tumours. *Acta Neurochir (Wien*) 2009 Mar;151(3):231-8, *Inje University Ilsan Paik Hospital, Goyang City, Korea*

Nelson JW, Yoo DS, Sampson JH, Isaacs RE, Larrier NA, Marks LB, Yin FF, Wu QJ, Wang Z, Kirkpatrick JP.Stereotactic body radiotherapy for lesions of the spine and paraspinal regions. *Int J Radiat Oncol Biol Phys*. 2009 Apr 1;73(5):1369-75. *Duke University Center, Durham*

Wu AJ, Bilsky MH, Edgar MA, Yamada Y. Near-complete pathological response of chordoma to high-dose single-fraction radiotherapy: case report. *Neurosurgery*. 2009 Feb;64(2):E389-90. *Memorial Sloan-Kettering Cancer Center, New York*

Zeman RJ, Wen X, Ouyang N, Rocchio R, Shih L, Alfieri A, Moorthy C, Etlinger JD. Stereotactic Radiosurgery Improves Locomotor Recovery after Spinal Cord Injury in Rats. *Neurosurgery*. 2008 Nov;63(5):981- 988. *Westchester Medical Center / NY Medical College,Valhalla*

Kriminski SA, Lovelock DM, Seshan VE, Ali I, Munro P, Amols HI, Fuks Z, Bilsky M, Yamada Y. Comparison of kilovoltage cone-beam computed tomography with megavoltage projection pairs for paraspinal radiosurgery patient alignment and position verification. *Int J Radiat Oncol Biol Phys.* 2008 Aug 1;71(5):1572-80. *Memorial Sloan-Kettering Cancer Center, New York* Yamada Y, Bilsky MH, Lovelock DM, Venkatraman ES, Toner S, Johnson J, Zatcky J, Zelefsky MJ, Fuks Z.

High-dose, single-fraction image-guided intensity-modulated radiotherapy for metastatic spinal lesions. *Int J Radiat Oncol Biol Phys.* 2008 Jun 1;71(2):484-90. *Memorial Sloan-Kettering Cancer Center, New York*

Watchman CJ, Hamilton RJ, Stea B, Mignault AJ. Patient positioning using implanted gold markers with the novalis body system in the thoracic spine. *Neurosurgery*. 2008 May;62(5 Suppl):A62-8; *University of Arizona, Tucson*

Jin JY, Ryu S, Rock J, Faber K, Chen Q, Ajlouni M, Movsas B. Evaluation of residual patient position variation for spinal radiosurgery using the Novalis image guided system. *Med Phys.* 2008 Mar;35(3):1087-93, *Henry Ford Hospital, Detroit*

Agazaryan N, Tenn SE, Desalles AA, Selch MT. Image-guided radiosurgery for spinal tumors: methods, accuracy and patient intrafraction motion. *Phys Med Biol.* 2008 Mar 21;53(6):1715-27. *UCLA, Los Angeles*

Ryu S, Jin R, Jin JY, Chen Q, Rock J, Anderson J, Movsas B. Pain Control by Image-Guided Radiosurgery for Solitary Spinal Metastasis., *J Pain Symptom Manage*. 2008 Mar;35(3):292-8. *Henry Ford Hospital, Detroit*

Finn MA, Vrionis FD, Schmidt MH. Spinal radiosurgery for metastatic disease of the spine. *Cancer Control.* 2007 Oct;14(4):405-11. *Univ of Utah, Salt Lake City*

Yamada Y, Lovelock DM, Bilsky MH. A Review of Image-Guided Intensity-Modulated Radiotherapy for Spinal Tumors. *Neurosurgery*. 2007 Aug;61(2):226-235, *Memorial Sloan-Kettering Cancer Center, New York*

Chang EL, Shiu AS, Mendel E, Mathews LA, Mahajan A, Allen PK, Weinberg JS, Brown BW, Wang XS, Woo SY, Cleeland C, Maor MH, Rhines LD Phase I/II study of stereotactic body radiotherapy for spinal metastasis and its pattern of failure. *J Neurosurg Spine*. 2007 Aug;7(2):151-60, *University of Texas M. D. Anderson Cancer Center, Houston*

Wang C, Shiu A, Lii M, Woo S, Chang EL. Automatic target localization and verification for on-line imageguided stereotactic body radiotherapy of the spine. *Technol Cancer Res Treat.* 2007 Jun;6(3):187-96. *M. D. Anderson Cancer Center, Houston*

Jin JY, Chen Q, Jin R, Rock J, Anderson J, Li S, Movsas B, Ryu S. Technical and clinical experience with spine radiosurgery: a new technology for management of localized spine metastases. *Technol Cancer Res Treat*. 2007 Apr;6(2):127-33. *Henry Ford Hospital, Detroit*

Ryu S, Jin JY, Jin R, Rock J, Ajlouni M, Movsas B, Rosenblum M, Kim JH. Partial volume tolerance of the spinal cord and complications of single-dose radiosurgery. *Cancer*. 2007 Feb 1;109(3):628-36. *Henry Ford Hospital, Detroit*

Yamada Y, Lovelock M, Bilsky MH. Image-guided intensity-modulated radiation therapy of spine tumors. *Curr Neurol Neurosci Rep*. 2006 May;6(3):207-11. *Memorial Sloan-Kettering Cancer Center, New York*

Rock JP, Ryu S, Shukairy MS, Yin FF, Sharif A, Schreiber F, Abdulhak M, Kim JH, Rosenblum ML. Postoperative radiosurgery for malignant spinal tumors. *Neurosurgery*. 2006 May;58(5):891-8; discussion 891-8. *Henry Ford Hospital, Detroit*

Yin FF, Ryu S, Ajlouni M, Yan H, Jin JY, Lee SW, Kim J, Rock J, Rosenblum M, Kim JH. Image-guided procedures for intensity-modulated spinal radiosurgery. Technical note. *J Neurosurg.* 2004 Nov;101 Suppl 3:419-24. *Henry Ford Hospital, Detroit*

Bilsky MH, Yamada Y, Yenice KM, Lovelock M, Hunt M, Gutin PH, Leibel SA. Intensity-modulated stereotactic radiotherapy of paraspinal tumors: a preliminary report. *Neurosurgery*. 2004 Apr;54(4):823-30; discussion 830-1. *Memorial Sloan-Kettering, New York.*

Ryu S, Rock J, Rosenblum M, Kim JH. Patterns of failure after single-dose radiosurgery for spinal metastasis. *J Neurosurg*. 2004 Nov;101 Suppl 3:402-5. *Henry Ford Hospital, Detroit*

Benzil DL, Saboori M, Mogilner AY, Rocchio R, Moorthy CR. Safety and efficacy of stereotactic radiosurgery for tumors of the spine. *J Neurosurg.* 2004 Nov;101 Suppl 3:413-418. *New York Med College, Valhalla, NY*

Yin FF, Ryu S, Ajlouni M, Yan H, Jin JY, Lee SW, Kim J, Rock J, Rosenblum M, Kim JH. Image-guided procedures for intensity-modulated spinal radiosurgery. Technical note. *J Neurosurg.* 2004 Nov;101 Suppl 3:419-24. *Henry Ford Hospital, Detroit*

De Salles AA, Pedroso AG, Medin P, Agazaryan N, Solberg T, Cabatan-Awang C, Espinosa DM, Ford J, Selch MT. Spinal lesions treated with Novalis shaped beam intensity-modulated radiosurgery and stereotactic radiotherapy. *J Neurosurg.* 2004 Nov;101 Suppl 3:435-40 *UCLA, Los Angeles*

Rock JP, Ryu S, Yin FF. Novalis radiosurgery for metastatic spine tumors. *Neurosurg Clin N Am.* 2004 Oct;15(4):503-9. *Henry Ford Hospital, Detroit*

Rock JP, Ryu S, Yin FF, Schreiber F, Abdulhak M. The evolving role of stereotactic radiosurgery and stereotactic radiation therapy for patients with spine tumors. *J Neurooncol*. 2004 Aug-Sep;69(1-3):319-34. *Henry Ford Hospital, Detroit*

Bilsky MH, Yamada Y, Yenice KM, Lovelock M, Hunt M, Gutin PH, Leibel SA. Intensity-modulated stereotactic radiotherapy of paraspinal tumors: a preliminary report. *Neurosurgery*. 2004 Apr;54(4):823-30; discussion 830-1. *Memorial Sloan-Kettering, New York.*

Shiu AS, Chang EL, Ye JS, Lii M, Rhines LD, Mendel E, Weinberg J, Singh S, Maor MH, Mohan R, Cox JD. Near simultaneous computed tomography image-guided stereotactic spinal radiotherapy: an emerging paradigm for achieving true stereotaxy. *Int J Radiat Oncol Biol Phys.* 2003 Nov 1;57(3):605-13. *MD Anderson Cancer Center, Houston*

Ryu S, Fang Yin F, Rock J, Zhu J, Chu A, Kagan E, Rogers L, Ajlouni M, Rosenblum M, Kim JH. Imageguided and intensity-modulated radiosurgery for patients with spinal metastasis. *Cancer*. 2003 Apr 15;97(8):2013-8. *Henry Ford Hospital, Detroit*

Yin FF, Ryu S, Ajlouni M, Zhu J, Yan H, Guan H, Faber K, Rock J, Abdalhak M, Rogers L, Rosenblum M, Kim JH. A technique of intensity-modulated radiosurgery (IMRS) for spinal tumors. *Med Phys*. 2002 Dec;29(12):2815-22. *Henry Ford Hospital, Detroit*

Rock J, Kole M, Yin FF, Ryu S, Guttierez J, Rosenblum M. Radiosurgical treatment for Ewing's sarcoma of the lumbar spine: case report. *Spine*. 2002 Nov 1;27(21):E471-5. *Henry Ford Hospital, Detroit*

Medin PM, Solberg TD, De Salles AA, Cagnon CH, Selch MT, Johnson JP, Smathers JB, Cosman ER. Investigations of a minimally invasive method for treatment of spinal malignancies with LINAC stereotactic radiation therapy: accuracy and animal studies. *Int J Radiat Oncol Biol Phys.* 2002 Mar 15;52(4):1111-22. *UCLA, Los Angeles*

Ryken TC, Meeks SL, Traynelis V, Haller J, Bouchet LG, Bova FJ, Pennington EC, Buatti JM. Ultrasonographic guidance for spinal extracranial radiosurgery: technique and application for metastatic spinal lesions. *Neurosurg Focus.* 2001 Dec 15;11(6):e8. *University of Florida, Gainesville*

Bilsky MH, Yenice K, Lovelock M, Yamada J. Stereotactic intensity-modulation radiation therapy for vertebral body and paraspinal tumors. *Neurosurg Focus*. 2001 Dec 15;11(6):e7. *Memorial Sloan-Kettering Cancer Center, New York*

H&N-EENT & Skull Base

Non-CNS Tumors of the Orbt and Head & Neck

Rwigema JC, Heron DE, Ferris RL, Andrade RS, Gibson MK, Yang Y, Ozhasoglu C, Argiris AE, Grandis JR, Burton SA. The Impact of Tumor Volume and Radiotherapy Dose on Outcome in Previously Irradiated Recurrent Squamous Cell Carcinoma of the Head and Neck Treated With Stereotactic Body Radiation Therapy. *Am J Clin Oncol.* 2010 Sep 20. *University of Pittsburgh Cancer Institute, Pittsburgh, PA* [Epub ahead of print]

Heron DE, Rwigema JC, Gibson MK, Burton SA, Quinn AE, Ferris RL. Concurrent Cetuximab With Stereotactic Body Radiotherapy for Recurrent Squamous Cell Carcinoma of the Head and Neck: A Single Institution Matched Case-Control Study. *Am J Clin Oncol.* 2010 Aug 3. *University of Pittsburgh Cancer Institute, Pittsburgh, PA* [Epub ahead of print]

Kan MW, Cheung JY, Leung LH, Lau BM, Yu PK. The accuracy of dose calculations by anisotropic analytical algorithms for stereotactic radiotherapy in nasopharyngeal carcinoma. *Phys Med Biol.* 2010 Dec 22;56(2):397-413. *Princess Margaret Hospital, Hong Kong SAR, People's Republic of China.*

Heron DE, Ferris RL, Karamouzis M, Andrade RS, Deeb EL, Burton S, Gooding WE, Branstetter BF, Mountz JM, Johnson JT, Argiris A, Grandis JR, Lai SY. Stereotactic Body Radiotherapy for Recurrent Squamous Cell Carcinoma of the Head and Neck: Results of a Phase I Dose-Escalation Trial. *Int J Radiat Oncol Biol Phys.* 2009 Dec 1;75(5):1493-500. *University of Pittsburgh, Pittsburgh, PA*

Heron DE. Stereotactic body radiation therapy for recurrent head & neck cancers: rethi nking nonoperative salvage strategies. *Future Oncol*. 2009 Nov;5(9):1321-5, *UPMC Medical Center, Pittsburgh, PA*

Verbakel WF, Cuijpers JP, Hoffmans D, Bieker M, Slotman BJ, Senan S. Volumetric intensity-modulated arc therapy vs. conventional IMRT in head-and-neck cancer: a comparative planning and dosimetric study. *Int J Radiat Oncol Biol Phys.* 2009 May 1;74(1):252-9. *VU University Medical Center, Amsterdam, The Netherlands.*

Siddiqui F, Patel M, Khan M, McLean S, Dragovic J, Jin JY, Movsas B, Ryu S. Stereotactic Body Radiation Therapy for Primary, Recurrent, and Metastatic Tumors in the Head-and-Neck Region. *Int J Radiat Oncol Biol Phys.* 2009 Jul 15;74(4):1047-53 *Henry Ford Health System, Detroit, MI*

Gagne IM, Ansbacher W, Zavgorodni S, Popescu C, Beckham WA. A Monte Carlo evaluation of RapidArc dose calculations for oropharynx radiotherapy. *Phys Med Biol.* 2008 Dec 21;53(24):7167-85. *BC Cancer Agency-Vancouver Island Centre, Victoria, British Columbia, Canada*.

Kim GY, Pawlicki T, Le QT, Luxton G. Linac-based on-board imaging feasibility and the dosimetric consequences of head roll in head-and-neck IMRT plans. *Med Dosim*. 2008 Spring;33(1):93-9. *Stanford University Medical Center, Palo Alto*

Wu SX, Chua DT, Deng ML, Zhao C, Li FY, Sham JS, Wang HY, Bao Y, Gao YH, Zeng ZF. Outcome of fractionated stereotactic radiotherapy for 90 patients with locally persistent and recurrent nasopharyngeal carcinoma. *Int J Radiat Oncol Biol Phys.* 2007 Nov 1;69(3):761-9. *Duke University Medical Center, Raleigh- Durham*

Miralbell R, Caro M, Weber DC, Elizalde J, Perez-Ochoa A, Villà S, IgnacioToscas J, Martinez P, Linero D, Nouet P, Escudé L. Stereotactic Radiotherapy for Ocular Melanoma: Initial Experience Using Closed Eyes For Ocular Target Immobilization, *Technol Cancer Res Treat.* Oct 2007;6(5):361-588), *Instituto Oncológico Teknon, Barcelona, SP*

Lawson JD, Elder E, Fox T, Davis L, Crocker I. Quantification of dosimetric impact of implementation of onboard imaging (OBI) for IMRT treatment of head-and-neck malignancies. *Med Dosim*. 2007 Winter; 32(4):287-94. *Emory University, Atlanta*

Henderson MA, Shirazi H, Lo SS, Mendonca MS, Fakiris AJ, Witt TC, Worth RM, Timmerman RD. Stereotactic radiosurgery and fractionated stereotactic radiotherapy in the treatment of uveal melanoma. *Technol Cancer Res Treat*. 2006 Aug;5(4):411-9. *University of Texas Southwestern Medical Center, Dallas*

Poznanovic SA, Cass SP, Kavanagh BD., Short-term tumor control and acute toxicity after stereotactic radiosurgery for glomus jugulare tumors. *Otolaryngol Head Neck Surg.* 2006 Mar;134(3):437-42. *University of Colorado Health Sciences Center, Aurora*

Linthout N, Verellen D, Tournel K, Storme G. Six dimensional analysis with daily stereoscopic x-ray imaging of intrafraction patient motion in head and neck treatments using five points fixation masks. *Med Phys*. 2006 Feb;33(2):504-13. *Academic Hospital-Free University, Brussels*

Ernst-Stecken A, Lambrecht U, Ganslandt O, Mueller R, Fahlbusch R, Sauer R, Grabenbauer G. Radiosurgery of small skull-base lesions. No advantage for intensity-modulated stereotactic radiosurgery versus conformal arc technique. *Strahlenther Onkol.* 2005 May;181(5):336-44. *University of Erlangen-Nuremberg, Erlangen, DE.*

Saarilahti K, Kouri M, Collan J, Hamalainen T, Atula T, Joensuu H, Tenhunen M. Intensity modulated radiotherapyfor head and neck cancer: evidence for preserved salivary gland function. *Radiother Oncol.* 2005 Mar;74(3):251-8. *Helsinki University Central Hospital*

Ryu S, Khan M, Yin FF, Concus A, Ajlouni M, Benninger MS, Kim JH. Image-guided radiosurgery of head and neck cancers. *Otolaryngol Head Neck Surg*. 2004 Jun;130(6):690-7. *Henry Ford Hospital*

Nakamura JL, Pirzkall A, Carol MP, Xia P, Smith V, Wara WM, Petti PL, Verhey LJ, Sneed PK. Comparison of intensity-modulated radiosurgery with gamma knife radiosurgery for challenging skull base lesions. *Int J Radiat Oncol Biol Phys.* 2003 Jan 1;55(1):99-109. *UCSF, San Francisco*

Linthout N, Verellen D, Van Acker S, Voordeckers M, Bretz A, Storme G. Evaluation of dose calculation algorithms for dynamic arc treatments of head and neck tumors. *Radiother Oncol*. 2002 Jul;64(1):85-95. *Academic Hospital, Free University Brussels, BE*

Fiveash JB, Murshed H, Duan J, Hyatt M, Caranto J, Bonner JA, Popple RA. Effect of multileaf collimator leaf width on physical dose distributions in the treatment of CNS and head and neck neoplasms with intensity modulated radiation therapy. *Med Phys.* 2002 Jun;29(6):1116-9. *University of Alabama-Birmingham* Feigenberg SJ, Mendenhall WM, Hinerman RW, Amdur RJ, Friedman WA, Antonelli PJ. Radiosurgery for paraganglioma of the temporal bone. *Head Neck*. 2002 Apr;24(4):384-9. *University of Florida, Gainesville*

LUNG

Primary and Metastatic Lung Lesions

Palma DA, van Sörnsen de Koste JR, Verbakel WF, Senan S. A new approach to quantifying lung damage after stereotactic body radiation therapy. *Acta Oncol.* 2010 Dec 21. *VU University Medical Center, Amsterdam, The Netherlands* [Epub ahead of print]

Palma D, Visser O, Lagerwaard FJ, Belderbos J, Slotman BJ, Senan S. Impact of Introducing Stereotactic Lung Radiotherapy for Elderly Patients With Stage I Non-Small-Cell Lung Cancer: A Population-Based Time-Trend Analysis. *J Clin Oncol.* 2010 Nov 1. *Vrije Universiteit University Medical Center, Amsterdam*, [Epub ahead of print]

Palma DA, Senan S, Haasbeek CJ, Verbakel WF, Vincent A, Lagerwaard F. Radiological and Clinical Pneumonitis after Stereotactic Lung Radiotherapy: A Matched Analysis of Three-dimensional Conformal and Volumetric-modulated Arc Therapy Techniques. *Int J Radiat Oncol Biol Phys.* 2010 Jun 26. *VU Medical Center, Amsterdam, The Netherlands* [Epub ahead of print]

Welsh J, Thomas J, Shah D, Allen PK, Wei X, Mitchell K, Gao S, Balter P, Komaki R, Chang JY. Obesity Increases the Risk of Chest Wall Pain from Thoracic Stereotactic Body Radiation Therapy. *Int J Radiat Oncol Biol Phys.* 2010 Jun 11. *The University of Texas M. D. Anderson Cancer Center, Houston, TX*. [Epub ahead of print]

Chi A, Tomé WA, Fowler J, Komaki R, Nguyen NP, Mehta MP, Welsh JS Stereotactic Body Radiation Therapy in Non-Small-Cell Lung Cancer: Linking Radiobiological Modeling and Clinical Outcome. *Am J Clin Oncol*. 2010 Jun 9. *University of Arizona, Tucson, AZ* [Epub ahead of print]

Chen F, Matsuo Y, Yoshizawa A, Sato T, Sakai H, Bando T, Okubo K, Shibuya K, Date H. Salvage lung resection for non-small cell lung cancer after stereotactic body radiotherapy in initially operable patients. *J Thorac Oncol*. 2010 Dec;5(12):1999-2002. *Kyoto University, Kyoto, Japan.*

Kelly P, Balter PA, Rebueno N, Sharp HJ, Liao Z, Komaki R, Chang JY. Stereotactic body radiation therapy for patients with lung cancer previously treated with thoracic radiation. *Int J Radiat Oncol Biol Phys.* 2010 Dec 1;78(5):1387-93. *The University of Texas M. D. Anderson Cancer Center, Houston*

Palma D, Senan S. Stereotactic radiation therapy: changing treatment paradigms for stage I nonsmall cell lung cancer. *Curr Opin Oncol.* 2010 Nov 22. *University of Western Ontario, London, Ontario & VUMC* [Epub ahead of print]

Ong CL, Verbakel WF, Cuijpers JP, Slotman BJ, Lagerwaard FJ, Senan S. Stereotactic radiotherapy for peripheral lung tumors: a comparison of volumetric modulated arc therapy with 3 other delivery techniques. *Radiother Oncol.* 2010 Dec;97(3):437-42. *VU University Medical Center, Amsterdam, The Netherlands*

De Ruysscher D, Faivre-Finn C, Nestle U, Hurkmans CW, Le Péchoux C, Price A, Senan S. European organization for research and treatment of cancer recommendations for planning and delivery of high-dose, high-precision radiotherapy for lung cancer. *J Clin Oncol.* 2010 Dec 20;28(36):5301-10, *Maastricht University Medical Center, Maastricht, the Netherlands & Others*

Kelly P, Balter PA, Rebueno N, Sharp HJ, Liao Z, Komaki R, Chang JY. Stereotactic Body Radiation Therapy for Patients with Lung Cancer Previously Treated with Thoracic Radiation. *Int J Radiat Oncol Biol Phys*. 2010 Dec 1;78(5):1387-93. *The University of Texas M. D. Anderson Cancer Center*, Houston

Burdick MJ, Stephans KL, Reddy CA, Djemil T, Srinivas SM, Videtic GM. Maximum standardized uptake value from staging FDG-PET/CT does not predict treatment outcome for early-stage non-small-cell lung cancer treated with stereotactic body radiotherapy. *Int J Radiat Oncol Biol Phys*. 2010 Nov 15;78(4):1033-9 *Cleveland Clinic, Cleveland, OH*

Baba F, Shibamoto Y, Ogino H, Murata R, Sugie C, Iwata H, Otsuka S, Kosaki K, Nagai A, Murai T, Miyakawa A. Clinical outcomes of stereotactic body radiotherapy for stage I non-small cell lung cancer using different doses depending on tumor size. *Radiat Oncol*. 2010 Sep 17;5(1):81. *Nagoya City University, Nagoya, JP*

Buyyounouski MK, Balter P, Lewis B, D'Ambrosio DJ, Dilling TJ, Miller RC, Schefter T, Tomé W, Harris EE, Price RA Jr, Konski AA, Wallner PE. Stereotactic body radiotherapy for early-stage non-small-cell lung cancer: report of the ASTRO Emerging Technology Committee. *Int J Radiat Oncol Biol Phys*. 2010 Sep 1;78(1):3-10. *Includes University of Colorado*

Crabtree TD, Denlinger CE, Meyers BF, El Naqa I, Zoole J, Krupnick AS, Kreisel D, Patterson GA, Bradley JD. Stereotactic body radiation therapy versus surgical resection for stage I non-small cell lung cancer. *J Thorac Cardiovasc Surg.* 2010 Aug;140(2):377-86. *Washington University School of Medicine, St. Louis, MO*

van Dam IE, van Sörnsen de Koste JR, Hanna GG, Muirhead R, Slotman BJ, Senan S. Improving target delineation on 4-dimensional CT scans in stage I NSCLC using a deformable registration tool. *Radiother Oncol.* 2010 Jul;96(1):67-72. *VU University Medical Center, Amsterdam,*

Trovo M, Linda A, El Naqa I, Javidan-Nejad C, Bradley J. Early and late lung radiographic injury following stereotactic body radiation therapy (SBRT). *Lung Cancer.* 2010 Jul;69(1):77-85. *Washington University Medical Center, St. Louis*

Robinson CG, Bradley JD. The Treatment of Early-Stage Disease. *Semin Radiat Oncol.* 2010 Jul;20(3):178- 185. *Washington University School of Medicine. St. Louis*

Huang L, Park K, Boike T, Lee P, Papiez L, Solberg T, Ding C, Timmerman RD A study on the dosimetric accuracy of treatment planning for stereotactic body radiation therapy of lung cancer using average and maximum intensity

projection images. *Radiother Oncol.* 2010 Jul;96(1):48-54. *The University of Texas Southwestern Medical Center, Dallas*

Bradley JD, El Naqa I, Drzymala RE, Trovo M, Jones G, Denning MD. Stereotactic body radiation therapy for early-stage non-small-cell lung cancer: the pattern of failure is distant. *Int J Radiat Oncol Biol Phys.* 2010 Jul 15;77(4):1146-50 *Washington University School of Medicine, St. Louis, MO*

Videtic GM, Stephans K, Reddy C, Gajdos S, Kolar M, Clouser E, Djemil T. Intensity-modulated radiotherapy- based stereotactic body radiotherapy for medically inoperable early-stage lung cancer: excellent local control. *Int J Radiat Oncol Biol Phys.* 2010 Jun 1;77(2):344-9. *Cleveland Clinic Foundation, Cleveland*

Das M, Abdelmaksoud MH, Loo BW Jr, Kothary N. Alternatives to surgery for early stage non-small cell lung cancer-ready for prime time? *Curr Treat Options Oncol.* 2010 Jun;11(1-2):24-35. *Stanford University and Cancer Center, Stanford, CA*

Hadziahmetovic M, Loo BW, Timmerman RD, Mayr NA, Wang JZ, Huang Z, Grecula JC, Lo SS. Stereotactic body radiation therapy (stereotactic ablative radiotherapy) for stage I non-small cell lung cancer—updates of radiobiology, techniques, and clinical outcomes. *Discov Med.* 2010 May;9(48):411-7 *Ohio State University, Columbus, OH*

Timmerman R, Paulus R, Galvin J, Michalski J, Straube W, Bradley J, Fakiris A, Bezjak A, Videtic G, Johnstone D, Fowler J, Gore E, Choy H. Stereotactic body radiation therapy for inoperable early stage lung cancer. *JAMA.* 2010 Mar 17;303(11):1070-6. *University of Texas Southwestern Medical Center, Dallas*

Jin JY, Kong FM, Chetty IJ, Ajlouni M, Ryu S, Ten Haken R, Movsas B. Impact of fraction size on lung radiation toxicity: hypofractionation may be beneficial in dose escalation of radiotherapy for lung cancers. *Int J Radiat Oncol Biol Phys.* 2010 Mar 1;76(3):782-8. *Henry Ford Hospital, Detroit* Dunlap NE, Cai J, Biedermann GB, Yang W, Benedict SH, Sheng K, Schefter TE, Kavanagh BD, Larner JM.

Chest Wall Volume Receiving >30 Gy Predicts Risk of Severe Pain and/or Rib Fracture After Lung Stereotactic Body Radiotherapy. *Int J Radiat Oncol Biol Phys*. 2010 Mar 1;76(3):796-801. *University of Colorado Comprehensive Cancer Center, Denver and University of Virginia, Charlottesville*

Chi A, Liao Z, Nguyen NP, Xu J, Stea B, Komaki R. Systemic review of the patterns of failure following stereotactic body radiation therapy in early-stage non-small-cell lung cancer: clinical implications. *Radiother Oncol.* 2010 Jan;94(1):1-11. *University of Arizona, Tucson, AZ*

Kopek N, Paludan M, Petersen J, Hansen AT, Grau C, Høyer M. Co-morbidity index predicts for mortality after stereotactic body radiotherapy for medically inoperable early-stage non-small cell lung cancer. *Radiother Oncol*. 2009 Dec;93(3):402-7. *Aarhus University Hospital, Denmark.*

Song SY, Choi W, Shin SS, Lee SW, Ahn SD, Kim JH, Je HU, Park CI, Lee JS, Choi EK. Fractionated stereotactic body radiation therapy for medically inoperable stage I lung cancer adjacent to central large bronchus. *Lung Cancer.* 2009 Oct;66(1):89-93. *Asan Medical Center, University of Ulsan, Seoul*

Verbakel WF, Senan S, Cuijpers JP, Slotman BJ, Lagerwaard FJ. Rapid delivery of stereotactic radiotherapy for peripheral lung tumors using volumetric intensity-modulated arcs. *Radiother Oncol.* 2009 Oct;93(1):122- 4. *VU University Medical Center, Amsterdam*

Voroney JP, Hope A, Dahele MR, Purdy T, Franks KN, Pearson S, Cho JB, Sun A, Payne DG, Bissonnette JP, Bezjak A, Brade AM. Chest wall pain and rib fracture after stereotactic radiotherapy for peripheral nonsmall cell lung cancer. *J Thorac Oncol.* 2009 Aug;4(8):1035-7 *Cleveland Clinic Foundation, Cleveland*

Stephans KL, Djemil T, Reddy CA, Gajdos SM, Kolar M, Mason D, Murthy S, Rice TW, Mazzone P, Machuzak M, Mekhail T, Videtic GM. A comparison of two stereotactic body radiation fractionation schedules for medically inoperable stage I non-small cell lung cancer: the Cleveland Clinic experience. *J Thorac Oncol.* 2009 Aug;4(8):976-82. *Cleveland Clinic, Cleveland*

Stephans KL, Djemil T, Reddy CA, Gajdos SM, Kolar M, Machuzak M, Mazzone P, Videtic GM. Comprehensive Analysis of Pulmonary Function Test (PFT) Changes After Stereotactic Body Radiotherapy (SBRT) for Stage I Lung

Cancer in Medically Inoperable Patients. *J Thorac Oncol*. 2009 Jul;4(7):838-44. *Cleveland Clinic Foundations, Cleveland, OH*

Zhao B, Yang Y, Li T, Li X, Heron DE, Huq MS. Image-guided respiratory-gated lung stereotactic body radiotherapy: which target definition is optimal? *Med Phys.* 2009 Jun;36(6):2248-57. *University of Pittsburgh Medical Center, Pittsburgh*

Milano MT, Chen Y, Katz AW, Philip A, Schell MC, Okunieff P. Central thoracic lesions treated with hypofractionated stereotactic body radiotherapy. *Radiother Oncol*. 2009 Jun;91(3):301-6. *University of Rochester Medical Center, NY*

Rusthoven KE, Hammerman SF, Kavanagh BD, BirtwhistleMJ, Stares M, Camidge DR. Is there a role for consolidative stereotactic body radiation therapy following first-line systemic therapy for metastatic lung cancer? A patterns-of-failure analysis. *Acta Oncol*. 2009;48(4):578-83. *University of Colorado Comprehensive Cancer Center, Denver*

Rønde HS, Hoffmann L. Validation of Varian's AAA algorithm with focus on lung treatments. *Acta Oncol.* 2009;48(2):209-15. *Aarhus University Hospital, Aarhus, Denmark*

Rusthoven KE, Hammerman SF, Kavanagh BD, Birtwhistle MJ, Stares M, Camidge DR. Is there a role for consolidative stereotactic body radiation therapy following first-line systemic therapy for metastatic lung cancer? A patterns-of-failure analysis. *Acta Oncol*. 2009;48(4):578-83. *University of Colorado Comprehensive Cancer Center, Denver*

Rusthoven KE, Kavanagh BD, Burri SH, Chen C, Cardenes H, Chidel MA, Pugh TJ, Kane M, Gaspar LE, Schefter TE. Multi-institutional phase I/II trial of stereotactic body radiation therapy for lung metastases. *J Clin Oncol.* 2009 Apr 1;27(10):1579-84. *University of Colorado Comprehensive Cancer Center, Denver*

Rosenzweig KE, Movsas B, Bradley J, Gewanter RM, Gopal RS, Komaki RU, Kong FM, Lee HK, Feins RH, Langer CJ. ACR appropriateness criteria on nonsurgical treatment for non-small-cell lung cancer: poor performance status or palliative intent. *J Am Coll Radiol.* 2009 Feb;6(2):85-95. *Memorial Sloan-Kettering Cancer Center.*

Haasbeek CJ, Lagerwaard FJ, de Jaeger K, Slotman BJ, Senan S. Outcomes of stereotactic radiotherapy for a new clinical stage I lung cancer arising postpneumonectomy. *Cancer*. 2009 Feb 1;115(3):587-94. *Vrije University Medical Center, Amsterdam, The Netherlands*

Riegel AC, Chang JY, Vedam SS, Johnson V, Chi PC, Pan T. Cine computed tomography without respiratory surrogate in planning stereotactic radiotherapy for non-small-cell lung cancer. *Int J Radiat Oncol Biol Phys*. 2009 Feb 1;73(2):433-41*. M.D. Anderson Cancer Center, Houston, TX*

Vassiliev ON, Kry SF, Chang JY, Balter PA, Titt U, Mohan R. Stereotactic radiotherapy for lung cancer using a flattening filter free Clinac. *J Appl Clin Med Phys*. 2009 Jan 27;10(1):2880.Rusthoven KE, Hammerman

SF, Kavanagh BD, Birtwhistle, *M. D. Anderson Cancer Center, Houston, Texas* McCammon R, Schefter TE, Gaspar LE, Zaemisch R, Gravdahl D, Kavanagh B. Observation of a dosecontrol relationship for lung and liver tumors after stereotactic body radiation therapy. *Int J Radiat Oncol Biol Phys.* 2009 Jan 1;73(1):112-8. *University of Colorado Health Sciences Center, Aurora*

Nguyen NP, Garland L, Welsh J, Hamilton R, Cohen D, Vinh-Hung V. Can stereotactic fractionated radiation therapy become the standard of care for early stage non-small cell lung carcinoma. *Cancer Treat Rev.* 2008 Dec;34(8):719-27. *University of Arizona, Tucson*

Chang JY, Balter PA, Dong L, Yang Q, Liao Z, Jeter M, Bucci MK, McAleer MF, Mehran RJ, Roth JA, Komaki R. Stereotactic body radiation therapy in centrally and superiorly located stage I or isolated recurrent non-small-cell lung cancer. *Int J Radiat Oncol Biol Phys*. 2008 Nov 15;72(4):967-71.

Spoelstra FO, van Sörnsen de Koste JR, Cuijpers JP, Lagerwaard FJ, Slotman BJ, Senan S. Analysis of reproducibility of respiration-triggered gated radiotherapy for lung tumors. *Radiother Oncol.* 2008 Apr; 87(1):59-64. *VU University Medical Center, Amsterdam*

Heinzerling JH, Anderson JF, Papiez L, Boike T, Chien S, Zhang G, Abdulrahman R, Timmerman R. Fourdimensional computed tomography scan analysis of tumor and organ motion at varying levels of abdominal compression during stereotactic treatment of lung and liver. *Int J Radiat Oncol Biol Phys*. 2008 Apr 1;70(5):1571-8. *University of Texas Southwestern Medical Center, Dallas*

Haasbeek CJ, Senan S, Smit EF, Paul MA, Slotman BJ, Lagerwaard FJ. Critical review of nonsurgical treatment options for stage I non-small cell lung cancer. *Oncologist*. 2008 Mar;13(3):309-19. *VU University Medical Center, Amsterdam, NL*

Wakelee H, Langer C, Vokes E, Schiller J, Baas P, Saijo N, Adjei A, Shepherd F, Choy H, Gandara DR. Cooperative group research efforts in lung cancer: focus on early-stage non-small-cell lung cancer. *Clin Lung Cancer.* 2008 Jan;9(1):9-15. *Stanford University Medical Center, Palo Alto*

Lagerwaard FJ, Haasbeek CJ, Smit EF, Slotman BJ, Senan S. Outcomes of risk-adapted fractionated stereotactic radiotherapy for stage I non-small-cell lung cancer. *Int J Radiat Oncol Biol Phys.* 2008 Mar 1;70(3):685-92. *VU University Medical Center, Amsterdam, NL*

Chang JY, Dong L, Liu H, Starkschall G, Balter P, Mohan R, Liao Z, Cox JD, Komaki R. Image-guided radiation therapy for non-small cell lung cancer. *J Thorac Oncol.* 2008 Feb;3(2):177-86.. *MD Anderson Cancer Center, Houston, Texas*

Wakelee H, Langer C, Vokes E, Schiller J, Baas P, Saijo N, Adjei A, Shepherd F, Choy H, Gandara DR. Cooperative group research efforts in lung cancer: focus on early-stage non-small-cell lung cancer. *Clin Lung Cancer.* 2008 Jan;9(1):9-15. *Stanford University Medical Center, Palo Alto*

Maxim PG, Loo BW Jr, Shirazi H, Thorndyke B, Luxton G, Le QT. Quantification of motion of different thoracic locations using four-dimensional computed tomography: implications for radiotherapy planning. *Int J Radiat Oncol Biol Phys.* 2007 Dec 1;69(5):1395-401. *Stanford University Medical Center, Palo Alto*

Wang Z, Wu QJ, Marks LB, Larrier N, Yin FF. Cone-beam CT localization of internal target volumes for stereotactic body radiotherapy of lung lesions. *Int J Radiat Oncol Biol Phys.* 2007 Dec 1;69(5):1618-24. *Duke University Medical Center, Raleigh-Durham*

Xu Q, Hamilton RJ, Schowengerdt RA, Jiang SB. A deformable lung tumor tracking method in fluoroscopic video using active shape models: a feasibility study. *Phys Med Biol.* 2007 Sep 7;52(17):5277-93. *University of Arizona, Tucson*

Timmerman RD, Park C, Kavanagh BD. The North American experience with stereotactic body radiation therapy in non-small cell lung cancer. *J Thorac Oncol*. 2007 Jul;2(7 Suppl 3):S101-12. *University of Texas Southwestern Medical Center, Dallas*

Panettieri V, Wennberg B, Gagliardi G, Duch MA, Ginjaume M, Lax I. SBRT of lung tumours: Monte Carlo simulation with PENELOPE of dose distributions including respiratory motion and comparison with different treatment planning systems. *Phys Med Biol*. 2007 Jul 21;52(14):4265-81. *Universitat Politècnica de Catalunya, Barcelona, SP*

H&N-EENT & Skull Base

Non-CNS Tumors of the Orbt and Head & Neck

Rwigema JC, Heron DE, Ferris RL, Andrade RS, Gibson MK, Yang Y, Ozhasoglu C, Argiris AE, Grandis JR, Burton SA. The Impact of Tumor Volume and Radiotherapy Dose on Outcome in Previously Irradiated Recurrent Squamous Cell Carcinoma of the Head and Neck Treated With Stereotactic Body Radiation Therapy. *Am J Clin Oncol.* 2010 Sep 20. *University of Pittsburgh Cancer Institute, Pittsburgh, PA* [Epub ahead of print]

Heron DE, Rwigema JC, Gibson MK, Burton SA, Quinn AE, Ferris RL. Concurrent Cetuximab With Stereotactic Body Radiotherapy for Recurrent Squamous Cell Carcinoma of the Head and Neck: A Single Institution Matched Case-

Control Study. *Am J Clin Oncol.* 2010 Aug 3. *University of Pittsburgh Cancer Institute, Pittsburgh, PA* [Epub ahead of print]

Kan MW, Cheung JY, Leung LH, Lau BM, Yu PK. The accuracy of dose calculations by anisotropic analytical algorithms for stereotactic radiotherapy in nasopharyngeal carcinoma. *Phys Med Biol.* 2010 Dec 22;56(2):397-413. *Princess Margaret Hospital, Hong Kong SAR, People's Republic of China.*

Heron DE, Ferris RL, Karamouzis M, Andrade RS, Deeb EL, Burton S, Gooding WE, Branstetter BF, Mountz JM, Johnson JT, Argiris A, Grandis JR, Lai SY. Stereotactic Body Radiotherapy for Recurrent Squamous Cell Carcinoma of the Head and Neck: Results of a Phase I Dose-Escalation Trial. *Int J Radiat Oncol Biol Phys.* 2009 Dec 1;75(5):1493-500. *University of Pittsburgh, Pittsburgh, PA*

Heron DE. Stereotactic body radiation therapy for recurrent head & neck cancers: rethi nking nonoperative salvage strategies. *Future Oncol*. 2009 Nov;5(9):1321-5, *UPMC Medical Center, Pittsburgh, PA*

Verbakel WF, Cuijpers JP, Hoffmans D, Bieker M, Slotman BJ, Senan S. Volumetric intensity-modulated arc therapy vs. conventional IMRT in head-and-neck cancer: a comparative planning and dosimetric study. *Int J Radiat Oncol Biol Phys.* 2009 May 1;74(1):252-9. *VU University Medical Center, Amsterdam, The Netherlands.*

Siddiqui F, Patel M, Khan M, McLean S, Dragovic J, Jin JY, Movsas B, Ryu S. Stereotactic Body Radiation Therapy for Primary, Recurrent, and Metastatic Tumors in the Head-and-Neck Region. *Int J Radiat Oncol Biol Phys.* 2009 Jul 15;74(4):1047-53 *Henry Ford Health System, Detroit, MI*

Gagne IM, Ansbacher W, Zavgorodni S, Popescu C, Beckham WA. A Monte Carlo evaluation of RapidArc dose calculations for oropharynx radiotherapy. *Phys Med Biol.* 2008 Dec 21;53(24):7167-85. *BC Cancer Agency-Vancouver Island Centre, Victoria, British Columbia, Canada*.

Kim GY, Pawlicki T, Le QT, Luxton G. Linac-based on-board imaging feasibility and the dosimetric consequences of head roll in head-and-neck IMRT plans. *Med Dosim*. 2008 Spring;33(1):93-9. *Stanford University Medical Center, Palo Alto*

Wu SX, Chua DT, Deng ML, Zhao C, Li FY, Sham JS, Wang HY, Bao Y, Gao YH, Zeng ZF. Outcome of fractionated stereotactic radiotherapy for 90 patients with locally persistent and recurrent nasopharyngeal carcinoma. *Int J Radiat Oncol Biol Phys.* 2007 Nov 1;69(3):761-9. *Duke University Medical Center, Raleigh- Durham*

Miralbell R, Caro M, Weber DC, Elizalde J, Perez-Ochoa A, Villà S, IgnacioToscas J, Martinez P, Linero D, Nouet P, Escudé L. Stereotactic Radiotherapy for Ocular Melanoma: Initial Experience Using Closed Eyes For Ocular Target Immobilization, *Technol Cancer Res Treat.* Oct 2007;6(5):361-588), *Instituto Oncológico Teknon, Barcelona, SP*

Lawson JD, Elder E, Fox T, Davis L, Crocker I. Quantification of dosimetric impact of implementation of onboard imaging (OBI) for IMRT treatment of head-and-neck malignancies. *Med Dosim*. 2007 Winter; 32(4):287-94. *Emory University, Atlanta*

Henderson MA, Shirazi H, Lo SS, Mendonca MS, Fakiris AJ, Witt TC, Worth RM, Timmerman RD. Stereotactic radiosurgery and fractionated stereotactic radiotherapy in the treatment of uveal melanoma. *Technol Cancer Res Treat*. 2006 Aug;5(4):411-9. *University of Texas Southwestern Medical Center, Dallas*

Poznanovic SA, Cass SP, Kavanagh BD., Short-term tumor control and acute toxicity after stereotactic radiosurgery for glomus jugulare tumors. *Otolaryngol Head Neck Surg.* 2006 Mar;134(3):437-42. *University of Colorado Health Sciences Center, Aurora*

Linthout N, Verellen D, Tournel K, Storme G. Six dimensional analysis with daily stereoscopic x-ray imaging of intrafraction patient motion in head and neck treatments using five points fixation masks. *Med Phys*. 2006 Feb;33(2):504-13. *Academic Hospital-Free University, Brussels*

Ernst-Stecken A, Lambrecht U, Ganslandt O, Mueller R, Fahlbusch R, Sauer R, Grabenbauer G. Radiosurgery of small skull-base lesions. No advantage for intensity-modulated stereotactic radiosurgery versus conformal arc technique. *Strahlenther Onkol.* 2005 May;181(5):336-44. *University of Erlangen-Nuremberg, Erlangen, DE.*

Saarilahti K, Kouri M, Collan J, Hamalainen T, Atula T, Joensuu H, Tenhunen M. Intensity modulated radiotherapy for head and neck cancer: evidence for preserved salivary gland function. *Radiother Oncol.* 2005 Mar;74(3):251-8. *Helsinki University Central Hospital*

Ryu S, Khan M, Yin FF, Concus A, Ajlouni M, Benninger MS, Kim JH. Image-guided radiosurgery of head and neck cancers. *Otolaryngol Head Neck Surg*. 2004 Jun;130(6):690-7. *Henry Ford Hospital*

Nakamura JL, Pirzkall A, Carol MP, Xia P, Smith V, Wara WM, Petti PL, Verhey LJ, Sneed PK. Comparison of intensity-modulated radiosurgery with gamma knife radiosurgery for challenging skull base lesions. *Int J Radiat Oncol Biol Phys.* 2003 Jan 1;55(1):99-109. *UCSF, San Francisco*

Linthout N, Verellen D, Van Acker S, Voordeckers M, Bretz A, Storme G. Evaluation of dose calculation algorithms for dynamic arc treatments of head and neck tumors. *Radiother Oncol*. 2002 Jul;64(1):85-95. *Academic Hospital, Free University Brussels, BE*

Fiveash JB, Murshed H, Duan J, Hyatt M, Caranto J, Bonner JA, Popple RA. Effect of multileaf collimator leaf width on physical dose distributions in the treatment of CNS and head and neck neoplasms with intensity modulated radiation therapy. *Med Phys.* 2002 Jun;29(6):1116-9. *University of Alabama-Birmingham*

Feigenberg SJ, Mendenhall WM, Hinerman RW, Amdur RJ, Friedman WA, Antonelli PJ. Radiosurgery for paraganglioma of the temporal bone. *Head Neck*. 2002 Apr;24(4):384-9. *University of Florida, Gainesville*

LUNG

Primary and Metastatic Lung Lesions

Palma DA, van Sörnsen de Koste JR, Verbakel WF, Senan S. A new approach to quantifying lung damage after stereotactic body radiation therapy. *Acta Oncol.* 2010 Dec 21. *VU University Medical Center, Amsterdam, The Netherlands* [Epub ahead of print]

Palma D, Visser O, Lagerwaard FJ, Belderbos J, Slotman BJ, Senan S. Impact of Introducing Stereotactic Lung Radiotherapy for Elderly Patients With Stage I Non-Small-Cell Lung Cancer: A Population-Based Time-Trend Analysis. *J Clin Oncol.* 2010 Nov 1. *Vrije Universiteit University Medical Center, Amsterdam*, [Epub ahead of print]

Palma DA, Senan S, Haasbeek CJ, Verbakel WF, Vincent A, Lagerwaard F. Radiological and Clinical Pneumonitis after Stereotactic Lung Radiotherapy: A Matched Analysis of Three-dimensional Conformal and Volumetric-modulated Arc Therapy Techniques. *Int J Radiat Oncol Biol Phys.* 2010 Jun 26. *VU Medical Center, Amsterdam, The Netherlands* [Epub ahead of print]

Welsh J, Thomas J, Shah D, Allen PK, Wei X, Mitchell K, Gao S, Balter P, Komaki R, Chang JY. Obesity Increases the Risk of Chest Wall Pain from Thoracic Stereotactic Body Radiation Therapy. *Int J Radiat Oncol Biol Phys.* 2010 Jun 11. *The University of Texas M. D. Anderson Cancer Center, Houston, TX*. [Epub ahead of print]

Chi A, Tomé WA, Fowler J, Komaki R, Nguyen NP, Mehta MP, Welsh JS Stereotactic Body Radiation Therapy in Non-Small-Cell Lung Cancer: Linking Radiobiological Modeling and Clinical Outcome. *Am J Clin Oncol*. 2010 Jun 9. *University of Arizona, Tucson, AZ* [Epub ahead of print]

Chen F, Matsuo Y, Yoshizawa A, Sato T, Sakai H, Bando T, Okubo K, Shibuya K, Date H. Salvage lung resection for non-small cell lung cancer after stereotactic body radiotherapy in initially operable patients. *J Thorac Oncol*. 2010 Dec;5(12):1999-2002. *Kyoto University, Kyoto, Japan.*

Kelly P, Balter PA, Rebueno N, Sharp HJ, Liao Z, Komaki R, Chang JY. Stereotactic body radiation therapy for patients with lung cancer previously treated with thoracic radiation. *Int J Radiat Oncol Biol Phys.* 2010 Dec 1;78(5):1387-93. *The University of Texas M. D. Anderson Cancer Center, Houston*

Palma D, Senan S. Stereotactic radiation therapy: changing treatment paradigms for stage I nonsmall cell lung cancer. *Curr Opin Oncol.* 2010 Nov 22. *University of Western Ontario, London, Ontario & VUMC* [Epub ahead of print]

Ong CL, Verbakel WF, Cuijpers JP, Slotman BJ, Lagerwaard FJ, Senan S. Stereotactic radiotherapy for peripheral lung tumors: a comparison of volumetric modulated arc therapy with 3 other delivery techniques. *Radiother Oncol.* 2010 Dec;97(3):437-42. *VU University Medical Center, Amsterdam, The Netherlands*

De Ruysscher D, Faivre-Finn C, Nestle U, Hurkmans CW, Le Péchoux C, Price A, Senan S. European organization for research and treatment of cancer recommendations for planning and delivery of high-dose, high-precision radiotherapy for lung cancer. *J Clin Oncol.* 2010 Dec 20;28(36):5301-10, *Maastricht University Medical Center, Maastricht, the Netherlands & Others*

Kelly P, Balter PA, Rebueno N, Sharp HJ, Liao Z, Komaki R, Chang JY. Stereotactic Body Radiation Therapy for Patients with Lung Cancer Previously Treated with Thoracic Radiation. *Int J Radiat Oncol Biol Phys*. 2010 Dec 1;78(5):1387-93. *The University of Texas M. D. Anderson Cancer Center*, Houston

Burdick MJ, Stephans KL, Reddy CA, Djemil T, Srinivas SM, Videtic GM. Maximum standardized uptake value from staging FDG-PET/CT does not predict treatment outcome for early-stage non-small-cell lung cancer treated with stereotactic body radiotherapy. *Int J Radiat Oncol Biol Phys*. 2010 Nov 15;78(4):1033-9 *Cleveland Clinic, Cleveland, OH*

Baba F, Shibamoto Y, Ogino H, Murata R, Sugie C, Iwata H, Otsuka S, Kosaki K, Nagai A, Murai T, Miyakawa A. Clinical outcomes of stereotactic body radiotherapy for stage I non-small cell lung cancer using different doses depending on tumor size. *Radiat Oncol*. 2010 Sep 17;5(1):81. *Nagoya City University, Nagoya, JP*

Buyyounouski MK, Balter P, Lewis B, D'Ambrosio DJ, Dilling TJ, Miller RC, Schefter T, Tomé W, Harris EE, Price RA Jr, Konski AA, Wallner PE. Stereotactic body radiotherapy for early-stage non-small-cell lung cancer: report of the ASTRO Emerging Technology Committee. *Int J Radiat Oncol Biol Phys*. 2010 Sep 1;78(1):3-10. *Includes University of Colorado*

Crabtree TD, Denlinger CE, Meyers BF, El Naqa I, Zoole J, Krupnick AS, Kreisel D, Patterson GA, Bradley JD. Stereotactic body radiation therapy versus surgical resection for stage I non-small cell lung cancer. *J Thorac Cardiovasc Surg.* 2010 Aug;140(2):377-86. *Washington University School of Medicine, St. Louis, MO*

van Dam IE, van Sörnsen de Koste JR, Hanna GG, Muirhead R, Slotman BJ, Senan S. Improving target delineation on 4-dimensional CT scans in stage I NSCLC using a deformable registration tool. *Radiother Oncol.* 2010 Jul;96(1):67-72. *VU University Medical Center, Amsterdam,*

Trovo M, Linda A, El Naqa I, Javidan-Nejad C, Bradley J. Early and late lung radiographic injury following stereotactic body radiation therapy (SBRT). *Lung Cancer.* 2010 Jul;69(1):77-85. *Washington University Medical Center, St. Louis*

Robinson CG, Bradley JD. The Treatment of Early-Stage Disease. *Semin Radiat Oncol.* 2010 Jul;20(3):178- 185. *Washington University School of Medicine. St. Louis*

Huang L, Park K, Boike T, Lee P, Papiez L, Solberg T, Ding C, Timmerman RD A study on the dosimetric accuracy of treatment planning for stereotactic body radiation therapy of lung cancer using average and maximum intensity projection images. *Radiother Oncol.* 2010 Jul;96(1):48-54. *The University of Texas Southwestern Medical Center, Dallas*

Bradley JD, El Naqa I, Drzymala RE, Trovo M, Jones G, Denning MD. Stereotactic body radiation therapy for early-stage non-small-cell lung cancer: the pattern of failure is distant. *Int J Radiat Oncol Biol Phys.* 2010 Jul 15;77(4):1146-50 *Washington University School of Medicine, St. Louis, MO*

Videtic GM, Stephans K, Reddy C, Gajdos S, Kolar M, Clouser E, Djemil T. Intensity-modulated radiotherapy-based stereotactic body radiotherapy for medically inoperable early-stage lung cancer: excellent local control. *Int J Radiat Oncol Biol Phys.* 2010 Jun 1;77(2):344-9. *Cleveland Clinic Foundation, Cleveland*

Das M, Abdelmaksoud MH, Loo BW Jr, Kothary N. Alternatives to surgery for early stage non-small cell lung cancer-ready for prime time? *Curr Treat Options Oncol.* 2010 Jun;11(1-2):24-35. *Stanford University and Cancer Center, Stanford, CA*

Hadziahmetovic M, Loo BW, Timmerman RD, Mayr NA, Wang JZ, Huang Z, Grecula JC, Lo SS. Stereotactic body radiation therapy (stereotactic ablative radiotherapy) for stage I non-small cell lung cancer—updates of radiobiology, techniques, and clinical outcomes. *Discov Med.* 2010 May;9(48):411-7 *Ohio State University, Columbus, OH*

Timmerman R, Paulus R, Galvin J, Michalski J, Straube W, Bradley J, Fakiris A, Bezjak A, Videtic G, Johnstone D, Fowler J, Gore E, Choy H. Stereotactic body radiation therapy for inoperable early stage lung cancer. *JAMA.* 2010 Mar 17;303(11):1070-6. *University of Texas Southwestern Medical Center, Dallas*

Jin JY, Kong FM, Chetty IJ, Ajlouni M, Ryu S, Ten Haken R, Movsas B. Impact of fraction size on lung radiation toxicity: hypofractionation may be beneficial in dose escalation of radiotherapy for lung cancers. *Int J Radiat Oncol Biol Phys.* 2010 Mar 1;76(3):782-8. *Henry Ford Hospital, Detroit*

Dunlap NE, Cai J, Biedermann GB, Yang W, Benedict SH, Sheng K, Schefter TE, Kavanagh BD, Larner JM. Chest Wall Volume Receiving >30 Gy Predicts Risk of Severe Pain and/or Rib Fracture After Lung Stereotactic Body Radiotherapy. *Int J Radiat Oncol Biol Phys*. 2010 Mar 1;76(3):796-801. *University of Colorado Comprehensive Cancer Center, Denver and University of Virginia, Charlottesville*

Chi A, Liao Z, Nguyen NP, Xu J, Stea B, Komaki R. Systemic review of the patterns of failure following stereotactic body radiation therapy in early-stage non-small-cell lung cancer: clinical implications. *Radiother Oncol.* 2010 Jan;94(1):1-11. *University of Arizona, Tucson, AZ*

Kopek N, Paludan M, Petersen J, Hansen AT, Grau C, Høyer M. Co-morbidity index predicts for mortality after stereotactic body radiotherapy for medically inoperable early-stage non-small cell lung cancer. *Radiother Oncol*. 2009 Dec;93(3):402-7. *Aarhus University Hospital, Denmark.*

Song SY, Choi W, Shin SS, Lee SW, Ahn SD, Kim JH, Je HU, Park CI, Lee JS, Choi EK. Fractionated stereotactic body radiation therapy for medically inoperable stage I lung cancer adjacent to central large bronchus. *Lung Cancer.* 2009 Oct;66(1):89-93. *Asan Medical Center, University of Ulsan, Seoul*

Verbakel WF, Senan S, Cuijpers JP, Slotman BJ, Lagerwaard FJ. Rapid delivery of stereotactic radiotherapy for peripheral lung tumors using volumetric intensity-modulated arcs. *Radiother Oncol.* 2009 Oct;93(1):122- 4. *VU University Medical Center, Amsterdam*

Voroney JP, Hope A, Dahele MR, Purdy T, Franks KN, Pearson S, Cho JB, Sun A, Payne DG, Bissonnette JP, Bezjak A, Brade AM. Chest wall pain and rib fracture after stereotactic radiotherapy for peripheral nonsmall cell lung cancer. *J Thorac Oncol.* 2009 Aug;4(8):1035-7 *Cleveland Clinic Foundation, Cleveland*

Stephans KL, Djemil T, Reddy CA, Gajdos SM, Kolar M, Mason D, Murthy S, Rice TW, Mazzone P, MachuzakM, Mekhail T, Videtic GM. A comparison of two stereotactic body radiation fractionation schedules for medically inoperable stage I non-small cell lung cancer: the Cleveland Clinic experience. *J Thorac Oncol.* 2009 Aug;4(8):976-82. *Cleveland Clinic, Cleveland*

Stephans KL, Djemil T, Reddy CA, Gajdos SM, Kolar M, Machuzak M, Mazzone P, Videtic GM. Comprehensive Analysis of Pulmonary Function Test (PFT) Changes After Stereotactic Body Radiotherapy (SBRT) for Stage I Lung Cancer in Medically Inoperable Patients. *J Thorac Oncol*. 2009 Jul;4(7):838-44. *Cleveland Clinic Foundations, Cleveland, OH*

Zhao B, Yang Y, Li T, Li X, Heron DE, Huq MS. Image-guided respiratory-gated lung stereotactic body radiotherapy: which target definition is optimal? *Med Phys.* 2009 Jun;36(6):2248-57. *University of Pittsburgh Medical Center, Pittsburgh*

Milano MT, Chen Y, Katz AW, Philip A, Schell MC, Okunieff P. Central thoracic lesions treated with hypofractionated stereotactic body radiotherapy. *Radiother Oncol*. 2009 Jun;91(3):301-6. *University of Rochester Medical Center, NY*

Rusthoven KE, Hammerman SF, Kavanagh BD, BirtwhistleMJ, Stares M, Camidge DR. Is there a role for consolidative stereotactic body radiation therapy following first-line systemic therapy for metastatic lung cancer? A patterns-of-failure analysis. *Acta Oncol*. 2009;48(4):578-83. *University of Colorado Comprehensive Cancer Center, Denver*

Rønde HS, Hoffmann L. Validation of Varian's AAA algorithm with focus on lung treatments. *Acta Oncol.* 2009;48(2):209-15. *Aarhus University Hospital, Aarhus, Denmark*

Rusthoven KE, Hammerman SF, Kavanagh BD, Birtwhistle MJ, Stares M, Camidge DR. Is there a role for consolidative stereotactic body radiation therapy following first-line systemic therapy for metastatic lung cancer? A patterns-of-failure analysis. *Acta Oncol*. 2009;48(4):578-83. *University of Colorado Comprehensive Cancer Center, Denver*

Rusthoven KE, Kavanagh BD, Burri SH, Chen C, Cardenes H, Chidel MA, Pugh TJ, Kane M, Gaspar LE, Schefter TE. Multi-institutional phase I/II trial of stereotactic body radiation therapy for lung metastases. *J Clin Oncol.* 2009 Apr 1;27(10):1579-84. *University of Colorado Comprehensive Cancer Center, Denver*

Rosenzweig KE, Movsas B, Bradley J, Gewanter RM, Gopal RS, Komaki RU, Kong FM, Lee HK, Feins RH, Langer CJ. ACR appropriateness criteria on nonsurgical treatment for non-small-cell lung cancer: poor performance status or palliative intent. *J Am Coll Radiol.* 2009 Feb;6(2):85-95. *Memorial Sloan-Kettering Cancer Center.*

Haasbeek CJ, Lagerwaard FJ, de Jaeger K, Slotman BJ, Senan S. Outcomes of stereotactic radiotherapy for a new clinical stage I lung cancer arising postpneumonectomy. *Cancer*. 2009 Feb 1;115(3):587-94. *Vrije University Medical Center, Amsterdam, The Netherlands*

Riegel AC, Chang JY, Vedam SS, Johnson V, Chi PC, Pan T. Cine computed tomography without respiratory surrogate in planning stereotactic radiotherapy for non-small-cell lung cancer. *Int J Radiat Oncol Biol Phys*. 2009 Feb 1;73(2):433-41*. M.D. Anderson Cancer Center, Houston, TX*

Vassiliev ON, Kry SF, Chang JY, Balter PA, Titt U, Mohan R. Stereotactic radiotherapy for lung cancer using a flattening filter free Clinac. *J Appl Clin Med Phys*. 2009 Jan 27;10(1):2880.Rusthoven KE, Hammerman SF, Kavanagh BD, Birtwhistle, *M. D. Anderson Cancer Center, Houston, Texas*

McCammon R, Schefter TE, Gaspar LE, Zaemisch R, Gravdahl D, Kavanagh B. Observation of a dosecontrol relationship for lung and liver tumors after stereotactic body radiation therapy. *Int J Radiat Oncol Biol Phys.* 2009 Jan 1;73(1):112-8. *University of Colorado Health Sciences Center, Aurora*

Nguyen NP, Garland L, Welsh J, Hamilton R, Cohen D, Vinh-Hung V. Can stereotactic fractionated radiation therapy become the standard of care for early stage non-small cell lung carcinoma. *Cancer Treat Rev.* 2008 Dec;34(8):719-27. *University of Arizona, Tucson*

Chang JY, Balter PA, Dong L, Yang Q, Liao Z, Jeter M, Bucci MK, McAleer MF, Mehran RJ, Roth JA, Komaki R. Stereotactic body radiation therapy in centrally and superiorly located stage I or isolated recurrent non-small-cell lung cancer. *Int J Radiat Oncol Biol Phys*. 2008 Nov 15;72(4):967-71.

Spoelstra FO, van Sörnsen de Koste JR, Cuijpers JP, Lagerwaard FJ, Slotman BJ, Senan S. Analysis of reproducibility of respiration-triggered gated radiotherapy for lung tumors. *Radiother Oncol.* 2008 Apr; 87(1):59-64. *VU University Medical Center, Amsterdam*

Heinzerling JH, Anderson JF, Papiez L, Boike T, Chien S, Zhang G, Abdulrahman R, Timmerman R. Fourdimensional computed tomography scan analysis of tumor and organ motion at varying levels of abdominal compression during stereotactic treatment of lung and liver. *Int J Radiat Oncol Biol Phys*. 2008 Apr 1;70(5):1571-8. *University of Texas Southwestern Medical Center, Dallas*

Haasbeek CJ, Senan S, Smit EF, Paul MA, Slotman BJ, Lagerwaard FJ. Critical review of nonsurgical treatment options for stage I non-small cell lung cancer. *Oncologist*. 2008 Mar;13(3):309-19. *VU University Medical Center, Amsterdam, NL*

Wakelee H, Langer C, Vokes E, Schiller J, Baas P, Saijo N, Adjei A, Shepherd F, Choy H, Gandara DR. Cooperative group research efforts in lung cancer: focus on early-stage non-small-cell lung cancer. *Clin Lung Cancer.* 2008 Jan;9(1):9-15. *Stanford University Medical Center, Palo Alto*

Lagerwaard FJ, Haasbeek CJ, Smit EF, Slotman BJ, Senan S. Outcomes of risk-adapted fractionated stereotactic radiotherapy for stage I non-small-cell lung cancer. *Int J Radiat Oncol Biol Phys.* 2008 Mar 1;70(3):685-92. *VU University Medical Center, Amsterdam, NL*

Chang JY, Dong L, Liu H, Starkschall G, Balter P, Mohan R, Liao Z, Cox JD, Komaki R. Image-guided radiation therapy for non-small cell lung cancer. *J Thorac Oncol.* 2008 Feb;3(2):177-86.. *MD Anderson Cancer Center, Houston, Texas*

Wakelee H, Langer C, Vokes E, Schiller J, Baas P, Saijo N, Adjei A, Shepherd F, Choy H, Gandara DR. Cooperative group research efforts in lung cancer: focus on early-stage non-small-cell lung cancer. *Clin Lung Cancer.* 2008 Jan;9(1):9-15. *Stanford University Medical Center, Palo Alto*

Maxim PG, Loo BW Jr, Shirazi H, Thorndyke B, Luxton G, Le QT. Quantification of motion of different thoracic locations using four-dimensional computed tomography: implications for radiotherapy planning. *Int J Radiat Oncol Biol Phys.* 2007 Dec 1;69(5):1395-401. *Stanford University Medical Center, Palo Alto*

Wang Z, Wu QJ, Marks LB, Larrier N, Yin FF. Cone-beam CT localization of internal target volumes for stereotactic body radiotherapy of lung lesions. *Int J Radiat Oncol Biol Phys.* 2007 Dec 1;69(5):1618-24. *Duke University Medical Center, Raleigh-Durham*

Xu Q, Hamilton RJ, Schowengerdt RA, Jiang SB. A deformable lung tumor tracking method in fluoroscopic video using active shape models: a feasibility study. *Phys Med Biol.* 2007 Sep 7;52(17):5277-93. *University of Arizona, Tucson*

Timmerman RD, Park C, Kavanagh BD. The North American experience with stereotactic body radiation therapy in non-small cell lung cancer. *J Thorac Oncol*. 2007 Jul;2(7 Suppl 3):S101-12. *University of Texas Southwestern Medical Center, Dallas*

Panettieri V, Wennberg B, Gagliardi G, Duch MA, Ginjaume M, Lax I. SBRT of lung tumours: Monte Carlo simulation with PENELOPE of dose distributions including respiratory motion and comparison with different treatment planning systems. *Phys Med Biol*. 2007 Jul 21;52(14):4265-81. *Universitat Politècnica de Catalunya, Barcelona, SP*

Hoopes DJ, Tann M, Fletcher JW, Forquer JA, Lin PF, Lo SS, Timmerman RD, McGarry RC. FDG-PET and stereotactic body radiotherapy (SBRT) for stage I non-small-cell lung cancer. *Lung Cancer*. 2007 May;56(2):229-34*, Indiana University, Indianapolis*

Haasbeek CJ, Lagerwaard FJ, Cuijpers JP, Slotman BJ, Senan S. Is adaptive treatment planning required for stereotactic radiotherapy of stage I non-small-cell lung cancer? *Int J Radiat Oncol Biol Phys.* 2007 Apr 1;67(5):1370-4. *VU University Medical Center, Amsterdam, NL*

Duggan DM, Ding GX, Coffey CW 2nd, Kirby W, Hallahan DE, Malcolm A, Lu B. Deep-inspiration breathhold kilovoltage cone-beam CT for setup of stereotactic body radiation therapy for lung tumors: initial experience. *Lung Cancer.* 2007 Apr;56(1):77-88. *Vanderbilt University, Nashville, TN*

Ernst-Stecken A, Lambrecht U, Mueller R, Sauer R, Grabenbauer G. Hypofractionated stereotactic radiotherapy for primary and secondary intrapulmonary tumors: first results of a phase I/II study. *Strahlenther Onkol*. 2006 Dec;182(12):696-702. *University of Erlangen-Nuremberg, Erlangen, Germany*

Wang L, Feigenberg S, Chen L, Pasklev K, Ma CC. Benefit of three-dimensional image-guided stereotactic localization in the hypofractionated treatment of lung cancer. *Int J Radiat Oncol Biol Phys*. 2006 Nov 1;66(3):738-47. *Fox Chase Cancer Center, Philadelphia.*

Willoughby TR, Forbes AR, Buchholz D, Langen KM, Wagner TH, Zeidan OA, Kupelian PA, Meeks SL. Evaluation of an infrared camera and X-ray system using implanted fiducials in patients with lung tumors for gated radiation therapy. *Int J Radiat Oncol Biol Phys.* 2006 Oct 1;66(2):568-75. *MD Anderson Cancer Center Orlando, Orlando*

Timmerman R, McGarry R, Yiannoutsos C, Papiez L, Tudor K, DeLuca J, Ewing. Excessive toxicity when treating central tumors in a phase II study of stereotactic body radiation therapy for medically inoperable early-stage lung cancer. *J Clin Oncol.* 2006 Oct 20;24. *The University of Texas Southwestern Medical Center, Dallas, TX*

Timmerman R, Galvin J, Michalski J, Straube W, Ibbott G, Martin E, Abdulrahman R, Swann S, Fowler J, Choy H. Accreditation and quality assurance for Radiation Therapy Oncology Group: Multicenter clinical trials using Stereotactic Body Radiation Therapy in lung cancer. *Acta Oncol*. 2006;45(7):779-86. *University of Texas Southwestern Medical Center, Dallas*

Baumann P, Nyman J, Lax I, Friesland S, Hoyer M, Rehn Ericsson S, Johansson KA, Ekberg L, Morhed E, Paludan M, Wittgren L, Blomgren H, Lewensohn R. Factors important for efficacy of stereotactic body radiotherapy of medically inoperable stage I lung cancer. A retrospective analysis of patients treated in the Nordic countries. *Acta Oncol*. 2006;45(7):787-95. *Karolinska University Hospital, Sweden.*

Paludan M, Traberg Hansen A, Petersen J, Grau C, Hoyer M. Aggravation of dyspnea in stage I non-small cell lung cancer patients following stereotactic body radiotherapy: Is there a dose-volume dependency? *Acta Oncol*. 2006;45(7):818-22. *Aarhus University Hospital, Aarhus, Denmark*

Wurm RE, Gum F, Erbel S, Schlenger L, Scheffler D, Agaoglu D, Schild R, Gebauer B, Rogalla P, Plotkin M, Ocran K, Budach V. Image guided respiratory gated hypofractionated Stereotactic Body Radiation Therapy (H-SBRT) for liver and lung tumors: Initial experience. *Acta Oncol*. 2006;45(7):881-9. *Charité- Universitätsmedizin Berlin, DE*

Slotman BJ, Lagerwaard FJ, Senan S. 4D imaging for target definition in stereotactic radiotherapy for lung cancer. *Acta Oncol.* 2006;45(7):966-72. *VU University Medical Center, Amsterdam*

Djarv E, Nyman J, Baumann P, Ekberg L, Hoyer M, Lax I, Lewensohn R, Levin N, Lund JA, Morhed E, Ericsson SR, Traberg A, Wittgren L, Johansson KA. Dummy run for a phase II study of stereotactic body radiotherapy of T1-T2 N0M0 medical inoperable non-small cell lung cancer. *Acta Oncol*. 2006;45(7):973-7. *Sahlgrenska University Hospital, Gothenburg, Sweden*

Underberg RW, Lagerwaard FJ, van Tinteren H, Cuijpers JP, Slotman BJ, Senan S. Time trends in target volumes for stage I non-small-cell lung cancer after stereotactic radiotherapy. *Int J Radiat Oncol Biol Phys.* 2006 Mar 15;64(4):1221-8. *VU University Medical Center, Amsterdam*, Full Text + Links | PDF

Jin JY, Ajlouni M, Chen Q, Yin FF, Movsas B.A technique of using gated-CT images to determine internal target volume (ITV) for fractionated stereotactic lung radiotherapy. *Radiother Oncol.* 2006 Feb;78(2):177-84. *Henry Ford Hospital, Detroit*

Song DY, Benedict SH, Cardinale RM, Chung TD, Chang MG, Schmidt-Ullrich RK. Stereotactic body radiation therapy of lung tumors: preliminary experience using normal tissue complication probability-based dose limits. *Am J Clin Oncol*. 2005 Dec;28(6):591-6., *Virginia Commonwealth University Medical Center, Richmond*

McGarry RC, Papiez L, Williams M, Whitford T, Timmerman RD. Stereotactic body radiation therapy of early- stage non-small-cell lung carcinoma: phase I study. *Int J Radiat Oncol Biol Phys*. 2005 Nov 15;63(4):1010-5. *Indiana University, Indianapolis*

Underberg RW, Lagerwaard FJ, Slotman BJ, Cuijpers JP, Senan S. Use of maximum intensity projections (MIP) for target volume generation in 4DCT scans for lung cancer. *Int J Radiat Oncol Biol Phys*. 2005 Sep 1;63(1):253-60. *VU University Medical Center, Amsterdam, NL*

Underberg RW, Lagerwaard FJ, Slotman BJ, Cuijpers JP, Senan S. Benefit of respiration-gated stereotactic radiotherapy for stage I lung cancer: an analysis of 4DCT datasets. *Int J Radiat Oncol Biol Phys.* 2005 Jun 1;62(2):554-60. *VU University Medical Center, Amsterdam*

de Mey J, Van de Steene J, Vandenbroucke F, Verellen D, Trappeniers L, Meysman M, Everaert H, Noppen M, Storme G, Bossuyt A. Percutaneous placement of marking coils before stereotactic radiation therapy of malignant lung lesions. *J Vasc Interv Radiol.* 2005 Jan;16(1):51-6. *University Hospital Vrije Universiteit Brussel, Bressels, BE*

Underberg RW, Lagerwaard FJ, Cuijpers JP, Slotman BJ, van Sornsen de Koste JR, Senan S. Fourdimensional CT scans for treatment planning in stereotactic radiotherapy for stage I lung cancer. *Int J Radiat Oncol Biol Phys.* 2004 Nov 15;60(4):1283-90. *VU University Medical Center, Amsterdam, NL*

Timmerman R, Papiez L, McGarry R, Likes L, DesRosiers C, Frost S, Williams M. Extracranial stereotactic radioablation: results of a phase I study in medically inoperable stage I non-small cell lung cancer. *Chest*. 2003 Nov;124(5):1946-55. *Indiana University, Indianapolis, IN*

van Sornsen de Koste JR, Lagerwaard FJ, Nijssen-Visser MR, Graveland WJ, Senan S. Tumor location cannot predict the mobility of lung tumors: a 3D analysis of data generated from multiple CT scans. *Int J Radiat Oncol Biol Phys.* 2003 Jun 1;56(2):348-54. *VU University Medical Center, Amsterdam, NL*

de Koste JR, Lagerwaard FJ, de Boer HC, Nijssen-Visser MR, Senan S. Are multiple CT scans required for planning curative radiotherapy in lung tumors of the lower lobe? *Int J Radiat Oncol Biol Phys.* 2003 Apr 1;55(5):1394-9. *VU University Medical Center, Amsterdam, NL*

LIVER, PANCREAS & ADRENALS

Primary and Metastatic Liver Tumors

Palma DA, van Sörnsen de Koste JR, Verbakel WF, Senan S. A new approach to quantifying lung damage after stereotactic body radiation therapy. *Acta Oncol.* 2010 Dec 21. *VU University Medical Center, Amsterdam* [Epub ahead of print]

Rule W, Timmerman R, Tong L, Abdulrahman R, Meyer J, Boike T, Schwarz RE, Weatherall P, Chinsoo Cho L. Phase I Dose-Escalation Study of Stereotactic Body Radiotherapy in Patients With Hepatic Metastases. *Ann Surg Oncol*. 2010 Nov 3. *University of Texas Southwestern, Dallas*, [Epub ahead of print]

Rwigema JC, Heron DE, Parikh SD, Zeh HJ 3rd, Moser JA, Bahary N, Ashby K, Burton SA. Adjuvant Stereotactic Body Radiotherapy for Resected Pancreatic Adenocarcinoma with Close or Positive Margins. *J Gastrointest Cancer*. 2010 Sep 1. *University of Pittsburgh School of Medicine, Pittsburgh, PA* [Epub ahead of print]

Bignardi M, Navarria P, Mancosu P, Cozzi L, Fogliata A, Tozzi A, Castiglioni S, Carnaghi C, Tronconi MC, Santoro A, Scorsetti M. Clinical Outcome of Hypofractionated Stereotactic Radiotherapy for Abdominal Lymph Node Metastases. *Int J Radiat Oncol Biol Phys.* 2010 Aug 26. *Istituto Clinico Humanitas, Rozzano, Italy*. [Epub ahead of print]

Torok J, Wegner RE, Burton SA, Heron DE. Stereotactic body radiation therapy for adrenal metastases: a retrospective review of a noninvasive therapeutic strategy. *Future Oncol.* 2011 Jan;7(1):145-51. *University of Pittsburgh Cancer Institute, Pittsburgh, PA*

Iwata H, Shibamoto Y, Hashizume C, Mori Y, Kobayashi T, Hayashi N, Kosaki K, Ishikawa T, Kuzuya T, Utsunomiya S. Hypofractionated stereotactic body radiotherapy for primary and metastatic liver tumors using the novalis image-guided system: preliminary results regarding efficacy and toxicity. *Technol Cancer Res Treat.* 2010 Dec;9(6):619-27.*Nagoya City University Graduate School of Medical Sciences, Nagoya, JP*

Murphy JD, Christman-Skieller C, Kim J, Dieterich S, Chang DT, Koong AC. A dosimetric model of duodenal toxicity after stereotactic body radiotherapy for pancreatic cancer. *Int J Radiat Oncol Biol Phys.* 2010 Dec 1;78(5):1420-6. *Stanford University School of Medicine, Stanford, CA*

Eppinga W, Lagerwaard F, Verbakel W, Slotman B, Senan S. Volumetric modulated arc therapy for advanced pancreatic cancer. *Strahlenther Onkol*. 2010 Jul;186(7):382-7. *VU University Medical Center, Amsterdam, NL*

Sawrie SM, Fiveash JB, Caudell JJ. Stereotactic body radiation therapy for liver metastases and primary hepatocellular carcinoma: normal tissue tolerances and toxicity. *Cancer Control*. 2010 Apr;17(2):111-9 *University of Alabama*

Kopek N, Holt MI, Hansen AT, Høyer M. Stereotactic body radiotherapy for unresectable cholangiocarcinoma. *Radiother Oncol.* 2010 Jan;94(1):47-52. *Aarhus University Hospital, Aarhus C, Denmark*

Al Hamad AA, Hassanain M, Michel RP, Metrakos P, Roberge D. Stereotactic radiotherapy of the liver: a bridge to transplantation stereotactic radiotherapy of the liver: a bridge to transplantation. *Technol Cancer Res Treat.* 2009 Dec;8(6):401-5. *McGill University Health Center, Montreal*

Chawla S, Chen Y, Katz AW, Muhs AG, Philip A, Okunieff P, Milano MT. Stereotactic body radiotherapy for treatment of adrenal metastases. *Int J Radiat Oncol Biol Phys.* 2009 Sep 1;75(1):71-5, *University of Rochester, Rochester, NY*

Rusthoven KE, Kavanagh BD, Cardenes H, Stieber VW, Burri SH, Feigenberg SJ, Chidel MA, Pugh TJ, Franklin W, Kane M, Gaspar LE, Schefter TE. Multi-institutional phase I/II trial of stereotactic body radiation therapy for liver metastases. *J Clin Oncol.* 2009 Apr 1;27(10):1572-8. *University of Colorado, Denver*

Olsen CC, Welsh J, Kavanagh BD, Franklin W, McCarter M, Cardenes HR, Gaspar LE, Schefter TE. Microscopic and macroscopic tumor and parenchymal effects of liver stereotactic body radiotherapy. *Int J Radiat Oncol Biol Phys.* 2009 Apr 1;73(5):1414-24., *University of Colorado, Denver*

McCammon R, Schefter TE, Gaspar LE, Zaemisch R, Gravdahl D, Kavanagh B. Observation of a dosecontrol relationship for lung and liver tumors after stereotactic body radiation therapy. *Int J Radiat Oncol Biol Phys*. 2009 Jan 1;73(1):112-8. *University of Colorado Health Sciences Center, Aurora*

Wu QJ, Thongphiew D, Wang Z, Chankong V, Yin FF. The impact of respiratory motion and treatment technique on stereotactic body radiation therapy for liver cancer. *Med Phys.* 2008 Apr;35(4):1440-51. *Duke University Medical Center Durham*

Kavanagh BD, Schefter TE, Wersäll PJ. Liver, renal, and retroperitoneal tumors: stereotactic radiotherapy. *Front Radiat Ther Oncol.* 2007;40:415-26. *University of Colorado Comprehensive Cancer Center, Aurora*

Katz AW, Carey-Sampson M, Muhs AG, Milano MT, Schell MC, Okunieff P. Hypofractionated stereotactic body radiation therapy (SBRT) for limited hepatic metastases. *Int J Radiat Oncol Biol Phys.* 2007 Mar 1;67(3):793-8. *University of Rochester Medical Center, Rochester, NY*

Kavanagh BD, Schefter TE, Cardenes HR, Stieber VW, Raben D, Timmerman RD, McCarter MD, Burri S, Nedzi LA, Sawyer TE, Gaspar LE. Interim analysis of a prospective phase I/II trial of SBRT for liver metastases. *Acta Oncol.* 2006;45(7):848-55. *University of Colorado Health Sciences Center, Aurora*

Wurm RE, Gum F, Erbel S, Schlenger L, Scheffler D, Agaoglu D, Schild R, Gebauer B, Rogalla P, Plotkin M, Ocran K, Budach V. Image guided respiratory gated hypofractionated Stereotactic Body Radiation Therapy (H-SBRT) for liver and lung tumors: Initial experience. *Acta Oncol*. 2006;45(7):881-9. *Charité- Universitätsmedizin, Berlin*

Schefter TE, Kavanagh BD, Timmerman RD, Cardenes HR, Baron A, Gaspar LE. A phase I trial of stereotactic body radiation therapy (SBRT) for liver metastases. *Int J Radiat Oncol Biol Phys.* 2005 Aug 1;62(5):1371-8. *University of Colorado Health Sciences Center, Aurora*

Fuss M, Thomas CR Jr. Stereotactic body radiation therapy: an ablative treatment option for primary and secondary liver tumors. *Ann Surg Oncol.* 2004 Feb;11(2):130-8. *The University of Texas Health Science Center at San Antonio, San Antonio,*

Gunven P, Blomgren H, Lax I. Radiosurgery for recurring liver metastases after hepatectomy. *Hepatogastroenterology*. 2003 Sep-Oct;50(53):1201-4. *Karolinska, SW*

PROSTATE, KIDNEY and GU

Primary and Metastatic Liver Tumors

Teh BS, Ishiyama H, Mathews T, Xu B, Butler EB, Mayr NA, Lo SS, Lu JJ, Blanco AI, Paulino AC, Timmerman RD Stereotactic body radiation therapy (SBRT) for genitourinary malignancies. *Discov Med.* 2010 Sep;10(52):255-62. *The Methodist Hospital, Houston, Texas*

Zhang P, Happersett L, Hunt M, Jackson A, Zelefsky M, Mageras G. Volumetric Modulated Arc Therapy: Planning and Evaluation for Prostate Cancer Cases. *Int J Radiat Oncol Biol Phys*. 2010 Apr;76(5):1456-62. *Memorial Sloan-Kettering Cancer Center, New York, NY*

Weber DC, Wang H, Cozzi L, Dipasquale G, Khan HG, Ratib O, Rouzaud M, Vees H, Zaidi H, Miralbell R. RapidArc, intensity modulated photon and proton techniques for recurrent prostate cancer in previously irradiated patients: a treatment planning comparison study. *Radiat Oncol.* 2009 Sep 9;4(1):34. *Hôpitaux Universitaires de Genève, Genève, Switzerland*

Shaffer R, Morris WJ, Moiseenko V, Welsh M, Crumley C, Nakano S, Schmuland M, Pickles T, Otto K. Volumetric modulated Arc therapy and conventional intensity-modulated radiotherapy for simultaneous maximal intraprostatic boost: a planning comparison study. *Clin Oncol (R Coll Radiol).* 2009 Jun;21(5):401-7. *British Columbia Cancer Agency, Vancouver, British Columbia, Canada.*

Kjaer-Kristoffersen F, Ohlhues L, Medin J, Korreman S. RapidArc volumetric modulated therapy planning for prostate cancer patients. *Acta Oncol.* 2009;48(2):227-32. *Rigshospitalet, Copenhagen, DK*

Palma D, Vollans E, James K, Nakano S, Moiseenko V, Shaffer R, McKenzie M, Morris J, Otto K. Volumetric modulated arc therapy for delivery of prostate radiotherapy: comparison with intensity-modulated radiotherapy and three-dimensional conformal radiotherapy. *Int J Radiat Oncol Biol Phys.* 2008 Nov 15;72(4):996- 1001. *British Columbia Cancer Agency, Vancouver, British Columbia, Canada.*

Kupelian PA, Langen KM, Willoughby TR, Zeidan OA, Meeks SL. Image-guided radiotherapy for localized prostate cancer: treating a moving target. *Semin Radiat Oncol.* 2008 Jan;18(1):58-66. Review. *Anderson Cancer Center Orlando*

Alonso-Arrizabalaga S, Brualla González L, Roselló Ferrando JV, Pastor Peidro J, López Torrecilla J, Planes Meseguer D, García Hernández T. Prostate Planning Treatment Volume Margin Calculation Based on the ExacTrac X-Ray 6D Image-Guided System: Margins for Various Clinical Implementations, *Int J Radiat Oncol Biol Phys.* 2007 Nov 1, 69(3):936-943. *Hospital General Universitario, Valencia, SP*

Hsu A, Pawlicki T, Luxton G, Hara W, King CR. A study of image-guided intensity-modulated radiotherapy with fiducials for localized prostate cancer including pelvic lymph nodes. *Int J Radiat Oncol Biol Phys.* 2007 Jul 1;68(3):898-902. *Stanford University Medical Center, Palo Alto*

Litzenberg DW, Willoughby TR, Balter JM, Sandler HM, Wei J, Kupelian PA, Cunningham AA, Bock A, Aubin M, Roach M 3rd, Shinohara K, Pouliot J. Positional stability of electromagnetic transponders used for prostate localization and continuous, real-time tracking. *Int J Radiat Oncol Biol Phys.* 2007 Jul 15;68(4):1199-206. *University of Michigan, Ann Arbor*

Pawlicki T, Kim GY, Hsu A, Cotrutz C, Boyer AL, Xing L, King CR, Luxton G. Investigation of linac-based image-guided hypofractionated prostate radiotherapy. *Med Dosim.* 2007 Summer;32(2):71-9. *Stanford University Medical Center, Palo Alto*

Pawlicki T, Cotrutz C, King C. Prostate cancer therapy with stereotactic body radiation therapy. *Front Radiat Ther Oncol*. 2007;40:395-406. *Stanford University Medical Center, Palo Alto, CA*

Linthout N, Verellen D, Tournel K, Reynders T, Duchateau M, Storme G. Assessment of secondary patient motion induced by automated couch movement during on-line 6 dimensional repositioning in prostate cancer treatment. *Radiother Oncol.* 2007 May;83(2):168-74. *Universitair Ziekenhuis Brussel, BE*

Madsen BL, Hsi RA, Pham HT, Fowler JF, Esagui L, Corman J Int J Radiat Oncol Biol Phys. 2007 Mar 15;67(4):1099-105. Stereotactic hypofractionated accurate radiotherapy of the prostate (SHARP), 33.5 Gy in five fractions for localized disease: first clinical trial results. *Int J Radiat Oncol Biol Phys*. 2007 Mar 15;67(4):1099-105, *Virginia Mason Medical Center, Seattle*

Kupelian P, Willoughby T, Mahadevan A, Djemil T, Weinstein G, Jani S, Enke C, Solberg T, Flores N, Liu D, Beyer D, Levine L. Multi-institutional clinical experience with the calypso system in localization and continuous, real-time monitoring of the prostate gland during external radiotherapy. *Int J Radiat Oncol Biol Phys.* 2007 Mar 15;67(4):1088-98. *MD Anderson Cancer Center Orlando, Orlando*

Soete G, De Cock M, Verellen D, Michielsen D, Keuppens F, Storme G. X-ray-assisted positioning of patients treated by conformal arc radiotherapy for prostate cancer: Comparison of setup accuracy using implanted markers versus bony structures. *Int J Radiat Oncol Biol Phys.* 2007 Mar 1;67(3):823-7. *Academic Hospital Free University of Brussels, Brussels*

Fuller CD, Thoas CR, Schwartz S, Golden N, Ting J, Wong A, Erdogmus D, Scarbrough TJ. Method comparison of ultrasound and kilovoltage x-ray fiducial marker imaging for prostate radiotherapy targeting. *Phys Med Biol*. 2006 Oct 7;51(19):4981-93. *University of Texas Health Science Center, San Antonio, TX*

Willoughby TR, Kupelian PA, Pouliot J, Shinohara K, Aubin M, Roach M 3rd, Skrumeda LL, Balter JM, Litzenberg DW, Hadley SW, Wei JT, Sandler HM. Target localization and real-time tracking using the Calypso 4D localization system in patients with localized prostate cancer. *Int J Radiat Oncol Biol Phys*. 2006 Jun 1;65(2):528-34. *MD Anderson Cancer Center Orlando, Orlando*

Kupelian PA, Willoughby TR, Meeks SL, Forbes A, Wagner T, Maach M, Langen KM. Intraprostatic fiducials for localization of the prostate gland: monitoring intermarker distances during radiation therapy to test for marker stability. *Int J Radiat Oncol Biol Phys.* 2005 Aug 1;62(5):1291-6. *Anderson Cancer Center Orlando, Orlando*

Madsen BL, Hsi RA, Pham HT, Presser J, Esagui L, Corman J, Myers L, Jones D. Intrafractional stability of the prostate using a stereotactic radiotherapy technique. *Int J Radiat Oncol Biol Phys.* 2003 Dec 1;57(5):1285-91. *Virginia Mason Medical Center, Seattle, WA*

Lukka H, Pickles T, Morton G, Catton C, Souhami L, Warde P; Canadian GU Radiation Oncologist Group. Prostate cancer radiotherapy 2002: the way forward. *Can J Urol.* 2005 Feb;12(1):2521-31. *Juravinski Cancer Centre, Hamilton, Ontario*

Geinitz H, Zimmermann FB, Kuzmany A, Kneschaurek P. Daily CT planning during boost irradiation of prostate cancer. Feasibility and time requirements. *Strahlenther Onkol.* 2000 Sep;176(9):429-32 *Universität München, Munich, DE*

EXTRACRANIAL DISEASE – MIXED CLINICAL TARGETS

Extracranial and NonCNS Cranial - Other

Jhaveri P, Teh BS, Bloch C, Amato R, Butler EB, Paulino AC. Stereotactic body radiotherapy in the management of painful bone metastases. Oncology (Williston Park). 2008 Jun;22(7):782-8; discussion 788-9, 796-7 *Methodist Hospital Research Institute and Baylor College of Medicine, Houston*

Teh BS, Paulino AC, Lu HH, Chiu JK, Richardson S, Chiang S, Amato R, Butler EB, Bloch C. Versatility of the Novalis System to Deliver Image-Guided Stereotactic Body Radiation Therapy (SBRT) for Various Anatomical Sites. *Technol Cancer Res Treat.* 2007 Aug;6(4):347-54. *Methodist Hospital Research Institute and Baylor College of Medicine, Houston*

Saw CB, Heron DE, Huq MS. Image-guided radiation therapy: part 3 - stereotactic body radiation therapy. *Med Dosim*. 2007 Summer;32(2):69-70. *University of Pittsburgh Medical Center*

Timmerman RD, Kavanagh BD, Cho LC, Papiez L, Xing L. Stereotactic body radiation therapy in multiple organ sites. *J Clin Oncol*. 2007 Mar 10;25(8):947-52. *University of Texas Southwestern Medical Center, Dallas*

Hoyer M, Roed H, Traberg Hansen A, Ohlhuis L, Petersen J, Nellemann H, Kiil Berthelsen A, Grau C, Aage Engelholm S, Von der Maase H. Phase II study on stereotactic body radiotherapy of colorectal metastases. *Acta Oncol*. 2006;45(7):823-30. *Aarhus University Hospital, Aarhus, Denmark*

Kavanagh BD, McGarry RC, Timmerman RD. Extracranial radiosurgery (stereotactic body radiation therapy) for oligometastases. *Semin Radiat Oncol*. 2006 Apr;16(2):77-84. *University of Colorado Health Sciences Center, Aurora*

Korreman SS, Pedersen AN, Nøttrup TJ, Specht L, Nyström H. Breathing adapted radiotherapy for breast cancer: comparison of free breathing gating with the breath-hold technique. *Radiother Oncol.* 2005 Sep; 76(3):311-8. *Rigshospitalet, Copenhagen, DE*

GENERAL RADIOSURGERY & SBRT

General Applications of Radiosurgery and Stereotactic Body Radiotherapy

Verbakel WF, Lagerwaard FJ, Verduin AJ, Heukelom S, Slotman BJ, Cuijpers JP. The accuracy of frameless stereotactic intracranial radiosurgery. *Radiother Oncol.* 2010 Nov 1. *VU University Medical Center, Amsterdam, The Netherlands.* [Epub ahead of print]

Roos DE, Brophy BP, Taylor J. Lessons from a 17-Year Radiosurgery Experience at the Royal Adelaide Hospital. *Int J Radiat Oncol Biol Phys.* 2010 Oct 30. *University of Adelaide, Royal Adelaide Hospital, Adelaide, South Australia.* [Epub ahead of print]

Tanyi JA, Kato CM, Chen Y, Chen Z, Fuss M. Impact of the high-definition multileaf collimator on linear accelerator-based intracranial stereotactic radiosurgery. *Br J Radiol*. 2010 Oct 5. *Oregon Health and Science University, Portland* [Epub ahead of print]

Geneser SE, Hinkle JD, Kirby RM, Wang B, Salter B, Joshi S. Quantifying variability in radiation dose due to respiratory-induced tumor motion. *Med Image Anal.* 2010 Jul 14. *University of Utah*, *Salt Lake City, UT* [Epub ahead of print]

Benedict SH, Yenice KM, Followill D, Galvin JM, Hinson W, Kavanagh B, Keall P, Lovelock M, Meeks S, Papiez L, Purdie T, Sadagopan R, Schell MC, Salter B, Schlesinger DJ, Shiu AS, Solberg T, Song DY, Stieber V, Timmerman R, Tomé WA, Verellen D, Wang L, Yin FF. Stereotactic body radiation therapy: the report of AAPM Task Group 101. *Med Phys*. 2010 Aug;37(8):4078-101. *University of Virginia Health System, Charlottesville, Virginia*

Brown JM, Diehn M, Loo BW Jr.Stereotactic ablative radiotherapy should be combined with a hypoxic cell radiosensitizer. *Int J Radiat Oncol Biol Phys*. 2010 Oct 1;78(2):323-7. *Stanford University School of Medicine, CA*

Dhabaan A, Elder E, Schreibmann E, Crocker I, Curran WJ, Oyesiku NM, Shu HK, Fox T. Dosimetric performance of the new high-definition multileaf collimator for intracranial stereotactic radiosurgery. *J Appl Clin Med Phys.* 2010 Jun 21;11(3):3040 *Emory University, Atlanta*

Schoonbeek A, Monshouwer R, Hanssens P, Raaijmakers E, Nowak P, Marijnissen JP, Lagerwaard FJ, Cuijpers JP, Vonk EJ, van der Maazen RW. Intracranial radiosurgery in the Netherlands. A planning comparison of available systems with regard to physical aspects and workload. *Technol Cancer Res Treat.* 2010 Jun;9(3):279-90 *Radboud University Nijmegen Medical Centre, Nijmegen* and *VU Amsterdam.*

Ramakrishna N, Rosca F, Friesen S, Tezcanli E, Zygmanszki P, Hacker F. A clinical comparison of patient setup and intra-fraction motion using frame-based radiosurgery versus a frameless image-guided radiosurgery system for intracranial lesions. *Radiother Oncol.* 2010 Apr;95(1):109-15 *Brigham and Women's Hospital and Dana Farber Cancer Institute, Boston, MA*

Cerviño LI, Pawlicki T, Lawson JD, Jiang SB. Frame-less and mask-less cranial stereotactic radiosurgery: a feasibility study. *Phys Med Biol.* 2010 Apr 7;55(7):1863-73 *University of California San Diego, La Jolla, CA*

Milano MT, Katz AW, Okunieff P. Patterns of Recurrence After Curative-Intent Radiation for Oligometastases Confined to One Organ. *Am J Clin Oncol*. 2010 Apr;33(2):157-63 *University of Rochester Medical Center, Rochester, New York*

Rahman M, Murad GJ, Bova F, Friedman WA, Mocco J. Stereotactic radiosurgery and the linear accelerator: accelerating electrons in neurosurgery. *Neurosurg Focus.* 2009 Sep;27(3):E13. *University of Florida, Gainesville*

Sahgal A, Ma L, Chang E, Shiu A, Larson DA, Laperriere N, Yin FF, Tsao M, Menard C, Basran PS, Létourneau D, Heydarian M, Beachey D, Shukla V, Cusimano M, Hodaie M, Zadeh G, Bernstein M, Schwartz M. Advances in technology for intracranial stereotactic radiosurgery. *Technol Cancer Res Treat.* 2009 Aug;8(4):271-80. includes *Duke University Medical Center, Durham, NC*

Lamba M, Breneman JC, Warnick RE. Evaluation of Image-Guided Positioning for Frameless Intracranial Radiosurgery. *Int J Radiat Oncol Biol Phys*. 2009 Jul 1;74(3):913-9. *University of Cincinnati Neuroscience Institute, Cincinnati, OH*

Lo SS, Fakiris AJ, Teh BS, Cardenes HR, Henderson MA, Forquer JA, Papiez L, McGarry RC, Wang JZ, Li K, Mayr NA, Timmerman RD. Stereotactic body radiation therapy for oligometastases. *Expert Rev Anticancer Ther*. 2009 May;9(5):621-35 Includes *Methodist Hospital Research Institute and Baylor College of Medicine, Houston*

Timmerman RD, Bizekis CS, Pass HI, Fong Y, Dupuy DE, Dawson LA, Lu D. Local surgical, ablative, and radiation treatment of metastases. *CA Cancer J Clin.* 2009 May-Jun;59(3):145-70. Review. *University of Texas Southwestern, Dallas*

Wang JZ, Rice R, Pawlicki T, Mundt AJ, Sandhu A, Lawson J, Murphy KT. Evaluation of patient setup uncertainty of optical guided frameless system for intracranial stereotactic radiosurgery. *J Appl Clin Med Phys.* 2010 Apr 17;11(2):3181 *UCSD, San Diego*

Lawson JD, Fox T., Waller AF., Davis L, Crocker I. Multileaf Collimator-Based Linear Accelerator Radiosurgery: Five-Year Efficiency Analysis *Journal of the American College of Radiology,* 2009 Mar 6(3):190-193. *Emory University, Atlanta,*

Bednarz G, Machtay M, Werner-Wasik M, Downes B, Bogner J, Hyslop T, Galvin J, Evans J, Curran W Jr, Andrews D. Report on a randomized trial comparing two forms of immobilization of the head for fractionated stereotactic radiotherapy. *Med Phys.* 2009 Jan;36(1):12-7 *Jefferson Medical College, Philadelphia, PA*

Wu QJ, Wang Z, Kirkpatrick JP, Chang Z, Meyer JJ, Lu M, Huntzinger C, Yin FF. Impact of collimator leaf width and treatment technique on stereotactic radiosurgery and radiotherapy plans for intra- and extracranial lesions. *Radiat Oncol*. 2009 Jan 21;4(1):3. *Duke University, Durham, NC*

Kavanagh B. Clinical experience shows that catastrophic late effects associated with ablative fractionation can be avoided by technological innovation. *Semin Radiat Oncol*. 2008 Oct;18(4):223-8. *University of Colorado, Denver*

Timmerman RD. An overview of hypofractionation and introduction to this issue of seminars in radiation oncology. *Semin Radiat Oncol* 2008 Oct;18(4):215-22 *University of Texas Southwestern, Dallas*

Nedzi LA.The implementation of ablative hypofractionated radiotherapy for stereotactic treatments in the brain and body: observations on efficacy and toxicity in clinical practice. *Semin Radiat Oncol*. 2008 Oct;18(4):265-72. *University of Texas Southwestern, Dallas*

Kirkpatrick JP, Meyer JJ, Marks LB. The linear-quadratic model is inappropriate to model high dose per fraction effects in radiosurgery. *Semin Radiat Oncol*. 2008 Oct;18(4):240-3. *Duke University Medical Center, Raleigh*

Jensen RL, Wendland MM, Chern SS, Shrieve DC. Novalis intensity-modulated radiosurgery: methods for pretreatment planning. *Neurosurgery*. 2008 May;62(5 Suppl):A2-10. *University of Utah Health Sciences Center, Salt Lake City*

Wurm RE, Erbel S, Schwenkert I, Gum F, Agaoglu D, Schild R, Schlenger L, Scheffler D, Brock M, Budach V. Novalis frameless image-guided noninvasive radiosurgery: initial experience. *Neurosurgery*. 2008 May;62(5 Suppl):A11-8; *Charité-Universitätsmedizin Berlin*

De Salles AA, Gorgulho AA, Selch M, De Marco J, Agazaryan N. Radiosurgery from the brain to the spine: 20 years experience. *Acta Neurochir Suppl.* 2008;101:163-8. *UCLA, Los Angeles*

Papiez L, Timmerman R. Hypofractionation in radiation therapy and its impact. *Med Phys.* 2008 Jan;35(1):112-8. *University of Texas Southwestern Medical Center, Dallas*

Yin FF, Wang Z, Yoo S, Wu QJ, Kirkpatrick J, Larrier N, Meyer J, Willett CG, Marks LB. Integration of Cone- Beam CT in Stereotactic Body Radiation Therapy. *Duke University Medical Center, Durham NC Technol Cancer Res Treat.* 2008 Apr;7(2):133-40.

Park C, Papiez L, Zhang S, Story M, Timmerman RD. Universal survival curve and single fraction equivalent dose: useful tools in understanding potency of ablative radiotherapy. Int J Radiat Oncol Biol Phys. 2008 Mar1;70(3):847-52. *University of Texas Southwestern Medical Center, Dallas*

Chang BK, Timmerman RD. Stereotactic body radiation therapy: a comprehensive review. Am J Clin Oncol. 2007 Dec;30(6):637-44. Review. *University of Texas Southwestern Medical Center, Dallas*

Chen JC, Rahimian J, Girvigian MR, Miller MJ. Contemporary methods of radiosurgery treatment with the Novalis linear accelerator system. *Neurosurg Focus*. 2007;23(6):E4. *Southern California Permanente Medical Group, Los Angeles*

Teh BS, Paulino AC, Lu HH, Chiu JK, Richardson S, Chiang S, Amato R, Butler EB, Bloch C. Versatility of the Novalis system to deliver image-guided stereotactic body radiation therapy (SBRT) for various anatomical sites. *Technol Cancer Res Treat.* 2007 Aug;6(4):347-54. *The Methodist Hospital Research Institute and Baylor College of Medicine, Houston*

Huntzinger C, Friedman W, Bova F, Fox T, Bouchet L, Boeh L. Trilogy image-guided stereotactic radiosurgery. *Med Dosim*. 2007 Summer;32(2):121-33. *University of Florida, Gainesville & Varian, Palo Alto*

Timmerman RD, Kavanagh BD, Cho LC, Papiez L, Xing L. Stereotactic body radiation therapy in multiple organ sites. *J Clin Oncol.* 2007 Mar 10;25(8):947-52. *University of Texas Southwestern Medical Center, Dallas*

Andrews DW, Bednarz G, Evans JJ, Downes B. A review of 3 current radiosurgery systems. *Surg Neurol*. 2006 Dec;66(6):559-64. *Thomas Jefferson University Hospital, Philadelphia*

Kavanagh BD, Timmerman RD. Stereotactic radiosurgery and stereotactic body radiation therapy: an overview of technical considerations and clinical applications. *Hematol Oncol Clin North Am*. 2006 Feb;20(1):87. *Univ of Colorado, Denver*

Whang CJ, Yee GT, Choi CY, Sohn MJ, Lee DJ. First experience in using Novalis shaped beam radiosurgery in Korea. *J Neurosurg.* 2004 Nov;101 Suppl 3:341-5. *Inje University, Gyoung gi, KR*

Solberg TD, Goetsch SJ, Selch MT, Melega W, Lacan G, DeSalles AA. Functional stereotactic radiosurgery involving a dedicated linear accelerator and gamma unit: a comparison study. *J Neurosurg*. 2004 Nov;101 Suppl 3:373-80. *UCLA, Los Angeles*

Shrieve DC, Klish M, Wendland MM, Watson GA. Basic principles of radiobiology, radiotherapy, and radiosurgery. *Neurosurg Clin N Am.* 2004 Oct;15(4):467-79,. Review. *University of Utah, Salt Lake City*

Law E, Mangarin E, Kelvin JF. Nursing management of patients receiving stereotactic radiosurgery. *Clin J Oncol Nurs.* 2003 Jul-Aug;7(4):387-92. *Memorial Sloan-Kettering Cancer Center, NYC*

Timmerman R, Papiez L, Suntharalingam M. Extracranial stereotactic radiation delivery: expansion of technology beyond the brain. *Technol Cancer Res Treat*. 2003 Apr;2(2):153-60. Review. *Indiana University, Indianapolis*

Stieber VW, Bourland JD, Tome WA, Mehta MP. Gentlemen (and ladies), choose your weapons: Gamma knife vs. linear accelerator radiosurgery. *Technol Cancer Res Treat.* 2003 Apr;2(2):79-86. *Wake Forest University, Winston-Salem, NC*

Papiez L, Timmerman R, DesRosiers C, Randall M. Extracranial stereotactic radioablation: physical principles. *Acta Oncol.* 2003;42(8):882-94, *Indiana University, Indianapolis*

Bova FJ, Goetsch SJ. Modern linac stereotactic radiosurgery systems have rendered the Gamma Knife obsolete. *Med Phys. 2001* Sep;28(9):1839-41. *University of Florida, Gainesville*

Buatti JM, Meeks SL, Friedman WA, Bova FJ**.** Stereotactic radiosurgery: techniques and clinical applications. *Surg Oncol Clin N Am.* 2000 Jul;9(3):469-87, *University of Florida, Gainesville*

Joensuu H. Novel cancer therapies: more efficacy, less toxicity and improved organ preservation. *Ann Med.* 2000 Feb;32(1):31-3. *Helsinki University Central Hospital, Finland*

Buatti JM, Meeks SL, Friedman WA, Bova FJ**.** Stereotactic radiosurgery: techniques and clinical applications. *Surg Oncol Clin N Am.* 2000 Jul;9(3):469-87, *University of Florida, Gainesville*

Buatti JM, Bova FJ, Friedman WA, Meeks SL, Marcus RB Jr, Mickle JP, Ellis TL, Mendenhall WM. Preliminary experience with frameless stereotactic radiotherapy. *Int J Radiat Oncol Biol Phys.* 1998 Oct 1;42(3):591-9. *University of Florida, Gainesville*

Meeks SL, Bova FJ, Friedman WA, Buatti JM, Mendenhall WM. Linac scalpel radiosurgery at the University of Florida. *Med Dosim.* 1998 Fall;23(3):177-85. *University of Florida, Gainesville*

Bova FJ, Buatti JM, Friedman WA, Mendenhall WM, Yang CC, Liu C. The University of Florida frameless high-precision stereotactic radiotherapy system. *Int J Radiat Oncol Biol Phys.* 1997 Jul 1;38(4):875-82. *University of Florida, Gainesville.*

Das IJ, Downes MB, Corn BW, Curran WJ, Werner-Wasik M, Andrews DW. Characteristics of a dedicated linear accelerator-based stereotactic radiosurgery-radiotherapy unit. *Radiother Oncol*. 1996 Jan;38(1):61-8. *Fox Chase Cancer Center, Philadelphia*

Friedman WA, Bova FJ, Spiegelmann R. Linear accelerator radiosurgery at the University of Florida., *Neurosurg Clin N Am*. 1992 Jan;3(1):141-66. *University of Florida, Gainesville.*

Friedman WA. Linear accelerator radiosurgery., *Clin Neurosurg.* 1992;38:445-71. Review *University of Florida, Gainesville.*

TECHNICAL

Tumor Targeting & Treatment Accuracy & Delivery Speed

Verbakel WF, Lagerwaard FJ, Verduin AJ, Heukelom S, Slotman BJ, Cuijpers JP. The accuracy of frameless stereotactic intracranial radiosurgery. *Radiother Oncol*. 2010 Dec;97(3):390-4. *VU University Medical Center, Amsterdam, The Netherlands*

Ali I, Tubbs J, Hibbitts K, Algan O, Thompson S, Herman T, Ahmad S. Evaluation of the setup accuracy of a stereotactic radiotherapy head immobilization mask system using kV on-board imaging. *J Appl Clin Med Phys.* 2010 May 20;11(3):3192 *University of Oklahoma Health Sciences Center, Oklahoma City, OK*

Linthout N, Bral S, Van de Vondel I, Verellen D, Tournel K, Gevaert T, Duchateau M, Reynders T, Storme G. Treatment delivery time optimization of respiratory gated radiation therapy by application of audio-visual feedback. *Radiother Oncol*. 2009 Jun;91(3):330-5. *Universitair Ziekenhuis Brussel, Belgium*

Hazard LJ, Wang B, Skidmore TB, Chern SS, Salter BJ, Jensen RL, Shrieve DC. Conformity of Linear Accelerator-based Stereotactic Radiosurgery Using Dynamic Conformal Arcs or Intensity Modulation and Micro- Multileaf Collimator. *Int J Radiat Oncol Biol Phys*. 2009 Feb 1;73(2):562-70 *University of Utah, Salt Lake City*

Zimmerman J, Korreman S, Persson G, Cattell H, Svatos M, Sawant A, Venkat R, Carlson D, Keall P. DMLC motion tracking of moving targets for intensity modulated arc therapy treatment: a feasibility study. *Acta Oncol.* 2009;48(2):245-50. *Rigshospitalet, University of Copenhagen, Copenhagen, DK*

Hayashi N, Uchiyama Y, Mori Y, Hashizume C, Kobayashi T, Yamada M, Obata Y. [Evaluation of patient setup accuracy with Novalis system in stereotactic radiosurgery] *Nippon Hoshasen Gijutsu Gakkai Zasshi.* 2008 Jan 20;64(1):117-9. *Nagoya Kyoritsu Hospital, Japan*

Chang J, Yenice KM, Narayana A, Gutin PH. Accuracy and feasibility of cone-beam computed tomography for stereotactic radiosurgery setup. *Med Phys.* 2007 Jun;34(6):2077-84. *Memorial Sloan-Kettering Cancer Center, New York*

Jin L, Wang L, Li J, Luo W, Feigenberg SJ, Ma CM. Investigation of optimal beam margins for stereotactic radiotherapy of lung-cancer using Monte Carlo dose calculations. *Phys Med Biol.* 2007 Jun 21;52(12):3549- 61. *Fox Chase Cancer Center, Philadelphia*

Hansen AT, Petersen JB, Hoyer M. Internal movement, set-up accuracy and margins for stereotactic body radiotherapy using a stereotactic body frame. *Acta Oncol*. 2006;45(7):948-52, *Aarhus University Hospital, Aarhus, Denmark*

Tenn SE, Solberg TD, Medin PM. Targeting accuracy of an image guided gating system for stereotactic body radiotherapy. *Phys Med Biol*. 2005 Dec 7;50(23):5443-62. *UCLA, Los Angeles*

Underberg RW, Lagerwaard FJ, Cuijpers JP, Slotman BJ, van Sornsen de Koste JR, Senan S. Fourdimensional CT scans for treatment planning in stereotactic radiotherapy for stage I lung cancer. *Int J Radiat Oncol Biol Phys*. 2004 Nov 15;60(4):1283-90. *VU University Medical Center, Amsterdam, NL*

Solberg TD, Agazaryan N, Goss BW, Dahlbom M, Lee SP. A feasibility study of 18F-fluorodeoxyglucose positron emission tomography targeting and simultaneous integrated boost for intensity-modulated radiosurgery and radiotherapy. *J Neurosurg.* 2004 Nov;101 Suppl 3:381-9 *UCLA, Los Angeles*

Yan H, Yin FF, Kim JH. A phantom study on the positioning accuracy of the Novalis Body system. *Med Phys*. 2003 Dec;30(12):3052-60. *Henry Ford Hospital, Detroit*

Grosu AL, Lachner R, Wiedenmann N, Stärk S, Thamm R, Kneschaurek P, Schwaiger M, Molls M, Weber WA. Validation of a method for automatic image fusion (BrainLAB System) of CT data and 11C-methionine- PET data for stereotactic radiotherapy using a LINAC: first clinical experience. *Int J Radiat Oncol Biol Phys.* 2003 Aug 1;56(5):1450-63. *Technical University Munich, DE*

van Sörnsen de Koste JR, Lagerwaard FJ, Nijssen-Visser MR, Graveland WJ, Senan S. Tumor location cannot predict the mobility of lung tumors: a 3D analysis of data generated from multiple CT scans. *Int J Radiat Oncol Biol Phys.* 2003 Jun 1;56(2):348-54. *VU University Medical Center, Amsterdam, NL*

Ryken TC, Meeks SL, Pennington EC, Hitchon P, Traynelis V, Mayr NA, Bova FJ, Friedman WA, Buatti JM. Initial clinical experience with frameless stereotactic radiosurgery: analysis of accuracy and feasibility. *Int J Radiat Oncol Biol Phys.* 2001 Nov 15;51(4):1152-8. *University of Florida, Gainesville*

TECHNICAL

Image-Guidance

Liu W, Wiersma RD, Xing L. Optimized hybrid megavoltage-kilovoltage imaging protocol for volumetric prostate arc therapy. *Int J Radiat Oncol Biol Phys.* 2010 Oct 1;78(2):595-604. *Stanford University School of Medicine, California*

Chang Z, Wang Z, Ma J, O'Daniel JC, Kirkpatrick J, Yin FF. 6D image guidance for spinal non-invasive stereotactic body radiation therapy: Comparison between ExacTrac X-ray 6D with kilo-voltage cone-beam CT. *Radiother Oncol.* 2010 Apr;95(1):116-21 *Duke University Medical Center, Durham, NC*

Ma J, Chang Z, Wang Z, Jackie Wu Q, Kirkpatrick JP, Yin FF. ExacTrac X-ray 6 degree-of-freedom imageguidance for intracranial non-invasive stereotactic radiotherapy: Comparison with kilo-voltage cone-beam CT. *Radiother Oncol*. 2009 Dec;93(3):602-8. *Duke University Medical Center*

Park SJ, Ionascu D, Hacker F , Mamon H, Berbeco R. Automatic marker detection and 3D position reconstruction using cine EPID images for SBRT verification. *Med Phys*. 2009 Oct;36(10):4536-46.*Dana- Farber/Brigham and Women's Cancer Center, Harvard Medical School, Boston*, MA

Cho B, Poulsen PR, Sloutsky A, Sawant A, Keall PJ. First Demonstration of Combined kV/MV Image- Guided Real-Time Dynamic Multileaf-Collimator Target Tracking. *Int J Radiat Oncol Biol Phys.* 2009 Jul 1;74(3):859-867*. Stanford University Medical Center, Palo Alto, CA*

Arimura H, Egashira Y, Shioyama Y, Nakamura K, Yoshidome S, Anai S, Nomoto S, Honda H, Toyofuku F, Higashida Y, Onizuka Y, Terashima H. Computerized method for estimation of the location of a lung tumor on EPID cine images without implanted markers in stereotactic body radiotherapy. *Phys Med Biol.* 2009 Feb 7;54(3):665-77*. Kyushu University, Fukuoka, Japan.*

Riegel AC, Chang JY, Vedam SS, Johnson V, Chi PC, Pan T. Cine computed tomography without respiratory surrogate in planning stereotactic radiotherapy for non-small-cell lung cancer. *Int J Radiat Oncol Biol Phys*. 2009 Feb 1;73(2):433-41*. M.D. Anderson Cancer Center, Houston, TX*

Wang Z, Nelson JW, Yoo S, Wu QJ, Kirkpatrick JP, Marks LB, Yin FF. Refinement of treatment setup and target localization accuracy using three-dimensional cone-beam computed tomography for stereotactic body radiotherapy. *Int J Radiat Oncol Biol Phys.* 2009 Feb 1;73(2):571-7. *Duke University Medical Center, Durham, NC*

Hong LX, Chen CC, Garg M, Yaparpalvi R, Mah D. Clinical experiences with onboard imager KV images for linear accelerator-based stereotactic radiosurgery and radiotherapy setup. *Int J Radiat Oncol Biol Phys.* 2009 Feb 1;73(2):556-61. *Montefiore Medical Center, Bronx, NY*

Arimura H, Egashira Y, Shioyama Y, Nakamura K, Yoshidome S, Anai S, Nomoto S, Honda H, Toyofuku F, Higashida Y, Onizuka Y, Terashima H. Computerized method for estimation of the location of a lung tumor on EPID cine images without implanted markers in stereotactic body radiotherapy. *Phys Med Biol.* 2009 Feb 7;54(3):665-77. *Kyushu University, Fukuoka*

Jin JY, Yin FF, Tenn SE, Medin PM, Solberg TD Use of the BrainLAB ExacTrac X-Ray 6D system in imageguided radiotherapy. *Med Dosim.* 2008 Summer;33(2):124-34.

Wurm RE, Erbel S, Schwenkert I, Gum F, Agaoglu D, Schild R, Schlenger L, Scheffler D, Brock M, Budach V. Novalis frameless image-guided noninvasive radiosurgery: initial experience. *Neurosurgery*. 2008 May;62(5 Suppl):A11-7

Yin FF, Wang Z, Yoo S, Wu QJ, Kirkpatrick J, Larrier N, Meyer J, Willett CG, Marks LB. Integration of conebeam CT in stereotactic body radiation therapy. *Technol Cancer Res Treat*. 2008 Apr;7(2):133-9. *Duke University Medical Center, Raleigh-Durham*

Lee SW, Jin JY, Guan H, Martin F, Kim JH, Yin FF. Clinical assessment and characterization of a dual tube kilovoltage X-ray localization system in the radiotherapy treatment room. *J Appl Clin Med Phys.* 2008 Jan 13;9(1):2318. *Duke University Medical Center, Raleigh-Durham*

Poulsen PR, Muren LP, Høyer M.Residual set-up errors and margins in on-line image-guided prostate localization in radiotherapy. *Radiother Oncol*. 2007 Nov;85(2):201-6. *Aarhus University Hospital, Aarhus, DK*

van Sörnsen de Koste JR, Cuijpers JP, de Geest FG, Lagerwaard FJ, Slotman BJ, Senan S. Verifying 4D gated radiotherapy using time-integrated electronic portal imaging: a phantom and clinical study. *Radiat Oncol*. 2007 Aug 30;2:32. *VU University medical center, Amsterdam, The Netherlands*

Wang C, Shiu A, Lii M, Woo S, Chang EL. Automatic target localization and verification for on-line imageguided stereotactic body radiotherapy of the spine. *Technol Cancer Res Treat.* 2007 Jun;6(3):187-96. *The University of Texas, M. D. Anderson Cancer Center, Houston*

Berbeco RI, Hacker F, Ionascu D, Mamon HJ. Clinical Feasibility of Using an EPID in cine Mode for Image- Guided Verification of Stereotactic Body Radiotherapy. *Int J Radiat Oncol Biol Phys.* 2007 Sep 1;69(1):258- 66. *Brigham and Women's Cancer Center and Harvard Medical School, Boston*

D'Souza WD, Nazareth DP, Zhang B, Deyoung C, Suntharalingam M, Kwok Y, Yu CX, Regine WF. The use of gated and 4D CT imaging in planning for stereotactic body radiation therapy. *Med Dosim*. 2007 Summer; 32(2):92-101. *University of Maryland, Baltimore*

Saw CB, Yang Y, Li F, Yue NJ, Ding C, Komanduri K, Huq S, Heron DE. Performance characteristics and quality assurance aspects of kilovoltage cone-beam CT on medical linear accelerator. *Med Dosim*. 2007 Summer;32(2):80-5. *University of Pittsburgh Medical Center*

Li T, Xing L, Munro P, McGuinness C, Chao M, Yang Y, Loo B, Koong A. Four-dimensional cone-beam computed tomography using an on-board imager. *Med Phys.* 2006 Oct;33(10):3825-33. *Stanford University Medical Center, Palo Alto*

Kim J, Li S, Pradhan D, Hammoud R, Chen Q, Yin FF, Zhao Y, Kim JH, Movsas B. Comparison of similarity measures for rigid-body CT/Dual X-ray image registrations. *Technol Cancer Res Treat.* 2007 Aug;6(4):337- 46. *Duke University Medical Center, Durham, NC*

Soete G, De Cock M, Verellen D, Michielsen D, Keuppens F, Storme G. X-ray-assisted positioning of patients treated by conformal arc radiotherapy for prostate cancer: Comparison of setup accuracy using implanted markers versus bony structures. *Int J Radiat Oncol Biol Phys.* 2007 Mar 1;67(3):823-7. *Academic Hospital Free University of Brussels, Brussels*

Verellen D, Soete G, Linthout N, Tournel K, Storme G. Optimal control of set-up margins and internal margins for intra- and extracranial radiotherapy using stereoscopic kilovoltage imaging. *Cancer Radiother*. 2006 Sep;10(5):235-44. *Vrije Universiteit Brussel, BE.*

Soete G, Verellen D, Tournel K, Storme G. Setup accuracy of stereoscopic X-ray positioning with automated correction for rotational errors in patients treated with conformal arc radiotherapy for prostate cancer. *Radiother Oncol.* 2006 Sep;80(3):371-3. *Vrije Universiteit Brussel, BE.*

Saw CB, Heron DE, Yue NJ, Huq MS. Cone-beam imaging and respiratory motion (IGRT)-part II. *Med Dosim*. 2006 Summer;31(2):89-90. *University of Pittsburgh Medical Center.*

Yin FF, Das S, Kirkpatrick J, Oldham M, Wang Z, Zhou SM. Physics and imaging for targeting of oligometastases. *Semin Radiat Oncol.* 2006 Apr;16(2):85-101. *Duke University Medical Center, Raleigh-Durham*

Fox TH, Elder ES, Crocker IR, Davis LW, Landry JC, Johnstone PA. Clinical implementation and efficiency of kilovoltage image-guided radiation therapy. *J Am Coll Radiol.* 2006 Jan;3(1):38-44. *Emory University, Atlanta*

Miralbell R, Mollà M, Arnalte R, Canales S, Vargas E, Linero D, Waters S, Nouet P, Rouzaud M, Escudé L. Target repositioning optimization in prostate cancer: is intensity-modulated radiotherapy under stereotactic conditions feasible? *Int J Radiat Oncol Biol Phys.* 2004 Jun 1;59(2):366-71. *Instituto Oncológico Teknon, Barcelona, SP*

Meeks SL, Buatti JM, Bouchet LG, Bova FJ, Ryken TC, Pennington EC, Anderson KM, Friedman WA. Ultrasound-guided extracranial radiosurgery: technique and application. *Int J Radiat Oncol Biol Phys*. 2003 Mar 15;55(4):1092-101. *University of Florida, Gainesville*

Meeks SL, Bova FJ, Wagner TH, Buatti JM, Friedman WA, Foote KD. Image localization for frameless stereotactic radiotherapy. *Int J Radiat Oncol Biol* Phys. 2000 Mar 15;46(5):1291-9. *University of Florida, Gainesville,*

Bova FJ, Meeks SL, Friedman WA, Buatti JM. Optic-guided stereotactic radiotherapy. *Med Dosim.* 1998 Fall;23(3):221-8. *University of Florida, Gainesville*

Meeks SL, Bova FJ, Friedman WA, Buatti JM, Moore RD, Mendenhall WM. IRLED-based patient localization for linac radiosurgery. *Int J Radiat Oncol Biol Phys.* 1998 May 1;41(2):433-9. *University of Florida, Gainesville*

TECHNICAL

MOTION MANAGEMENT

Keall PJ, Sawant A, Cho B, Ruan D, Wu J, Poulsen P, Petersen J, Newell LJ, Cattell H, Korreman S. Electromagnetic- Guided Dynamic Multileaf Collimator Tracking Enables Motion Management for Intensity-Modulated Arc Therapy. *Int J Radiat Oncol Biol Phys*. 2011 Jan 1;79(1):312-20 *Stanford University Medical Center*

Peng JL, Kahler D, Li JG, Samant S, Yan G, Amdur R, Liu C. Characterization of a real-time surface imageguided stereotactic positioning system. *Med Phys*. 2010 Oct;37(10):5421-33. *Medical University of South Carolina, Charleston, South Carolina*

Verellen D, Depuydt T, Gevaert T, Linthout N, Tournel K, Duchateau M, Reynders T, Storme G, De Ridder M. Gating and tracking, 4D in thoracic tumours. *Cancer Radiother.* 2010 Oct;14(6-7):446-54. *UZ Brussel, Brussels*

Poulsen PR, Cho B, Ruan D, Sawant A, Keall PJ. Dynamic multileaf collimator tracking of respiratory target motion based on a single kilovoltage imager during arc radiotherapy. *Int J Radiat Oncol Biol Phys.* 2010 Jun 1;77(2):600-7. *Stanford University, Stanford, California*

Ramakrishna N, Rosca F, Friesen S, Tezcanli E, Zygmanszki P, Hacker F. A clinical comparison of patient setup and intra-fraction motion using frame-based radiosurgery versus a frameless image-guided radiosurgery system for intracranial lesions. *Radiother Oncol*. 2010 Apr;95(1):109-15. *Brigham and Women's Hospital and Dana Farber Cancer Institute, Boston, MA*

Park SJ, Ionascu D, Hacker F, Mamon H, Berbeco R. Automatic marker detection and 3D position reconstruction using cine EPID images f or SBRT verification. Med Phys. 2009 Oct;36(10):4536-46. *Dana- Farber/Brigham and Women's Cancer Center, Harvard Medical School, Boston, MA*

Zhao B, Yang Y, Li T, Li X, Heron DE, Huq MS. Image-guided respiratory-gated lung stereotactic body radiotherapy: which target definition is optimal? *Med Phys.* 2009 Jun;36(6):2248-57. *University of Pittsburgh*

Cho B, Poulsen PR, Sloutsky A, Sawant A, Keall PJ. First demonstration of combined kV/MV image-guided real-time dynamic multileaf-collimator target tracking. *Int J Radiat Oncol Biol Phys*. 2009 Jul 1;74(3):859- 867. *Stanford University, Stanford, CA*

Zimmerman J, Korreman S, Persson G, Cattell H, Svatos M, Sawant A, Venkat R, Carlson D, Keall P. DMLC motion tracking of moving targets for intensity modulated arc therapy treatment: a feasibility study. *Acta Oncol.* 2009;48(2):245-50. *Rigshospitalet, University of Copenhagen, Copenhagen, DE*

Linthout N, Bral S, Van de Vondel I, Verellen D, Tournel K, Gevaert T, Duchateau M, Reynders T, Storme G. Treatment delivery time optimization of respiratory gated radiation therapy by application of audio-visual feedback. *Radiother Oncol*. 2009 Jun;91(3):330-5.. *Universitair Ziekenhuis Brussel, BE*

Haasbeek CJ, Spoelstra FO, Lagerwaard FJ, van Sörnsen de Koste JR, Cuijpers JP, Slotman BJ, Senan S. Impact of Audio-Coaching on The Position of Lung Tumors. *Int J Radiat Oncol Biol Phys.* 2008 Jul 15;71(4):1118-23. *VU University Medical Center, Amsterdam, The Netherlands.*

van der Weide L, van Sörnsen de Koste JR, Lagerwaard FJ, Vincent A, van Triest B, Slotman BJ, Senan S. Analysis of carina position as surrogate marker for delivering phase-gated radiotherapy. *Int J Radiat Oncol Biol Phys.* 2008 Jul 15;71(4):1111-7. *VU University Medical Center, Amsterdam, The Netherlands.*

Zhao B, Yang Y, Li T, Li X, Heron DE, Huq MS. Image-guided respiratory-gated lung stereotactic body radiotherapy: which target definition is optimal? *Med Phys.* 2009 Jun;36(6):2248-57. *University of Pittsburgh, Pittsburgh, PA*

Sawant A, Venkat R, Srivastava V, Carlson D, Povzner S, Cattell H, Keall P. Management of threedimensional intrafraction motion through real-time DMLC tracking. *Med Phys.* 2008 May;35(5):2050-61. *Stanford University, Stanford, California*

Mao W, Wiersma RD, Xing L. Fast internal marker tracking algorithm for onboard MV and kV imaging systems. *Med Phys*. 2008 May;35(5):1942-9. *Stanford University Medical Center, Palo Alto*

Spoelstra FO, van Sörnsen de Koste JR, Cuijpers JP, Lagerwaard FJ, Slotman BJ, Senan S. Analysis of reproducibility of respiration-triggered gated radiotherapy for lung tumors. *Radiother Oncol*. 2008 Apr;87(1):59-64.; *VU University Medical Center, Amsterdam, The Netherlands.*

Haasbeek CJ, Spoelstra FO, Lagerwaard FJ, van Sörnsen de Koste JR, Cuijpers JP, Slotman BJ, Senan S. Impact of Audio-Coaching on The Position of Lung Tumors. *Int J Radiat Oncol Biol Phys.* 2008 Jul 15;71(4):1118-23. Feb 5; *VU University Medical Center, Amsterdam, The Netherlands*

Mao W, Wiersma RD, Xing L. Fast internal marker tracking algorithm for onboard MV and kV imaging systems. *Med Phys*. 2008 May;35(5):1942-9. *Stanford University Medical Center, Palo Alto*

Wiersma RD, Mao W, Xing L. Combined kV and MV imaging for real-time tracking of implanted fiducial markers. *Med Phys*. 2008 Apr;35(4):1191-8. *Stanford University Medical Center, Palo Alto*

Xu Q, Hamilton RJ, Schowengerdt RA, Jiang SB. A deformable lung tumor tracking method in fluoroscopic video using active shape models: a feasibility study. *Phys Med Biol.* 2007 Sep 7;52(17):5277-93. *University of Arizona, Tucson (also in Lung)*

Jin JY, Ajlouni M, Ryu S, Chen Q, Li S, Movsas B. A technique of quantitatively monitoring both respiratory and nonrespiratory motion in patients using external body markers. *Med Phys.* 2007 Jul;34(7):2875-81. *Henry Ford Hospital, Detroit*

Wagner TH, Meeks SL, Bova FJ, Friedman WA, Willoughby TR, Kupelian PA, Tome W. Optical tracking technology in stereotactic radiation therapy. *Med Dosim*. 2007 Summer;32(2):111-20. *University of Florida, Gainesville*

Litzenberg DW, Willoughby TR, Balter JM, Sandler HM, Wei J, Kupelian PA, Cunningham AA, Bock A, Aubin M, Roach M 3rd, Shinohara K, Pouliot J. Positional stability of electromagnetic transponders used for prostate localization and continuous, real-time tracking. *Int J Radiat Oncol Biol Phys.* 2007 Jul 15;68(4):1199-206. *University of Michigan, Ann Arbor (also in Prostate)*

Kupelian P, Willoughby T, Mahadevan A, Djemil T, Weinstein G, Jani S, Enke C, Solberg T, Flores N, Liu D, Beyer D, Levine L. Multi-institutional clinical experience with the calypso system in localization and continuous, real-time monitoring of the prostate gland during external radiotherapy. *Int J Radiat Oncol Biol Phys.* 2007 Mar 15;67(4):1088-98. *MD Anderson Cancer Center Orlando, Orlando (also in Prostate)*

Willoughby TR, Forbes AR, Buchholz D, Langen KM, Wagner TH, Zeidan OA, Kupelian PA, Meeks SL. Evaluation of an infrared camera and X-ray system using implanted fiducials in patients with lung tumors for gated radiation therapy. *Int J Radiat Oncol Biol Phys.* 2006 Oct 1;66(2):568-75 *M. D. Anderson Cancer Center Orlando, Orlando*

Kontrisova K, Stock M, Dieckmann K, Bogner J, Pötter R, Georg D. Dosimetric comparison of stereotactic body radiotherapy in different respiration conditions: a modeling study. *Radiother Oncol*. 2006 Oct;81(1):97- 104*. Medical University Vienna, Vienna, AT*

Stock M, Kontrisova K, Dieckmann K, Bogner J, Poetter R, Georg D. Development and application of a realtime monitoring and feedback system for deep inspiration breath hold based on external marker tracking. *Med Phys.* 2006 Aug;33(8):2868-77. *Medical University Vienna, Vienna, AT*

Huntzinger C, Munro P, Johnson S, Miettinen M, Zankowski C, Ahlstrom G, Glettig R, Filliberti R, Kaissl W, Kamber M, Amstutz M, Bouchet L, Klebanov D, Mostafavi H, Stark R. Dynamic targeting image-guided radiotherapy. *Med Dosim.* 2006 Summer;31(2):113-25. Review. *University of Florida, Gainesville & Varian,* Full

Linthout N, Verellen D, Tournel K, Storme G. Six dimensional analysis with daily stereoscopic x-ray imaging of intrafraction patient motion in head and neck treatments using five points fixation masks. *Med Phys*. 2006 Feb;33(2):504-13. *Academic Hospital-Free University, Brussels (also in H&N)*

Willoughby TR, Forbes AR, Buchholz D, Langen KM, Wagner TH, Zeidan OA, Kupelian PA, Meeks SL. Evaluation of an infrared camera and X-ray system using implanted fiducials in patients with lung tumors for gated radiation therapy. *Int J Radiat Oncol Biol Phys.* 2006 Oct 1;66(2):568-75. *MD Anderson Cancer Center Orlando, Orlando, FL*

Willoughby TR, Kupelian PA, Pouliot J, Shinohara K, Aubin M, Roach M 3rd, Skrumeda LL, Balter JM, Litzenberg DW, Hadley SW, Wei JT, Sandler HM. Target localization and real-time tracking using the Calypso 4D localization system in patients with localized prostate cancer. *Int J Radiat Oncol Biol Phys*. 2006 Jun 1;65(2):528-34. *MD Anderson Cancer Center Orlando, Orlando, FL*

Verellen D, Tournel K, Linthout N, Soete G, Wauters T, Storme G. Importing measured field fluences into the treatment planning system to validate a breathing synchronized DMLC-IMRT irradiation technique. *Radiother Oncol.* 2006 Mar;78(3):332-8. *Vrije Universiteit Brussel, Brussels, BE*

D'Souza WD, Kwok Y, Deyoung C, Zacharapoulos N, Pepelea M, Klahr P, Yu CX Gated CT imaging using a free-breathing respiration signal from flow-volume spirometry. *Med Phys*. 2005 Dec;32(12):3641-9. *University of Maryland School of Medicine, Baltimore, MD*

Underberg RW, Lagerwaard FJ, Slotman BJ, Cuijpers JP, Senan S. Use of maximum intensity projections (MIP) for target volume generation in 4DCT scans for lung cancer. *Int J Radiat Oncol Biol Phys*. 2005 Sep 1;63(1):253-60. *VU University Medical Center, Amsterdam, NL*

Underberg RW, Lagerwaard FJ, Slotman BJ, Cuijpers JP, Senan S. Benefit of respiration-gated stereotactic radiotherapy for stage I lung cancer: an analysis of 4DCT datasets. *Int J Radiat Oncol Biol Phys.* 2005 Jun 1;62(2):554-60. *VU University Medical Center, Amsterdam, NL*

de Koste JR, Lagerwaard FJ, de Boer HC, Nijssen-Visser MR, Senan S. Are multiple CT scans required for planning curative radiotherapy in lung tumors of the lower lobe? *Int J Radiat Oncol Biol Phys.* 2003 Apr 1;55(5):1394-9. *VU University Medical Center, Amsterdam, NL*

TECHNICAL

Dose-Radiation Delivery-Radiobiology

Ong C, Verbakel WF, Cuijpers JP, Slotman BJ, Senan S. Dosimetric Impact of Interplay Effect on RapidArc Lung Stereotactic Treatment Delivery. *Int J Radiat Oncol Biol Phys*. 2010 Jul 12.*VU University Medical Center, Amsterdam* [Epub ahead of print]

Zamora DA, Riegel AC, Sun X, Balter P, Starkschall G, Mawlawi O, Pan T. Thoracic target volume delineation using various maximum-intensity projection computed tomography image sets for radiotherapy treatment planning. *Med Phys*. 2010 Nov;37(11):5811-20. *The University of Texas MD Anderson Cancer Center, Houston, TX*

Fragoso M, Wen N, Kumar S, Liu D, Ryu S, Movsas B, Munther A, Chetty IJ. Dosimetric verification and clinical evaluation of a new commercially available Monte Carlo-based dose algorithm for application in stereotactic body radiation therapy (SBRT) treatment planning. *Phys Med Biol.* 2010 Aug 21;55(16):4445-64. *Henry Ford Health System, Detroit, MI*

Faygelman V, Hunt D, Walker L, Mueller R, Demarco ML, Dilling T, Stevens C, Zhang G. Validation of Pinnacle treatment planning system for use with Novalis delivery unit. *J Appl Clin Med Phys.* 2010 Jun 15;11(3):3240 *H. Lee Moffitt Cancer Center, Tampa, FL*

Truman JP, García-Barros M, Kaag M, Hambardzumyan D, Stancevic B, Chan M, Fuks Z, Kolesnick R, Haimovitz-Friedman A. Endothelial Membrane Remodeling Is Obligate for Anti-Angiogenic Radiosensitization during Tumor Radiosurgery. *PLoS One.* 2010 Aug 19;5(8). pii: e12310. *Memorial Sloan-Kettering Cancer Center, NY*

Dhabaan A, Elder E, Schreibmann E, Crocker I, Curran WJ, Oyesiku NM, Shu HK, Fox T. Dosimetric performance of the new high-definition multileaf collimator for intracranial stereotactic radiosurgery. *J Appl Clin Med Phys*. 2010 Jun 21;11(3):3040 *Emory University, Atlanta, GA*

Fragoso M, Wen N, Kumar S, Liu D, Ryu S, Movsas B, Munther A, Chetty IJ. Dosimetric verification and clinical evaluation of a new commercially available Monte Carlo-based dose algorithm for application in stereotactic body radiation therapy (SBRT) treatment planning. *Phys Med Biol.* 2010 Jul 29;55(16):4445-4464. *Henry Ford Health Systems, Detroit, MI*

Petoukhova AL, van Wingerden K, Wiggenraad RG, van de Vaart PJ, van Egmond J, Franken EM, van Santvoort JP. Verification measurements and clinical evaluation of the iPlan RT Monte Carlo dose algorithm for 6 MV photon energy. *Phys Med Biol.* 2010 Jul 29;55(16):4601-4614. *The Hague, The Netherlands.*

Mancosu P, Navarria P, Bignardi M, Cozzi L, Fogliata A, Lattuada P, Santoro A, Urso G, Vigorito S, Scorsetti M. Re-irradiation of metastatic spinal cord compression: a feasibility study by volumetric-modulated arc radiotherapy for in-field recurrence creating a dosimetric hole on the central canal. *Radiother Oncol.* 2010 Jan;94(1):67-70. *IRCCS Istituto Clinico Humanitas, Rozzano, Italy.*

Kirkpatrick JP, Brenner DJ, Orton CG. Point/Counterpoint. The linear-quadratic model is inappropriate to model high dose per fraction effects in radiosurgery. *Med Phys.* 2009 Aug;36(8):3381-4. *Duke University Medical Center, Durham, NC*

Tanyi JA, Summers PA, McCracken CL, Chen Y, Ku LC, Fuss M. Implications of a high-definition multileaf collimator (HD-MLC) on treatment planning techniques for stereotactic body radiation therapy (SBRT): a planning study. *Radiat Oncol.* 2009 Jul 10;4:22. *Oregon Health & Science University, Portland, OR*

Geneser SE, Kirby RM, Wang B, Salter B, Joshi S. Incorporating patient breathing variability into a stochastic model of dose deposition for stereotactic body radiation therapy. *Inf Process Med Imaging.* 2009;21:688- 700. *University of Utah, Salt Lake City, UT*

Korreman S, Medin J, Kjaer-Kristoffersen F. Dosimetric verification of RapidArc treatment delivery. *Acta Oncol.* 2009;48(2):185-91. *Copenhagen University Hospital, Copenhagen, DK*

Vanetti E, Nicolini G, Clivio A, Fogliata A, Cozzi L. The impact of treatment couch modelling on RapidArc. *Phys Med Biol.* 2009 May 7;54(9):N157-66. *Oncology Institute of Southern Switzerland, Bellinzona, SZ*

Bush K, Townson R, Zavgorodni S. Monte Carlo simulation of RapidArc radiotherapy delivery. *Phys Med Biol*. 2008 Oct 7;53(19):N359-70. *University of Victoria, Victoria, BC*

Babic S, McNiven A, Battista J, Jordan K. Three-dimensional dosimetry of small megavoltage radiation fields using radiochromic gels and optical CT scanning. *Phys Med Biol.* 2009 Apr 1;54(8):*2463-2481 University of Western Ontario, London, Ontario*

Ding M, Newman F, Chen C, Stuhr K, Gaspar LE. Dosimetric comparison between 3DCRT and IMRT using different multileaf collimators in the treatment of brain tumors. *Med Dosim.* 2009 Spring;34(1):1-8. *University of Colorado Health Science Center, Aurora, CO*

Salter BJ, Fuss M, Sarkar V, Wang B, Rassiah-Szegedi P, Papanikolaou N, Hollingshaus S, Shrieve DC. Optimization of isocenter location for intensity modulated stereotactic treatment of small intracranial targets. *Int J Radiat Oncol Biol Phys.* 2009 Feb 1;73(2):546-55. *University of Utah, Salt Lake City, UT*

Kirkpatrick JP, Meyer JJ, Marks LB. The linear-quadratic model is inappropriate to model high dose per fraction effects in radiosurgery. *Semin Radiat Oncol*. 2008 Oct;18(4):240-3. *Duke University Medical Center, Durham*

Wu QJ, Wang Z, Kirkpatrick JP, Chang Z, Meyer JJ, Lu M, Huntzinger C, Yin FF. Impact of collimator leaf width and treatment technique on stereotactic radiosurgery and radiotherapy plans for intra- and extracranial lesions. *Radiat Oncol.* 2009 Jan 21;4:3. *Duke University Medical Center, Durham*

Milano MT, Constine LS, Okunieff P. Normal tissue toxicity after small field hypofractionated stereotactic body radiation. *Radiat Oncol*. 2008 Oct 31;3:36. *University of Rochester Medical Center, Rochester, NY*

Kavanagh BD, Ding M, Schefter TE, Stuhr K, Newman FA. The dosimetric effect of inhomogeneity correction in dynamic conformal arc stereotactic body radiation therapy for lung tumors. *J Appl Clin Med Phys*. 2006 May 25;7(2):58-63. *University of Colorado, Aurora*

Chang Z, Wang Z, Wu QJ, Yan H, Bowsher J, Zhang J, Yin FF. Dosimetric characteristics of Novalis Tx system with high definition multileaf collimator. *Med Phys*. 2008 Oct;35(10):4460-3, *Duke University Medical Center, Durham*

Yang JN, Pino R. Analytical calculation of central-axis dosimetric data for a dedicated 6-MV radiosurgery linear accelerator. *Med Phys*. 2008 Oct;35(10):4333-41. *MD Anderson, Houston*

Hoffmann L. Implementation and experimental validation of the high dose rate stereotactic treatment mode at Varian accelerators. *Acta Oncol*. 2008 Aug 29; 1-8 *Aarhus University Hospital, Aarhus, DN*

Jensen RL, Wendland MM, Chern SS, Shrieve DC. Novalis intensity-modulated radiosurgery: methods for pretreatment planning. *Neurosurgery*. 2008 May;62(5 Suppl):A2-10, *University of Utah, Salt Lake City, UT*

Lawson JD, Elder E, Fox T, Davis L, Crocker I. Quantification of dosimetric impact of implementation of onboard imaging (OBI) for IMRT treatment of head-and-neck malignancies. *Med Dosim*. 2007 Winter; 32(4):287-94. *Emory University, Atlanta, GA*

Lee JW, Choi KS, Hong S, Kim YL, Chung JB, Lee DH, Choe BY, Jang HS, Suh TS. Effects of static dosimetric leaf gap on MLC-based small-beam dose distribution for intensity-modulated radiosurgery. *J Appl Clin Med Phys.* 2007 Oct 24;8(4):2397, *Konkuk University Hospital, Republic of Korea.*

Ding GX, Duggan DM, Coffey CW. Accurate patient dosimetry of kilovoltage cone-beam CT in radiation therapy. *Med Phys*. 2008 Mar;35(3):1135-44. *Vanderbilt University School of Medicine, Nashville*

Park C, Papiez L, Zhang S, Story M, Timmerman RD. Universal survival curve and single fraction equivalent dose: useful tools in understanding potency of ablative radiotherapy. *Int J Radiat Oncol Biol Phys.* 2008 Mar 1;70(3):847-52, *UT Southwestern Medical Center, Dallas*

van Sornsen de Koste JR, Cuijpers JP, de Geest FG, Lagerwaard FJ, Slotman BJ, Senan S. Verifying 4D gated radiotherapy using time-integrated electronic portal imaging: a phantom and clinical study. *Radiat Oncol.* 2007 Aug 30;2(1):32 *VU University Medical Center, Amsterdam*

Panettieri V, Wennberg B, Gagliardi G, Duch MA, Ginjaume M, Lax I. SBRT of lung tumours: Monte Carlo simulation with PENELOPE of dose distributions including respiratory motion and comparison with different treatment planning systems. *Phys Med Biol.* 2007 Jul 21;52(14):4265-81. *Universitat Politècnica de Catalunya, Barcelona*

Park DH, Shin D, Park SY, Park D, Kim TH, Shin KH, Yoon M, Kim DY, Cho KH. Optimized matching of film dosimetry with calculated doses for IMRT quality assurance. *Phys Med.* 2007 Jun;23(2):49-57. *National Cancer Center, Ilsan-gu, Goyang, KR*

Abrego FC, Calcina CS, de Almeida A, de Almeida CE, Baffa O. Relative output factor and beam profile measurements of small radiation fields with an L-alanine/K-band EPR minidosimeter. *Med Phys.* 2007 May;34(5):1573-82. *University of São Paulo, Brazil.*

Ding GX, Duggan DM, Coffey CW. Characteristics of kilovoltage x-ray beams used for cone-beam computed tomography in radiation therapy. *Phys Med Biol*. 2007 Mar 21;52(6):1595-615. *Vanderbilt University, Nashville*

Roberge D, Ruo R, Souhami L. Killing two birds with one stone: a dosimetric study of dual target radiosurgery using a single isocenter. *Technol Cancer Res Treat*. 2006 Dec;5(6):613-7. *McGill University, Montreal*

Lax I, Panettieri V, Wennberg B, Amor Duch M, Näslund I, Baumann P, Dose distributions in SBRT of lung tumors: Comparison between two different treatment planning algorithms and Monte-Carlo simulation including breathing motions. *Acta Oncol*. 2006;45(7):978-88. *Karolinska University Hospital and Institute, Stockholm, SW*

Kavanagh BD, Ding M, Schefter TE, Stuhr K, Newman FA.The dosimetric effect of inhomogeneity correction in dynamic conformal arc stereotactic body radiation therapy for lung tumors. *J Appl Clin Med Phys.* 2006 May 25;7(2):58-63. *Univ of Colorado, Denver*.

Lee CM, Watson GA, Leavitt DD. Dynamic collimator optimization compared with fixed collimator angle in arc-based stereotactic radiotherapy: a dosimetric analysis. *Neurosurg Focus.* 2005 Jul 15;19(1):E12. *University of Utah, Salt Lake City*

Belec J, Patrocinio H, Verhaegen F. Development of a Monte Carlo model for the Brainlab microMLC. *Phys Med Biol.* 2005 Mar 7;50(5):787-99. *McGill University, Montreal*

Hsi WC, Zhang Y, Kirk MC, Bernard D, Chu JC. Limited accuracy of dose calculation for large fields at deep depths using the BrainSCAN v5.21 treatment planning system. *J Appl Clin Med Phys.* 2005 Spring;6(2):12- 8. *Rush University Medical Center, Chicago*

Jin JY, Yin FF, Ryu S, Ajlouni M, Kim JH. Dosimetric study using different leaf-width MLCs for treatment planning of dynamic conformal arcs and intensity-modulated radiosurgery. *Med Phys*. 2005 Feb;32(2):405- 11. *Henry Ford Hospital, Detroit*

de Pooter JA, Essers M, Nowak PJ, de Pan C, Heijmen BJ, Levendag PC. Stereotactic arc therapy for small elongated tumors using cones and collimator jaws; dosimetric and planning aspects. *Med Phys*. 2004 Dec;31(12):3444-51. *Erasmus Medical Center-Daniel den Hoed, Rotterdam*

Hamm KD, Surber G, Schmucking M, Wurm RE, Aschenbach R, Kleinert G, Niesen A, Baum RP. Stereotactic radiation treatment planning and follow-up studies involving fused multimodality imaging. *J Neurosurg*. 2004 Nov;101 Suppl 3:326-33. *Charité-Universitätsmedizin, Berlin*

Surber G, Hamm K, Kleinert G. Significance of different conformity indices for evaluation of radiosurgery treatment plans for vestibular schwannomas. *J Neurosurg.* 2004 Nov;101 Suppl 3:334-40. *Helios Klinikum Erfurt, Germany (also in Vestibular Schwannomas)*

Agazaryan N, Ullrich W, Lee SP, Solberg TD. A methodology for verification of radiotherapy dose calculation. *J Neurosurg*. 2004 Nov;101 Suppl 3:356-61. *UCLA, Los Angeles*

Tobler M, Leavitt DD, Watson G. Optimization of the primary collimator settings for fractionated IMRT stereotactic radiotherapy. *Med Dosim*. 2004 Summer;29(2):72-9. *University of Utah Health Science Center, Department of Radiation Oncology, Salt Lake City, UT*

Monk JE, Perks JR, Doughty D, Plowman PN. Comparison of a micro-multileaf collimator with a 5-mm-leafwidth collimator for intracranial stereotactic radiotherapy. *Int J Radiat Oncol Biol Phys.* 2003 Dec 1;57(5):1443-9., *St. Bartholomew's Hospital, London*

Wagner TH, Bova FJ, Friedman WA, Buatti JM, Bouchet LG, Meeks SL. A simple and reliable index for scoring rival stereotactic radiosurgery plans. *Int J Radiat Oncol Biol Phys.* 2003 Nov 15;57(4):1141-9. *University of Florida, Gainesville*

Yu C, Shepard D. Treatment planning for stereotactic radiosurgery with photon beams. *Technol Cancer Res Treat.* 2003 Apr;2(2):93-104. *University of Maryland, Baltimore*

Dogan N, Glasgow GP. Surface and build-up region dosimetry for obliquely incident intensity modulated radiotherapy 6 MV x rays. *Med Phys.* 2003 Dec;30(12):3091-6. *Loyola University, Maywood*

Zygmanski P, Kung JH, Jiang SB, Chin L. Dependence of fluence errors in dynamic IMRT on leaf-positional errors varying with time and leaf number. *Med Phys.* 2003 Oct;30(10):2736-49. *Brigham and Women's Hospital and Harvard Medical School, Boston*

Linthout N, Verellen D, Van Acker S, De Cock M, Storme G. Dosimetric evaluation of partially overlapping intensity modulated beams using dynamic mini-multileaf collimation. *Med Phys*. 2003 May;30(5):846-55, *Academic Hospital-Free University, Brussels, BE*

Kavanagh BD, Timmerman RD, Benedict SH, Wu Q, Schefter TE, Stuhr K, McCourt S, Newman F, Cardinale RM, Gaspar LF. How should we describe the radioblologic effect of extracranial stereotactic radiosurgery: equivalent uniform dose or tumor control probability? *Med Phys.* 2003 Mar;30(3):321-4. *University of Colorado Health Sciences Center, Aurora*

Paskalev KA, Seuntjens JP, Patrocinio HJ, Podgorsak EB. Physical aspects of dynamic stereotactic radiosurgery with very small photon beams (1.5 and 3 mm in diameter). *Med Phys*. 2003 Feb;30(2):111-8. *Montreal General Hospital, Québec, CA*

Aaronson RF, DeMarco JJ, Chetty IJ, Solberg TD. A Monte Carlo based phase space model for quality assurance of intensity modulated radiotherapy incorporating leaf specific characteristics. *Med Phys.* 2002 Dec;29(12):2952-8. *University of California, Los Angeles*

Yin FF, Zhu J, Yan H, Gaun H, Hammoud R, Ryu S, Kim JH. Dosimetric characteristics of Novalis shaped beam surgery unit. *Med Phys.* 2002 Aug;29(8):1729-38. *Henry Ford Hospital, Detroit*

Linthout N, Verellen D, Van Acker S, Voordeckers M, Bretz A, Storme G. Evaluation of dose calculation algorithms for dynamic arc treatments of head and neck tumors. *Radiother Oncol*. 2002 Jul;64(1):85-95. *Academic Hospital, Free University Brussels, BE*

Fiveash JB, Murshed H, Duan J, Hyatt M, Caranto J, Bonner JA, Popple RA. Effect of multileaf collimator leaf width on physical dose distributions in the treatment of CNS and head and neck neoplasms with intensity modulated radiation therapy. *Med Phys.* 2002 Jun;29(6):1116-9. *University of Alabama-Birmingham, AL*

Wagner TH, Meeks SL, Bova FJ, Friedman WA, Buatti JM, Bouchet LG. Isotropic beam bouquets for shaped beam linear accelerator radiosurgery. *Phys Med Biol*. 2001 Oct;46(10):2571-86. *University of Florida, Gainesville, FL*

Benedict SH, Cardinale RM, Wu Q, Zwicker RD, Broaddus WC, Mohan R. Intensity-modulated stereotactic radiosurgery using dynamic micro-multileaf collimation. *Int J Radiat Oncol Biol Phys.* 2001 Jul 1;50(3):751-8. *Medical College of Virginia, Richmond, VA*

Leavitt DD, Watson G, Tobler M, Williams G, Gaffney DK, Shrieve DC. Intensity-modulated radiosurgery / radiotherapy using a micromultileaf collimator. *Med Dosim.* 2001 Summer;26(2):143-50. *University of Utah, Salt Lake City*

Solberg TD, Boedeker KL, Fogg R, Selch MT, DeSalles AA. Dynamic arc radiosurgery field shaping: a comparison with static field conformal and noncoplanar circular arcs. *Int J Radiat Oncol Biol Phys*. 2001 Apr 1;49(5):1481-91. *UCLA, Los Angeles*

Wagner TH, Yi T, Meeks SL, Bova FJ, Brechner BL, Chen Y, Buatti JM, Friedman WA, Foote KD, Bouchet LG.A geometrically based method for automated radiosurgery planning. *Int J Radiat Oncol Biol Phys.* 2000 Dec 1;48(5):1599-611. *University of Florida, Gainesville, FL*

Meeks SL, Bova FJ, Buatti JM, Friedman WA, Eyster B, Kendrick LA. Analytic characterization of linear accelerator radiosurgery dose distributions for fast optimization. *Phys Med Biol.* 1999 Nov;44(11):2777-87, *University of Florida, Gainesville, FL.*

Kubo HD, Wilder RB, Pappas CT. Impact of collimator leaf width on stereotactic radiosurgery and 3D conformal radiotherapy treatment plans. *Int J Radiat Oncol Biol Phys.* 1999 Jul 1;44(4):937-45. *University of California, Davis Medical Center, Sacramento*

Verellen D, Linthout N, Bel A, Soete G, van den Berge D, D' Haens J, Storme . Assessment of the uncertainties in dose delivery of a commercial system for linac-based stereotactic radiosurgery. *Int J Radiat Oncol Biol Phys.* 1999 May 1;44(2):421-33. *Academic Hospital, Free University Brussels, BE*

Meeks SL, Buatti JM, Bova FJ, Friedman WA, Mendenhall WM. Treatment planning optimization for linear accelerator radiosurgery. *Int J Radiat Oncol Biol Phys.* 1998 Apr 1;41(1):183-97. *University of Florida, Gainesville, FL*

Buatti JM, Friedman WA, Meeks SL, Bova FJ. The radiobiology of radiosurgery and stereotactic radiotherapy. *Med Dosim.* 1998 Fall;23(3):201-7. *University of Florida, Gainesville, FL*

Norrgard FS, Sipila PM, Kulmala JA, Minn HR. Dose characteristics of in-house-built collimators for stereotactic radiotherapy with a linear accelerator. *Phys Med Biol*. 1998 Jun;43(6):1545-56. *University of Turku, Finland*

Leavitt DD. Beam shaping for SRT/SRS. *Med Dosim*. 1998 Fall;23(3):229-36. *University of Utah School of Medicine, Salt Lake City.*

Fan CJ, Devanna WG, Leybovich LB, Kurup RG, Hopkins BJ, Melian E, Anderson D, Glasgow GP. Dosimetry of very-small (5-10 mm) and small (12.5-40 mm) diameter cones and dose verification for radiosurgery with 6-MV X-ray beams. *Stereotact Funct Neurosurg*. 1996-1997;67(3-4):183-97. *Loyola University, Maywood, IL*

TECHNICAL

PERFORMANCE-QA-QC

Peng LC, Kahler D, Samant S, Li J, Amdur R, Palta JR, Liu C. Quality assessment of frameless fractionated stereotactic radiotherapy using cone beam computed tomography. *Int J Radiat Oncol Biol Phys.* 2010 Dec 1;78(5):1586-93. *University of Florida College of Medicine, Gainesville, Florida*

Ling CC, Zhang P, Archambault Y, Bocanek J, Tang G, Losasso T. Commissioning and quality assurance of RapidArc radiotherapy delivery system. *Int J Radiat Oncol Biol Phys.* 2008 Oct 1;72(2):575-81. *Memorial Sloan-Kettering Cancer Center, New York*

Nicolini G, Vanetti E, Clivio A, Fogliata A, Korreman S, Bocanek J, Cozzi L. The GLAaS algorithm for portal dosimetry and quality assurance of RapidArc, an intensity modulated rotational therapy. *Radiat Oncol.* 2008 Sep 9;3:24. *Oncology Institute of Southern Switzerland, Bellinzona,Switzerland.*

Solberg TD, Medin PM, Mullins J, Li S. Quality assurance of immobilization and target localization systems for frameless stereotactic cranial and extracranial hypofractionated radiotherapy. *Int J Radiat Oncol Biol Phys.* 2008;71(1 Suppl):S131-5. *University of Nebraska Medical Center, Omaha*

Park DH, Shin D, Park SY, Park D, Kim TH, Shin KH, Yoon M, Kim DY, Cho KH. Optimized matching of film dosimetry with calculated doses for IMRT quality assurance. *Phys Med.* 2007 Jun;23(2):49-57. *National Cancer Center, Ilsan-gu, Goyang KR.*

Yoo S, Kim GY, Hammoud R, Elder E, Pawlicki T, Guan H, Fox T, Luxton G, Yin FF, Munro P. A quality assurance program for the on-board imagers. *Med Phys.* 2006 Nov;33(11):4431-47. *Duke University Medical Center, Durham*

Rosca F, Lorenz F, Hacker FL, Chin LM, Ramakrishna N, Zygmanski P. An MLC-based linac QA procedure for the characterization of radiation isocenter and room lasers' position. *Med Phys*. 2006 Jun;33(6):1780-7. *Brigham and Women's Hospital and Harvard Medical School, Boston*

Ding GX, Duggan DM, Coffey CW. Commissioning stereotactic radiosurgery beams using both experimental and theoretical methods. *Phys Med Biol*. 2006 May 21;51(10):2549-66. *Vanderbilt University, Nashville*

Lightstone AW, Benedict SH, Bova FJ, Solberg TD, Stern RL; American Association of Physicists in Medicine Radiation Therapy Committee. Intracranial stereotactic positioning systems: Report of the American Association of Physicists in Medicine Radiation Therapy Committee Task Group no. 68. *Med Phys.* 2005 Jul;32(7):2380-98. *MCVA, U of Florida, UCLA, Toronto-Sunnybrook*

Hua C, Chang J, Yenice K, Chan M, Amols H. A practical approach to prevent gantry-couch collision for linac-based radiosurgery. *Med Phys.* 2004 Jul;31(7):2128-34. *Memorial Sloan-Kettering Cancer Center, New York*

Li K, Yu CX, Ma L. Improving a scissor-action couch for conformal arc radiotherapy and radiosurgery. *J Appl Clin Med Phys.* 2004 Summer;5(3):62-5. *University of Maryland School of Medicine, Baltimore*

Ramaseshan R, Heydarian M. Comprehensive quality assurance for stereotactic radiosurgery treatments. *Phys Med Biol.* 2003 Jul 21;48(14):N199-205. *Princess Margaret Hospital, Toronto, CA*

Paskalev KA, Seuntjens JP, Patrocinio HJ, Podgorsak EB. Physical aspects of dynamic stereotactic radiosurgery with very small photon beams (1.5 and 3 mm in diameter). *Med Phys.* 2003 Feb;30(2):111-8. *McGill University Health Centre, Montreal*

Grebe G, Pfaender M, Roll M, Luedemann L, Wurm RE. Dynamic arc radiosurgery and radiotherapy: commissioning and verification of dose distributions. *Int J Radiat Oncol Biol Phys.* 2001 Apr 1;49(5):1451-60. Erratum in: *Int J Radiat Oncol Biol Phys* 2001 Nov 1;51(3):865. *Charité-Universitätsmedizin, Berlin, DE*

Cosgrove VP, Jahn U, Pfaender M, Bauer S, Budach V, Wurm RE. Commissioning of a micro multi-leaf collimator and planning system for stereotactic radiosurgery. *Radiother Oncol*. 1999 Mar;50(3):325-36. *Universitätsklinikum Charité, Berlin, DE*

Animal Models

Basic Research

Zeman RJ, Wen X, Ouyang N, Rocchio R, Shih L, Alfieri A, Moorthy C, Etlinger JD. Stereotactic radiosurgery improves locomotor recovery after spinal cord injury in rats. *Neurosurgery*. 2008 Nov;63(5):981-8. *New York Medical College, Valhalla, New York*

Ernst-Stecken A, Jeske I, Hess A, Rodel F, Ganslandt O, Grabenbauer G, Sauer R, Brune K, Blumcke I. Hypofractionated Stereotactic Radiotherapy to the Rat Hippocampus : Determination of Dose Response and Tolerance. *Strahlenther Onkol*. 2007 Aug;183(8):440-446, *University of Erlangen-Nuremberg, Erlangen, DE*

Brunner TB, Ernst-Stecken A, Jeske I, Grabenbauer GG, Sauer R, Distel L. Molecular verification of stereotactic radiotherapy in rats using ATMpS1981 immunofluorescence. *Radiother Oncol*. 2006 Apr;79(1):109-14, *University Hospitals of Erlangen, DE*

Jahan R, Solberg TD, Lee D, Medin P, Tateshima S, Sayre J, De Salles A, Vinters HV, Vinuela F. Stereotactic radiosurgery of the rete mirabile in swine: a longitudinal study of histopathological changes. *Neurosurgery*. 2006 Mar;58(3):551-8; discussion 551-8. *UCLA, Los Angeles*

Medin PM, Solberg TD, De Salles AA, Cagnon CH, Selch MT, Johnson JP, Smathers JB, Cosman ER. Investigations of a minimally invasive method for treatment of spinal malignancies with LINAC stereotactic radiation therapy: accuracy and animal studies. *Int J Radiat Oncol Biol Phys.* 2002 Mar 15;52(4):1111-22. , *UCLA, Los Angeles*

De Salles AA, Melega WP, Lacan G, Steele LJ, Solberg TD. Radiosurgery performed with the aid of a 3-mm collimator in the subthalamic nucleus and substantia nigra of the vervet monkey. *J Neurosurg*. 2001 Dec;95(6):990-7. *UCLA, Los Angeles*