

Health Technology Clinical Committee
Findings and Coverage Decision

Topic: Vertebroplasty, Kyphoplasty and Sacroplasty

Meeting Date: December 10th, 2010

Final Adoption:

Number and Coverage Topic

20101210A – Vertebroplasty, Kyphoplasty and Sacroplasty

HTCC Coverage Determination

Vertebroplasty, Kyphoplasty and Sacroplasty are **not a covered benefit**.

HTCC Reimbursement Determination

- ❖ **Limitations of Coverage**
 - N/A
- ❖ **Non-Covered Indicators**
 - Vertebroplasty, Kyphoplasty and Sacroplasty are not covered benefits
- ❖ **Agency Contact Information**

Agency	Contact Phone Number
Labor and Industries	1-800-547-8367
Public Employees Health Plan	1-800-762-6004
Health and Recovery Services Administration	1-800-562-3022

Health Technology Background

The Vertebroplasty, Kyphoplasty and Sacroplasty topic was selected and published in December 2009 to undergo an evidence review process. The evidence based technology assessment report indicates that vertebroplasty, kyphoplasty and sacroplasty are surgical procedures used to treat spinal pain believed to be caused by fractures in the vertebra or sacrum. There are all cementoplasty techniques that are thought to relieve pain by stabilizing the fractured bone(s), but the mechanism of pain relief is not clear. Vertebroplasty involves injection of bone cement into a partially collapsed vertebral body under computed tomography (CT) or fluoroscopic guidance. Kyphoplasty is a modification of vertebroplasty that expands the partially collapsed vertebral body with an inflatable balloon before the injection of bone cement. Sacroplasty is an extension of vertebroplasty, involving the injection of bone cement into the sacrum to repair sacral insufficiency fractures.

Fractures secondary to osteoporosis, vertebral metastasis and multiple myeloma are an important source of acute and chronic back pain as well as spinal deformity, reduced pulmonary function, decreased mobility and increased mortality. The majority of patients with osteoporotic fractures are older women. Patients with osteoporotic fracture are on average older than those with malignant fractures. Osteoporosis, vertebral metastasis and multiple myeloma are the most frequently reported indications for vertebroplasty and kyphoplasty. Sacroplasty is most frequently used to treat sacral insufficiency fractures (SIF), the majority of which are due to osteoporosis.

Patients with vertebral compression fracture (VCF) may or may not be symptomatic. Treatment of pain in VCF in the acute phase is not standardized. Chronic pain may be secondary to multiple fractures but the mechanism may be related more to muscle and ligament strain secondary to kyphosis. Such pain does not generally improve with analgesic use but may be addressed through exercise. While most patients are successfully treated with conservative therapy and pain relief occurs within a few weeks, persistent pain in a small percentage of patients leads to the consideration of operative treatment in this subset of patients. Vertebroplasty, kyphoplasty and sacroplasty are typically indicated for patients with painful insufficiency fracture due to osteoporosis or malignancy that is not responding to conservative treatment such as rest and analgesic use.

Vertebroplasty, kyphoplasty and sacroplasty are minimally invasive procedures which have purported benefits of relieving pain due to osteoporotic stress-related and tumor-related fractures and restoring function in patients whose bone maybe poor and/or who are poor candidates for more invasive surgical intervention. All involve the percutaneous injection of cement into the bone. These surgical procedures are less invasive than other spinal surgical procedures (e.g. fixation using screws), but more invasive than conservative medical therapy. Vertebroplasty, kyphoplasty and sacroplasty may relieve pain due to osteoporotic or malignant fracture by stabilizing the fracture and reducing pain from bone rubbing against bone.

In October 2010, the HTA posted a draft and then followed with a final report from a contracted research organization that reviewed publicly submitted information; searched, summarized, and evaluated trials, articles, and other evidence about the topic. The comprehensive, public and peer reviewed Vertebroplasty, Kyphoplasty and Sacroplasty report is 126 pages, and identified a relatively large amount of literature.

An independent group of eleven clinicians who practice medicine locally meet in public to decide whether state agencies should pay for the health technology based on whether the evidence report and other presented information shows it is safe, effective and has value. The committee met on December 10th, reviewed the report, including peer and public feedback, and heard public and agency comments. Meeting minutes detailing the discussion are available through the HTA program or online at <http://www.hta.hca.wa.gov> under the committee section.

Draft version not officially adopted yet: 12/10/2010

Committee Findings

Having considered the evidence based technology assessment report and the written and oral comments, the committee identified the following key factors and health outcomes, and evidence related to those health outcomes and key factors:

1. Evidence availability and technology features

The committee concludes that the best available evidence on Vertebroplasty, Kyphoplasty and Sacroplasty have been collected and summarized. The evidence is presented below:

- The evidence based technology assessment report indicates that vertebral compression fractures and sacral insufficiency fractures occur, commonly as part of the natural disease progression of osteoporosis or osteopenia. Some patients with fractures are asymptomatic but others experience acute pain, loss of function, and decreased quality of life thought to be caused by the fracture.
- Vertebroplasty (PV), kyphoplasty (KP) and sacroplasty are all cementoplasty techniques that aim to relieve pain thought to be caused by the fracture by stabilizing the fractured bone(s). Vertebroplasty and sacroplasty are considered minimally invasive procedures and are usually performed using only local anesthesia or with conscious sedation. General anesthesia may be used. Kyphoplasty almost always requires general anesthesia and at least one overnight stay in the hospital. The patient must lie prone during all three procedures. Multiple levels can be treated during the same session. Patients are usually selected based on failure of conservative treatment or incapacitating pain. Alternatives include conservative management and surgical fixation, though invasive surgery may be problematic due to common comorbidities in the elderly and female population most often considered for this treatment.
- Despite increasing use of these procedures (rates of kyphoplasty doubled between 2001 and 2005), the evidence for the procedure remains low and the efficacy, safety and economic impact are not well understood. Patients are generally elderly women with osteopenic fractures and most included studies focused on this population.
- The timing of intervention is an important consideration. Most patients are successfully treated with conservative care which resolves pain in 4 to 6 weeks and is generally recommended first. However, patients with acute fractures (less than six weeks) may be more likely to experience pain relief and the rapid recovery from debilitating pain is a primary treatment aim. Fracture age is difficult to determine as patients may have difficulty pinpointing the onset of pain and whether a certain event may be associated with the onset.
- In addition to typical complications from invasive procedures, cementoplasty techniques include risk of possible increase of subsequent compression fractures near a cemented vertebra due to increased rigidity of the treated vertebrae and risk of cement leakage.
- Evidence included in the technology assessment review was obtained through systematic searches of the medical literature for systematic reviews including meta-analyses, randomized controlled trials, observational studies, and economic studies. 11 RCTs, 23 Observational studies, and 3 economic studies met inclusion criteria and were included in the review. Overall strength of evidence from these studies was low to very low or inconclusive. Two RCTs compared vertebroplasty with sham procedure; three RCTs compared vertebroplasty to conservative care; one RCT compared kyphoplasty to conservative care; and one RCT compared kyphoplasty and vertebroplasty.
 - The evidence based technology assessment report identified 4 clinical guidelines; there is no National Coverage decision on vertebroplasty, kyphoplasty or sacroplasty.
 - The committee also reviewed information provided by the state agencies, and public members; and heard comments from the evidence reviewer, clinical expert, HTA program, agency medical directors and the public.

2. Is the technology safe?

The committee discussed multiple key factors and health outcomes that were important for consideration in their overall decision on whether the technology is safe. Summary of committee considerations follows.

- The evidence based technology assessment report concluded that the overall strength of evidence for safety is low for vertebroplasty and kyphoplasty and very low for sacroplasty and evidence based estimate of effect are uncertain. While it appears that rates of serious complications are low for vertebroplasty and kyphoplasty, studies with long-term (> 5 year) follow-up are few and comparative studies, especially RCTs, may have too few patients to detect more rare but serious outcomes. Primary safety outcomes reported include rates of new fracture, cement leakage, pulmonary cement embolism, and mortality related to vertebroplasty and kyphoplasty.
- *New fractures (adjacent or non-adjacent)* – in comparative studies, rates of new fractures were up to 30% at 12 months, with no consistent pattern across studies of increased fracture rates for any one treatment (vertebroplasty, kyphoplasty, or conservative treatment). One RCT reported that the distribution of fracture location (adjacent or non-adjacent) was similar for vertebroplasty and non-surgical patients. Systematic reviews, incorporating information on longer-term follow-up with a large (pooled) number of patients in case series, suggest that rates of new fracture may be slightly higher in vertebroplasty (18-19% of patients, 16-21% of vertebral levels) than kyphoplasty (7-17% of patients, 11-13% of levels). One systematic review concluded that the proportion of new fractures that were in adjacent vertebrae was higher for kyphoplasty (75%) than for vertebroplasty (52%).
- *Cement leakage* – in comparative studies, rates of cement leakage (largely asymptomatic) approached 80% for vertebroplasty and 50% for kyphoplasty, with some evidence that leakage is more common with vertebroplasty than with kyphoplasty. Systematic reviews also suggest that leakage is more common in vertebroplasty (19.7% - 79.0% of levels treated) than in kyphoplasty (0.51% - 11.2%), and that rates of symptomatic leakage are quite low (0.5%-1.6% of levels treated for vertebroplasty and 0% - 0.3% for kyphoplasty).
- *Pulmonary cement embolism* – as a result of differential surveillance in RCTs, non-randomized studies, and case series, rates vary widely across studies. One RCT using computed tomography to detect emboli reported that 26% (15/54) of vertebroplasty patients had a cement embolism, all of which were asymptomatic. No incidents of symptomatic embolism were reported in comparative studies. A systematic review of cement embolism reported rates of 1.6% for asymptomatic PCE and 1.1% for symptomatic PCE (all but one of the case series included in the review were of vertebroplasty patients).
- *Mortality* – systematic reviews (based on case series) estimate mortality rates at 2.1% for vertebroplasty and 2.3%-3.2% for kyphoplasty; the timing of mortality was not reported. Peri-operative mortality rate for kyphoplasty was .01% across 11 case series. Since the majority of patients receiving these procedures are elderly and/or have malignant disease, the extent to which mortality can be attributed to the procedures is unclear.
- *Sacroplasty* – the evidence based technology assessment report indicates that the overall strength of evidence about safety of sacroplasty is very low, and all data are from case series. Cement leakage was the only reported complication and occurred in 7 of 34 (20.6%) patients across four case series.

3. Is the technology effective?

The committee discussed multiple key factors and health outcomes that were important for consideration in their overall decision on whether the technology is effective. Summary of committee considerations follows.

- Vertebroplasty:

- *Pain Relief* – the evidence based technology assessment report concluded that the overall strength of evidence about effectiveness of vertebroplasty to reduce/relieve pain is *low*; any effect estimate is uncertain and may change with additional research. The low strength of evidence and lack of ability to estimate effect based on evidence is due to the limitations of the studies and that the studies reported differing outcomes (some studies showed benefit others did not). The RCTs were limited to patients with osteoporotic fractures and evaluated short-term effects (≤ 12 months). Two sham-controlled RCTs demonstrated no difference in pain relief (up to 1 month in one study and 6 months in the other), though both studies were limited in power to detect differences in the proportion of patients with clinically meaningful improvement. Another RCT demonstrated statistically significant improvement in pain scores sustained to the 12-month follow-up compared to conservative care and included more patients but was not blinded and did not include a placebo comparison. Two small RCTs reported no advantage for vertebroplasty over 2 weeks or 12 months. Four nonrandomized studies with follow-up up to one year found that vertebroplasty was more effective in reducing pain than conservative medical treatment at up to approximately six months, but no difference at one year.
- *Function and quality of life* – the evidence based technology assessment report concluded that the overall strength of evidence about effectiveness of vertebroplasty to improve patient function or quality of life is *low*; any effect estimate is uncertain and may change with additional research. One larger RCT demonstrated that PV was more effective than conservative treatment in improving functioning as measured by the QualEffo and RDQ, although it is possible that early differences in improvement diminish over time. Two small RCTs found comparable improvements in function over 2 weeks and 12 months for vertebroplasty and non-surgical patients. In 4 non-randomized studies, vertebroplasty showed superior effectiveness in improvements in functioning and quality of life in the first 3-6 months was followed by equivalence at one year.
- **Kyphoplasty:**
 - *Pain Relief* – the evidence based technology assessment report concluded that the overall strength of evidence about effectiveness of kyphoplasty to relieve/reduce pain is very *low*; any effect estimate is uncertain and may change with additional research.
 - Only one RCT compared kyphoplasty with conservative treatment, reporting that while pain was reduced more rapidly in kyphoplasty patients, this advantage over conservative treatment was diminished by the one-year follow-up. Because of the paucity of RCTs comparing kyphoplasty to conservative treatment, the overall strength of evidence is low and effect estimates may change with additional research. In two non-randomized studies, kyphoplasty reduced pain more than conservative medical treatment for periods up to 3 years.
 - *Function and quality of life* – the evidence based technology assessment report indicated that it is uncertain whether kyphoplasty improves patient functioning and quality of life. In these two studies, kyphoplasty improved a limited set of functional outcomes more than conservative medical treatment.
- **Sacroplasty:** There is no evidence of efficacy for sacroplasty. Very limited data from 9 case series (N = 141 total patients) is available, the case series showed pain relief with sacroplasty; but the absence of comparative studies, small patient size do not permit an evidence based conclusion.

4. **Special Populations?**

- The evidence based technology report concluded that there is insufficient evidence for any conclusion of differential effect.

- Fracture age was one key potential differentiator; however no studies were designed to directly compare efficacy or safety outcomes between patients with acute, sub-acute, and/or chronic fractures. Two RCTs reported that improvements in pain and functional outcomes were not significantly different for patients with acute and chronic fractures; however, the studies may not have had adequate power for these post-hoc analyses. One RCT of PV vs. CMT in patients with acute fractures reported greater improvement in pain and function for PV patients, but evidence for differential efficacy cannot be derived since there was no direct comparison with more chronic fractures in the same underlying population
- The evidence based technology assessment report indicates that no studies were found that addressed differential efficacy or safety issues for subpopulations defined by gender, age, psychological or psychosocial co-morbidities, provider characteristics, or payer type.
- Diagnosis (osteoporosis or tumor-related fractures) – the evidence based technology assessment report indicates that there are no studies that assessed differential outcomes of vertebroplasty or kyphoplasty by fracture etiology. The majority of studies were limited to patients with osteoporotic fractures. Only two retrospective cohort studies (both comparing vertebroplasty with kyphoplasty) studied patients with fractures due to malignancy, with one study reporting comparable outcomes both procedures and the other reporting that kyphoplasty led to more improvement in pain than vertebroplasty over one year.

5. Is the technology cost-effective?

The committee discussed multiple key factors that were important for consideration in their overall decision on whether the technology has value and is cost-effective. Summary of committee considerations follows.

- The evidence based technology report summarized three economic studies, however, because the evidence about efficacy, effectiveness, and safety is low to very low and evidence based estimates of effect are uncertain; conclusions about cost effectiveness are premature. No cost studies were conducted with U.S. data, the cost effectiveness of vertebroplasty, kyphoplasty or sacroplasty in a US setting is unknown.
- The economic impact of complications, reoperation, or revision following vertebroplasty, kyphoplasty, or sacroplasty is unknown.
- Washington state agency utilization and cost information indicates that the single agency that reimburses (UMP) for these procedures expended \$868,543 in the last four years, with an average cost of \$10,837; and both procedure volume and costs are rising annually.

6. Medicare Decision and Expert Treatment Guidelines

Committee reviewed and discussed the expert guidelines as identified and reported in the technology assessment report. Overall, the clinical guidelines and Medicare coverage decisions included in the evidence report and the AAOS guideline published subsequent either do not cite evidence or rely on evidence assess as low or very low quality or consensus statements.

- Centers for Medicare and Medicaid Services (CMS) have no published National or Local coverage determinations for vertebroplasty, kyphoplasty or sacroplasty.
- The evidence based technology assessment report identified three guidelines on vertebroplasty, kyphoplasty and/or sacroplasty, although no guideline specifically addressed the procedures for osteoporosis or malignancy – the studied indications.
 - Two guidelines mentioned vertebroplasty and kyphoplasty as part of the assessment and management of spinal cord compression and chronic pain and indicate they may be considered.
 - Institute for Clinical Systems Improvement (ICSI), 2008

- National Collaborating Centre for Cancer, National Institute for Health and Clinical Excellence (NICE), 2008
- *American Society of Interventional and Therapeutic Neuroradiology, Society of Interventional Radiology, American Association of Neurological Surgeons / Congress of Neurological Surgeons, and American Society of Spine Radiology* -- A consensus statement on percutaneous vertebral augmentation was developed: “It is the position of the Societies that vertebral augmentation with vertebroplasty or kyphoplasty is a medically appropriate therapy for the treatment of painful vertebral compression fractures refractory to medical therapy when performed for the medical indications outlined in the published standards¹⁻³.”
- *American Association of Orthopaedic Surgeons (AAOS)* -- recommend against vertebroplasty for patients who present with an osteoporotic spinal compression fracture on imaging with correlating clinical signs and symptoms and who are neurologically intact. *Strength of Recommendation: Strong.* Kyphoplasty is an option for patients who present with an osteoporotic spinal compression fracture on imaging with correlating clinical signs and symptoms and who are neurologically intact. *Strength of Recommendation: Weak.*

Committee Decision

Based on the deliberations of key health outcomes, the committee decided that it had the most complete information: a comprehensive and current evidence report, public comments, and agency and state utilization information. The committee concluded that the current evidence indicated there is insufficient evidence to cover Vertebroplasty, Kyphoplasty and Sacroplasty; therefore, the committee unanimously agreed to not cover. The committee considered all the evidence and gave greatest weight to the evidence it determined, based on objective factors, to be the most valid and reliable.

Based on these findings, the committee voted 10 to 0 to not cover Vertebroplasty. Based on these findings, the committee voted 10 to 0 to not cover Kyphoplasty. Based on these findings, the committee voted 10 to 0 to not cover Sacroplasty.

Health Technology Clinical Committee Authority

Washington State’s legislature believes it is important to use a scientific based, clinician centered approach for difficult and important health care benefit decisions. Pursuant to chapter 70.14 RCW, the legislature has directed the Washington State Health Care Authority, through its Health Technology Assessment program to engage in a process for evaluation process that gathers and assesses the quality of the latest medical evidence using a scientific research company and takes public input at all stages. Pursuant to RCW 70.14.110 a Health Technology Clinical Committee (HTCC) composed of eleven independent health care professionals reviews all the information and renders a decision at an open public meeting. The Washington State Health Technology Clinical Committee (HTCC) determines how selected health technologies are covered by several state agencies (RCW 70.14.080-140). These technologies may include medical or surgical devices and procedures, medical equipment, and diagnostic tests. HTCC bases their decisions on evidence of the technology’s safety, efficacy, and cost effectiveness. Participating state agencies are required to comply with the decisions of the HTCC. HTCC decisions may be re-reviewed at the determination of the HCA Administrator.

Vertebroplasty, Kyphoplasty and Sacroplasty (VKS)

Draft Findings & Decision Timeline and Overview of Comments

The Health Technology Assessment (HTA) program received comments in response to the posted Health Technology Clinical Committee (HTCC) draft findings and decision on Vertebroplasty, Kyphoplasty and Sacroplasty (VKS).

Commenter	Comment Period Feb. 4–Feb. 18	Cited Evidence
Patient, relative, and citizen	1	0
Legislator and public official	0	0
Physician and health care professional	1	0
Industry and Manufacturer	1	1
Professional Society and Advocacy Organization	2	2

All Total = 5

Comments with Evidence:

Industry and Manufacturer Comments

Michelle Quinn, Senior Manager, Payer Strategies, Medtronic Spinal & Biologics

- Disagrees with decision on kyphoplasty, and combining decisions on procedures. Other key clinical evidence for balloon kyphoplasty is expected to be published soon.

Professional Society and Advocacy Organization Comments

Ziya Gokaslan, MD, Chair, American Association of Neurological Surgeons / Congress of Neurological Surgeons (AANS/CNS) Joint Selection on Disorders of the Spine and Peripheral Nerves

- Concerned regarding the coverage determination made since a patient with pathological spinal fracture and kyphosis from multiple myeloma would be deprived the less invasive option of kyphoplasty and radiation, and would possibly undergo a larger surgical procedure or accept unneeded disability. AANS/CNS believes that vertebral augmentation procedures are appropriate and beneficial in appropriately selected patients and decision is overbroad.

Gregory Przybylski, MD, President, North American Spine Society (NASS)

- NASS disagrees with decision, and believes it would be better to enforce appropriateness criteria to coverage of this procedure. Furthermore, NASS feels that vertebroplasty for the treatment of pathological fractures should be covered as a medically necessary procedure.

Comments without Evidence:

Physician and Health Care Professional Comments

Theodore Wagner, MD, Professor of Orthopedic Surgery, University of Washington

- Disagrees with the coverage determination. Strongly supports the use of kyphoplasty.

Patient, relative, and citizen Comments

Dennis Eibe, Patient

- Strongly endorses all the procedures reviewed as patient who has undergone a balloon kyphoplasty and vertebroplasty.

	Actual Timeline	Total Public Comment Days
Preliminary recommendations published	<i>October 27, 2009</i>	
Public comments due:	<i>November 10, 2009</i>	15 days
Selected set of topics published:	<i>December 8, 2009</i>	
Public comments due:	<i>January 11, 2010</i>	35 days
Draft Key Questions Published:	<i>March 15, 2010</i>	
Public comments due:	<i>March 29, 2010</i>	15 days
Key Questions Finalized:	<i>April 14, 2010</i>	
Draft report due:	<i>October 4, 2010</i>	
Draft report published:	<i>October 7, 2010</i>	
Public Comments due:	<i>October 22, 2010</i>	16 days
Final report due:	<i>November 3, 2010</i>	
Final report published:	<i>November 5, 2010</i>	
Public meeting Date:	<i>December 10, 2010</i>	
Findings & Decision Published	<i>February 4, 2011</i>	
Public Comments due:	<i>February 18, 2011</i>	15 days

March 18, 2011

Dear WA State Health Technology Clinical Committee,

Medtronic Kyphon would like to formally respond to the Health Technology Clinical Committee's decision to deny coverage for kyphoplasty as noted in its draft findings decision document dated 2/4/11.

While Medtronic recognizes the importance of utilizing randomized controlled trials (RCTs) in the State of Washington Health Care Authority's health technology assessment process, we are disappointed with the decision by group to not consider the **full body** of evidence pertaining specifically to kyphoplasty which we made available in our original comments. This will have an effect on patient care. As we previously showed, conservative care treatments are not effective in the majority of this patient population and therefore by not allowing balloon kypoplasty, patients will now be forced to endure unnecessarily. Additionally, Medtronic Kyphon is in disagreement with the committee's "combining" vertebroplasty and balloon kyphoplasty evidence into one recommendation. The two procedures are different from one another, with different clinical evidence and should have been taken into consideration separately.

The exclusion of the large body of peer-reviewed clinical evidence including prospective comparative trials, registry, extensive case series, and patient outcomes research which collectively report on consistently positive clinical outcomes following treatment of vertebral compression fractures (VCFs) with kyphoplasty is not in the patients' interest. **These data provide objective measures of the rapid, significant, and sustained relief of pain, increase in mobility, and improvement in quality of life** that is extensively reported in the literature and broadly experienced by both patients and their physicians worldwide.

We would like to reiterate that currently there is an extensive body of clinical evidence exists which describes clinical outcomes of patients with VCFS who were treated with kyphoplasty. As of April, 2010, this evidence consisted of 97 peer-reviewed publications and included randomized controlled trials, prospective comparative trials, a national registry, and large case series. Without exception, each of these studies reported positive clinical outcomes (improvements in pain, disability, mobility, and quality of life) for the patients treated with kyphoplasty. In addition to this demonstrated effectiveness in treating VCFs, kyphoplasty has established an excellent record of safety.

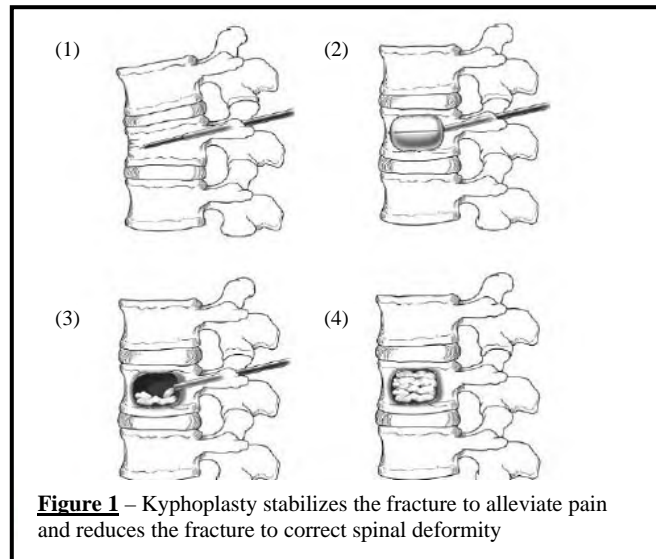
Based on the outline within the draft findings document we would like to summarize again key clinical findings that should be considered.

1. Evidence availability and technology features.

- 1.1. In addition to the acute pain, loss of function, and decreased quality of life that the Washington State Health Care Authority has listed as the consequences of vertebral compression fractures (VCFs) experienced by stricken patients, it should also be noted that a higher mortality rate has also been reported in individuals with VCFs. Lau et al. reported that patients who were diagnosed with VCFs were found to have an 7-year survival rate that was 40% below that of controls matched for age, gender, and comorbidities ($p < 0.001$).¹
- 1.2. In its coverage denial, the Washington State Health Care Authority refers to vertebroplasty, kyphoplasty, and sacroplasty as all being "cementoplasty" procedures and fails to recognize the differences between vertebroplasty and kyphoplasty that are inherent in the two procedures. Key characteristics of the kyphoplasty procedure and their importance in the treatment of vertebral compression fractures (VCFs) are discussed below and illustrated in Figure 1:
 - (1) The bipedicular introduction of cannulae through two 1-cm incisions into the fractured vertebral body under image guidance.

(2) The insertion of an inflatable bone tamp to elevate the vertebral body endplates and reduce spinal deformity. The inflation of the bone tamp compacts the cancellous bone, fills fracture lines and creates a void within the vertebral body.

(3-4) The controlled filling of the void with high viscosity bone cement under low pressure to distribute the cement across the vertebral body for reliable fracture stabilization. The advantages of void creation are a defined location with a known volume for cement placement along with the reduced potential for the fixation material to extend beyond the region of its intended application.²



The role of the void in kyphoplasty is critical to bone cement control and distribution. The lack of a void during vertebroplasty means that the practitioner must force bone cement into crushed bone. This is why vertebroplasty requires relatively liquid bone cement and higher injection pressures compared with kyphoplasty. Balloon inflation during kyphoplasty packs bone into fracture lines and disrupts the internal venous plexus, reducing leak pathways, as demonstrated by Phillips *et al.*³ This creates an environment in which leaks are less likely to occur through fractures in the vertebral cortex or injection into the vertebral venous system. In order to minimize the risk of cement extravasation, vertebroplasty practitioners attempt to stop further cement injection once it is evident that cement has passed outside the vertebra. Nevertheless, cement leakage can still occur due to the surgeon's reaction time between visualization of the cement leak and cessation of the injection. Premature cessation of cement injection can also lead to inadequate cement filling of the fractured vertebra.⁴

1.2.1. The differences between kyphoplasty and vertebroplasty in the clinical literature have been recognized by the Technology Assessment Committee of the Society for Interventional Radiology:⁵

“The most significant differences between the two procedures is the restoration of vertebral body height, thus reducing kyphosis at the treated level; and the associated long-term complications. Another potential benefit to kyphoplasty is the lower reported rate of cement extrusion. It has been shown that kyphoplasty may seal osseous defects and venous pathways, thereby preventing cement from leaking.”

1.2.2. The increased rate of cement leaks documented with the vertebroplasty technique compared to kyphoplasty predicts a higher rate of cement-related complications as well. This includes nerve root injury from foraminal leaks, cord/cauda equina compression from epidural leaks, as well as pulmonary emboli from venous leaks. While only large RCTs directly comparing the two procedures can definitely demonstrate safety differences, systematic literature reviews analyzing cement leaks and adverse events support this hypothesis.

- In the most recent meta-analysis comparing the incidence of complications in VCF patients treated with kyphoplasty (n=2,794 levels treated) vs. vertebroplasty (n=7,184 levels treated), Lee and colleagues found that vertebroplasty had a significantly higher rate of both total cement leaks (43% vs. 8.8%, p<0.001) and symptomatic cement leaks (1.08% vs. 0.04%, p<0.001) than kyphoplasty.⁶

- This result is consistent with previous formal analyses, documenting a higher pooled risk of pulmonary and neurologic complications during vertebroplasty than kyphoplasty.^{7,8}

1.2.3. Lad et al.⁹ evaluated the 2004 National Inpatient Sample (NIS) database to assess differences in the utilization and outcomes of vertebroplasty and kyphoplasty. The investigators reported that of the 23, 691 hospital inpatients with VCFs who were treated with either kyphoplasty or vertebroplasty, that those patients treated with kyphoplasty were more likely to have a shorter length of stay and were more likely to be discharged to their home (vs. an institution) than patients treated with vertebroplasty, while average hospital charges were similar. See data in Table 1 below.

Table 1		
	Kyphoplasty	Vertebroplasty
% discharged to home	77%	50%
% discharged to institution	23%	50%
Length of Hospital Stay	3.7 days	7.3 days
Mean Hospital Charges	\$30,144	\$29,517

1.3. In its coverage denial of kyphoplasty, the Washington State Health Care Authority states that “*Kyphoplasty almost always requires general anesthesia and at least one overnight stay in the hospital*”.

Kyphoplasty is performed under local or general anesthesia and on either an inpatient or an outpatient basis¹⁰ depending on the medical need of the patient as determined by the treating physician.^{11, 12}

1.3.1. Chung et al.¹³ and Theodorou et al.¹⁴ have reported on their VCF patient outcomes following treatment with kyphoplasty in which only local anesthesia was utilized while Wardlaw et al.¹⁵ report results using general anesthesia for most patients.

1.3.2. Based on CMS MEDPAR data for calendar year 2009, approximately one-half of all kyphoplasty procedures are done on an inpatient basis, one-half are performed on an outpatient basis.¹⁶

1.4. In its coverage denial of kyphoplasty, the Washington State Health Care Authority asserts that “*Most patients are successfully treated with conservative care which resolves pain in 4 to 6 weeks*”. No clinical evidence is cited for this assertion.

1.4.1. To the contrary, the American Academy of Orthopaedic Surgeons, after reviewing the medical literature determined that

“There are no existing adequate data to address the use of the following potential conservative, nonoperative therapies for a spinal compression fracture in patients who are neurologically intact: bed rest or complementary, alternative medicines and opioids/analgesics [p.49].”¹⁷

1.4.2. Further, the lack of significant benefit of conservative care was reported by Suzuki et al.¹⁸ who followed patients admitted to the hospital for osteoporotic VCFs and treated with conservative care for 12 months. Using a pain intensity score from 0 (no) to 100 (worst ever) pain, the mean pain score of these patients went from 71 at baseline to only 61 after 12 months. After 1 year, only 10% reported no or very little pain while almost 76% had pain intensity regarded as severe.

1.4.3. Consistent with the Suzuki’s finding, the continuing care needs of patients with a primary diagnosis of VCF following hospital discharge after receiving non-operative care was reported by Gehlbach and colleagues in their analysis of 68,901 VCF patients based on data from the 1997 National Inpatient Sample. The authors reported that after an average hospital stay of 5.7 days and average charges of \$8,500 per patient, that 50% of VCF patients still

required care in a nursing home or an intermediate care facility and another 12% required home health care.

- 1.4.4. Additionally, in a prospective, multicenter, randomized controlled trial comparing conservative nonoperative management to kyphoplasty, Wardlaw et al.¹⁹ reported that osteoporotic patients with VCFs who were treated with kyphoplasty experienced significantly less pain over the 12 months of follow-up. Significantly fewer of these patients required narcotic analgesics during the first 6 months following treatment or any analgesics during the 12 months following treatment than patients treated conservatively. Patients treated with kyphoplasty experienced 60 fewer days of restricted activity (1/2 the day or more in bed due to back pain) and, on average, experienced a significantly greater quality of life than patients treated conservatively.
- 1.5. In its coverage denial of kyphoplasty, the Washington State Health Care Authority states that “cementoplasty techniques include risk of possible increase in subsequent compression fractures near a cemented vertebra due to increased rigidity of the treated vertebrae and risk of cement leakage. This statement fails to recognize the findings of Lindsay et al.²⁰ who found that the rate of incident VCFs doubles with every 2 prevalent fractures in osteoporotic women. No clinical trials have been reported which control for prevalent fractures when reporting the number of subsequent fractures following kyphoplasty. Based on Lindsay’s findings, it is not appropriate to compare subsequent fracture rates between populations without controlling for VCF prevalence.

2. Is the technology safe?

2.1. In its coverage denial of kyphoplasty, the Washington State Health Care Authority states that “the overall strength of evidence for safety is low for vertebroplasty and kyphoplasty”. It should be noted that kyphoplasty is found to have a low adverse event rate in published meta-analyses, the large body of peer-reviewed medical literature that have reported patient outcomes following its use, in multicenter prospective randomized controlled trials and in the results of a search of the MAUDE database.

2.1.1. Kyphoplasty demonstrates a low rate of cement extravasations and complications in published meta-analyses. The data from several recent meta-analyses support the safety of kyphoplasty and are summarized in Table 2 below – for purposes of reference, those data reported for vertebroplasty in these studies are also provided.

Table 2		
Cement Leaks and Complications	Kyphoplasty	Vertebroplasty
Extravertebral Cement Extravasations (Most with no clinical consequences)	7 – 9% ^{21,22,23,24,}	20 – 41% ^{22,23,24}
Serious and Symptomatic Complications	2% ^{,25}	3.9% ²²
Symptomatic Cement Leakage	0% – 0.3% ^{21,24}	1.6% – 3% ²¹

2.1.2. Kyphoplasty is found to have a low rate of complications in the large body of peer-reviewed clinical evidence.

The results of the meta-analyses are in agreement with that of an internal Medtronic safety analysis in which 97 unique kyphoplasty cohort (n ≥10 pts.) studies were identified using the U.S. National Library of Medicine’s MEDLINE® database as of April 5, 2010. The following data were obtained based on 6,426 subjects who underwent kyphoplasty:

- Total procedure-related severe adverse event rate = 1.18% (76 out of 6,426 patients)
- Rate of cement related symptomatic adverse events = 0.22% (14 out of 6,426 patients)
- Post-operative medical complications - not thought to be procedure related = 0.67% (43 of 6,426 cases)

2.1.3. Kyphoplasty is found to have a low rate of complications in the Fracture Reduction Evaluation (FREE) randomized controlled trial. In FREE, 300 patients at 21 sites with VCFs due to osteoporosis were randomized to either kyphoplasty or nonsurgical management. In the kyphoplasty treatment group, there were 3/149 patients (2.0%) who had 4 device or procedure-related serious adverse events: a patient with a hematoma; a patient with a post-operative urinary tract infection and spondylitis; and a patient with an anterior cement migration after 1 year of index treatment.¹⁵

2.1.4. The results stemming from a search of FDA’s MAUDE database for kyphoplasty adverse events is also consistent with the safety results in the FREE trial. There were 309 (4.4 per 10,000 cases) unique events reported to the FDA; the majority of events were cardiopulmonary or neurologic in nature. No unanticipated serious device or procedure related adverse events were reported which are not already mentioned in the instructions for use. Given that approximately 700,000 fractures have been treated with kyphoplasty to date, this rate is also low.

In all cases, the published medical literature and data submitted to FDA’s MAUDE database support the safe use of kyphoplasty and PMMA-based bone cements for the indications for use. The review of the combined data supports an acceptable safety profile for kyphoplasty.

3. Is the technology effective?

3.1. In its coverage denial of kyphoplasty, the Washington State Health Care states that the “*evidence based technology assessment concluded that the overall strength of evidence about effectiveness of kyphoplasty to relieve pain is very low*” and that “*it is uncertain whether kyphoplasty improves patient functioning and quality of life*”

It should be noted that this assessment did not consider the findings of a comprehensive review of the clinical literature based on a search of the U.S. National Library of Medicine database conducted on April 5, 2010 and previously provided to the State of Washington Health Care Authority. That literature review found a total of 97 publications (containing cohorts of 10 or more patients) in which 12,194 patients were enrolled. The search criteria employed, a summary of each paper, and a bibliography providing full citations for each publication is provided in Appendix 1. The published studies are noteworthy in that they uniformly show consistently positive results for VCF patients treated with kyphoplasty concerning pain, patient functioning, and quality of life along with other endpoints – see Table 3 below.

Table 3		
Summary of Journal Publications on the Use of Kyphoplasty in the Treatment of Vertebral Compression Fractures		
Endpoint	# of Studies Reporting on this Endpoint	# of Studies with Positive Kyphoplasty Results
Pain (NRS, VAS, others)	82	82
Ambulation, Activities of Daily Living	37	37
Disability (ODI, RMDQ)	30	30
Quality of Life Health Survey	13	13
Vertebral Height Restoration	58	60
Angular Deformity Correction	58	58
Based on a U.S. National Library of Medicine Literature Search as of April 05, 2010. See Appendix 1.		

4. **Special Populations?** No comments are offered

5. Is the technology cost effective?

The cost-effectiveness of kyphoplasty was demonstrated by Strom and colleagues²⁶ who developed a Markov model to compare the cost-effectiveness of kyphoplasty to non-surgical management. The authors used the data from the FREE randomized controlled trial to derive the quality adjusted life years (QALYS) gained in each cohort and the cost data was obtained from three national health service hospitals in the United Kingdom. The analysis found that the incremental cost per QALY gained in the kyphoplasty group was £8,800 (\$14,200) – the authors deemed this to be cost effective given UK norms that accept a cost/QALY within the range of £20,000 – 30,000 to be acceptable. The Strom model included estimates of the probability and cost of subsequent fractures but did not include cost associated with patient care after hospital discharge. This difference may well be substantial based on the findings of Zampini and coworkers²⁷ who found that hospitalized patients treated with kyphoplasty were significantly less likely to be discharged to a skilled nursing home or another facility than patients treated with nonoperative care.

6. Medicare Decision and Expert Treatment Guidelines

The final report indicates there are no Medicare LCD's. As previously stated this is incorrect. Amongst others, Noridian, which is the Medicare MAC for the state of WA, does have a local coverage decision in place for kyphoplasty. This LCD does allow for coverage of balloon kyphoplasty for both osteoporosis and cancer relation patients.

7. Committee Decision

In its coverage denial of kyphoplasty, the Washington State Health Care states that *“the committee considered all the evidence and gave greatest weight to the evidence it determined, based on objective factors, to be the most valid and reliable”*.

Again, an extensive body of clinical evidence exists which describes clinical outcomes of patients with VCFS who were treated with kyphoplasty. As of April, 2010, this evidence consisted of 97 peer-reviewed publications and included randomized controlled trials, prospective comparative trials, a national registry, and large case series. Without exception, each of these studies reported positive clinical outcomes (improvements in pain, disability, mobility, and quality of life) for the patients treated with kyphoplasty. In addition to this demonstrated effectiveness in treating VCFs, kyphoplasty has established an excellent record of safety. It is felt that the committee did not fully consider this body of clinical evidence in its decision to deny coverage for kyphoplasty procedures.

In closing, we hope the committee will come to understand the importance of balloon kyphoplasty as a treatment option for patients. It is expected in the very near future, that other key clinical evidence for balloon kyphoplasty will be published. It is our hope that at that time, WA State will reconsider its decision and allow coverage of kyphoplasty.

Bibliography

1. Lau E, Ong K, Kurtz S, et al. Mortality following the diagnosis of a vertebral compression fracture in the Medicare population. *J Bone Joint Surg Am.* 2008 Jul;90(7):1479-86.
2. Phillips FM, Todd Wetzel F, Lieberman I, Campbell-Hupp M. An in vivo comparison of the potential for extravertebral cement leak after vertebroplasty and kyphoplasty. *Spine* 2002;27(19):2173-8; discussion 8-9.
3. Phillips FM, Wetzel TF, Lieberman I, et al. An in-vivo comparison of the potential for extravertebral cement leak after vertebroplasty and kyphoplasty. *Spine* 2002;27:2173-2178.
4. Phillips FM, Wetzel TF, Lieberman I, et al. An in-vivo comparison of the potential for extravertebral cement leak after vertebroplasty and kyphoplasty. *Spine* 2002;27:2173-2178.
5. Radvany M. Research Reporting Standards for Percutaneous Vertebral Augmentation. *J Vasc Interv Radiol* 2009; 20:1279-1286)
6. Lee MJ, Dumonski M, Cahill P, et al. Percutaneous treatment of vertebral compression fractures. A meta-analysis of complications. *Spine* 2009;34(11):1228-1232.
7. Taylor RS, Taylor RJ, Fritzell P. Balloon kyphoplasty and vertebroplasty for vertebral compression fractures: a comparative systematic review of efficacy and safety. *Spine* 2006; 31:2747-55. One or more authors were paid Medtronic consultants. Medtronic supported this study.
8. Hulme PA, Krebs J, Ferguson SJ, Berlemann U. Vertebroplasty and kyphoplasty: a systematic review of 69 clinical studies. *Spine* 2006; 31:1983-2001. One or more authors were paid Medtronic faculty. Medtronic did not support this study.
9. Lad SP, Patil CG, Lad EM, et al. National trends in vertebral augmentation procedures for the treatment of vertebral compression fractures. *Surg Neurol.* 2009 May;71(5):580-4.
10. Garfin SR, Yuan HA, Reiley MA. New technologies in spine: kyphoplasty and vertebroplasty for the treatment of painful osteoporotic compression fractures. *Spine.* 2001 Jul 15;26(14):1511-5.
11. Brunton S, Carmichael B, Gold D, et al. Vertebral compression fractures in primary care: recommendations from a consensus panel. *Fam Pract.* 2005 Sep;54(9):781-8.
12. Hussein MA, Vrionis FD, Allison R, Berenson J., et al. The role of vertebral augmentation in multiple myeloma: International Myeloma Working Group Consensus Statement. *Leukemia.* 2008 Aug;22(8):1479-84.
13. Chung HJ, Chung KJ, Yoon HS, et al. Comparative study of balloon kyphoplasty with unilateral versus bilateral approach in osteoporotic vertebral compression fractures. *Int Orthop.* 2008 Dec;32(6):817-20.
14. Theodorou DJ, Theodorou SJ, Duncana TD, et al. Percutaneous balloon kyphoplasty for the correction of spinal deformity in painful vertebral body compression fractures. *Clin Imaging.* 2002 Jan-Feb;26(1):1-5.
15. Wardlaw D, Cummings SR, Van Meirhaeghe, J et al. Efficacy and safety of balloon kyphoplasty compared with nonsurgical care for vertebral compression fracture (FREE): a randomized controlled trial. *Lancet* 2009;373:1016-24.
16. CMS MEDPAR data files from CY09
17. American Academy of Orthopaedic Surgeons Guidelines: <http://www.aaos.org/Research/guidelines/SCFguideline.pdf>
18. Suzuki N, Ogikubo O, Hansson T. The course of the acute vertebral body fragility fracture: its effect on pain, disability and quality of life during 12 months. *Eur Spine J.* 2008 Oct;17(10):1380-90.
19. Wardlaw D, Cummings SR, Van Meirhaeghe, J et al. Efficacy and safety of balloon kyphoplasty compared with nonsurgical care for vertebral compression fracture (FREE): a randomized controlled trial. *Lancet* 2009;373:1016-24.
20. Lindsay RE, Pack S, Li Z. Longitudinal progression of fracture prevalence through a population of postmenopausal women with osteoporosis. *Osteoporos Int* (2005) 16: 306–312

-
21. Taylor RS, Fritzell P, Taylor RJ. Balloon kyphoplasty in the management of vertebral compression fractures: an updated systematic review and meta-analysis. *Eur Spine J* 2007;16:1085-100.
 22. Hulme PA, Krebs J, Ferguson SJ, Berlemann U. Vertebroplasty and kyphoplasty: a systematic review of 69 clinical studies. *Spine* 2006;31:1983-2001.
 23. Hadjipavlou AG, Tzermiadianos MN, Katonis PG, Szpalski M. Percutaneous vertebroplasty and balloon kyphoplasty for the treatment of osteoporotic vertebral compression fractures and osteolytic tumours. *J Bone Joint Surg Br* 2005;87:1595-604.
 24. Eck JC, Nachtigall D, Humphreys SC, Hodges SD. Comparison of vertebroplasty and balloon kyphoplasty for treatment of vertebral compression fractures: a meta-analysis of the literature. *Spine J* 2008;8:488-97.
 25. Bouza C, Lopez T, Magro A, Navalpotro L, Amate JM. Efficacy and safety of balloon kyphoplasty in the treatment of vertebral compression fractures: a systematic review. *Eur Spine J* 2006:1-18.
 26. Ström O, Leonard C, Marsh D, et al. Cost-effectiveness of balloon kyphoplasty in patients with symptomatic vertebral compression fractures in a UK setting. *Osteoporos Int.* 2010 Sep;21(9):1599-608.
 27. Zampini JM, White AP, McGuire KJ. Comparison of 5766 vertebral compression fractures treated with or without kyphoplasty. *Clin Orthop Relat Res.* 2010 Jul;468(7):1773-80.

AANS/CNS SECTION ON DISORDERS OF THE SPINE AND PERIPHERAL NERVES



American
Association of
Neurological
Surgeons

A Section of the
American Association of Neurological Surgeons
and
Congress of Neurological Surgeons



CHAIRPERSON

Ziya L. Gokaslan, M.D., F.A.C.S.
Johns Hopkins University Hospital
Department of Neurosurgery
Phone: (443) 287-4934
Fax: (410) 502-3399
E-mail: zgokas11@jhmi.edu

SECRETARY

Michael W. Groff, MD
Beth Israel Deaconess Med. Ctr.
Phone: (617) 632-9911
Fax: (617) 632-0949
E-mail: mgroff@bidmc.harvard.edu

TREASURER

R. John Hurlbert, MD PhD
Foothills Med. Ctr./Clinical Neuroscience
Phone: (403) 283 4449
Fax: (403) 283 5559
E-mail: jhurlber@ucalgary.ca

CHAIRPERSON-ELECT

Christopher Wolfla, M.D.
Medical College of Wisconsin
Department of Neurosurgery
Phone: (414) 805-5400
Fax: (414) 955-0115
E-mail: cwolfla@mcw.edu

IMMEDIATE PAST CHAIRPERSON

Daniel K. Resnick, MD
University of Wisconsin
Phone: (608) 263-1411
Fax: (608) 263-1728
E-mail: resnick@neurosurg.wisc.edu

MEMBERS-AT-LARGE

Mark R. McLaughlin, MD
E-mail: m.mclaughlin@princetonbrainandspine.com

Christopher E. Wolfla, MD
E-mail: cwolfla@mcw.edu

Eric L. Zager, MD
E-mail: Eric.Zager@uphs.upenn.edu

February 18, 2011

Denise Santoyo
Program Coordinator, Health Technology Assessment
Washington State Health Care Authority
Phone: (360) 923-2742
Fax: (360) 923-2835
E-Mail: denise.santoyo@hca.wa.gov

Subject: Health Technology Clinical Committee Findings and Coverage
Decision on Vertebroplasty, Kyphoplasty & Sacroplasty

Ms. Santoyo,

The American Association of Neurological Surgeons/Congress of Neurological Surgeons Joint Section on Disorders of the Spine and Peripheral Nerves would like to thank the you and Washington State Health Care Authority for the opportunity to provide comment on the Washington State Health Care Authority Health Technology Clinical Committee Findings and Coverage Decision on Vertebroplasty, Kyphoplasty & Sacroplasty from December 10, 2010. While we applaud the goal of improving patient care through application of scientifically grounded therapies, we have concerns regarding the over generalized conclusion that Vertebroplasty, Kyphoplasty and Sacroplasty procedures are not a covered benefit.

Coverage decisions frequently determine access to appropriate medical care, and based on your coverage decision, a patient with a pathological spinal fracture and kyphosis from multiple myeloma would be deprived the less invasive option of kyphoplasty and radiation, and possibly undergo a larger surgical procedure or accept unneeded disability. In a systematic review of the available literature regarding the use of vertebroplasty and kyphoplasty in patients with painful compression fractures associated with metastatic spine disease, there is a strong recommendation for vertebral augmentation as safe and effective in providing pain relief and improving functional outcome in patients with vertebral body fractures (Mendel 2009). The authors performed a review of the English literature with the results reviewed and discussed through consensus among a multidisciplinary panel of expert members of the Spine Oncology Study Group, commonly known as a Delphi technique, and with recommendations made according to the Guyatt Guidelines. They identified a total of 1665 abstracts, with 28 articles using vertebroplasty reported on 877 patients and 1599 treated levels, and 12 articles using kyphoplasty reported on 333 patients and 481 treated levels. They noted low complication rate, from 0% to 0.5%, and without

any neurologic complications. The most important finding was that pain and functional outcomes were universally successful using either technique. Based on this, they noted a strong recommendation for vertebral augmentation as safe and effective in providing pain relief and improving functional outcome in patients with vertebral body fractures and axial pain due to metastatic disease.

1. E Mendel, E Bourekas, P Gerszten, JD Golan. Percutaneous Techniques in the Treatment of Spine Tumors: What Are the Diagnostic and Therapeutic Indications and Outcomes?. Spine Volume 34, Number 22S, pp S93–S100.

We believe the conclusions drawn regarding the use of vertebral augmentation in vertebral insufficiency fractures are over broad in combining the select patients with acute compression fractures who benefit from vertebral augmentation, with those patients beyond 10-12 weeks who do not benefit from such procedures. In patients with acute fractures, less than 3 months, with well-defined pathology, both vertebroplasty and kyphoplasty are appropriate and beneficial medical options for patients. Published articles between 1980 and 2008 reporting outcomes after vertebral augmentation for osteoporotic fractures have generally supported these procedures (McGirt 2009). There were 74 studies for use of vertebroplasty in osteoporotic compression fractures, with 1 Level I, 3 Level II, and 70 Level IV studies; in addition to 35 studies for use of kyphoplasty with 2 Level II and 33 Level IV studies. Analysis noted superior pain control within the first 2 weeks of intervention compared with optimal medical management for osteoporotic vertebral compression fractures, with fair evidence (Level II–III) that vertebral augmentation results in less analgesia use, less disability, and greater improvement in general health when compared with optimal medical management within the first 3 months after intervention. Note that by 2 years after intervention, vertebral augmentation provides a similar degree of pain control and physical function as optimal medical management. However, much like a cavity filling, vertebral augmentation is meant for the treatment of the acute fracture and not for the long term treatment of osteoporosis at 2 years.

1. MJ McGirt, SL Parker, JP Wolinsky, et. Al. Vertebroplasty and kyphoplasty for the treatment of vertebral compression fractures: an evidenced-based review of the literature. The Spine Journal 9 (2009) 501–508.

There has been much talk regarding the studies by Buchbinder and Kallmes which included sham procedures. These two studies, which form the basis of your coverage decision, were downgraded by our AANS/CNS Joint Guidelines Committee (JGC) on the basis of flaws in the study, which have been acknowledged by the authors of the American Academy of Orthopedic Surgery (AAOS) guidelines, including the fact that they were both underpowered and that the external validity (generalizability) of these studies is questionable. Therefore, the “applicability” which is the process for determining the strength of recommendation is severely affected. These two studies have also been prominent in the AAOS guidelines on vertebral augmentation. In addition to the disagreement on the grading and interpretation of the studies by Buchbinder and Kallmes, our JGC expressed concern that two studies (FREE and Grafe) were unjustifiably downgraded to a level II, and inconsistent with the AAOS methodology used to craft their first recommendation. Due to these and other issues regarding the process and interpretation of the available articles, the AANS and CNS chose not to endorse the AAOS document.


In summary, we believe that vertebral augmentation procedures are appropriate and beneficial in appropriately selected patients. The current coverage decision made by Washington State Health Care Authority is therefore over broad in combining the patients who benefit from

vertebral augmentation with those who do not. As coverage decisions frequently determine access to appropriate medical care, subsets of patients will be deprived access to appropriate and beneficial medical care.

Again, thank you for this opportunity to comment and we look forward to seeing the Health Technology Clinical Committee reconsider their Coverage Decision on Vertebroplasty, Kyphoplasty & Sacroplasty during their meeting on March 18, 2011.

If you have any questions, please feel free to contact Joseph Cheng, MD, AANS/CNS Coding and Reimbursement Committee at joseph.cheng@vanderbilt.edu or Cathy Hill, Senior Manager, Regulatory Affairs AANS/CNS at chill@neurosurgery.org.

Sincerely,

A handwritten signature in black ink, appearing to read "Ziya Gokaslan MD". The signature is stylized and cursive.

Ziya Gokaslan, MD, Chair
AANS/CNS Joint Section on Disorders of the
Spine and Peripheral Nerves

Percutaneous Techniques in the Treatment of Spine Tumors

What Are the Diagnostic and Therapeutic Indications and Outcomes?

Ehud Mendel, MD, FACS,* Eric Bourekas, MD,† Peter Gerszten, MD,‡
and Jeff D. Golan, MD, FRCS(c)§

Study Design. Systematic review of the literature.

Objective. Should cement augmentation procedures such as vertebroplasty and kyphoplasty be used in patients with painful compression fractures associated with metastatic spine disease? What is the role of embolization in the treatment of metastatic spine disease?

Summary of Background Data. Vertebral augmentation is commonly employed in treating osteoporotic fractures and is now increasingly used in the management of pain in patients with spinal tumors. Intra-arterial and transcatheter embolization techniques are also available in the management of spinal tumors. To date, the effectiveness and safety of these procedures have not been adequately demonstrated.

Methods. A review of the English literature was performed in Pub-Med. One search was performed using the following keywords: cancer, tumor, vertebroplasty, kyphoplasty, vertebral augmentation, outcome, safety, pain, and quality of life. A Second search was performed using the keywords: embolization, spinal, and tumors. Original studies reporting on at least 10 patients were included and systematically reviewed. The results were reviewed and discussed through consensus among a multidisciplinary panel of expert members of the Spine Oncology Study Group. Recommendations were made according to the Guyatt Guidelines.

Results. A total of 1665 abstracts were identified. Twenty-eight articles using vertebroplasty reported on 877 patients and 1599 treated levels. Medical and neurologic complications varied from 0% to 7.1% and 0% to 8.1%, respectively. Twelve articles using kyphoplasty reported on 333 patients and 481 treated levels. Medical complication rates varied from 0% to 0.5%, without any neurologic complications. Pain and functional outcomes were universally successful using either technique. Ten studies on embolization reported on 330 patients. There were 4 permanent complications (1.4%). Complete or partial embolization was possible in 97.5% with an estimated reduction of intraoperative blood loss of 2.3 L.

Conclusion. There is strong recommendation and moderate evidence for vertebral augmentation as safe

and effective in providing pain relief and improving functional outcome in patients with vertebral body fractures and axial pain due to metastatic disease. There is a strong recommendation and very low evidence for embolization techniques as safe and effective in decreasing intraoperative blood loss in hypervascular tumors.

Key words: vertebral augmentation, vertebroplasty, kyphoplasty, embolization, spine cancer, spinal tumors.
Spine 2009;34:S93–S100

The advent of percutaneous procedures has greatly expanded treatment options in the management of primary and secondary spine tumors. Their limited invasiveness makes them attractive to a variety of clinicians and patients alike.

Vertebroplasty and kyphoplasty are among the most commonly used treatments in spinal oncology for axial mechanical pain. Vertebroplasty is a percutaneous technique where radiopaque polymethylmethacrylate cement is injected under fluoroscopic control, while kyphoplasty involves initial inflation of a balloon within the vertebral body before injection of polymethylmethacrylate. The cement reinforces and stabilizes fractures.¹ It may also have antitumor activity as a result of cytotoxicity,² and thermal effect.³ In addition, vertebral biopsies can be readily performed during these procedures if the etiology of vertebral abnormality is unclear or to confirm a suspected pathology.

Embolization is another frequently performed technique in the treatment of spinal tumors. It is usually intra-arterial but may also be done directly via transcatheter routes. The main indication before surgery is to reduce blood loss during resection of vascular tumors. Additionally, embolization may be used in a palliative fashion for pain and local oncological control of tumors in patients that are not operative candidates.

A growing international experience with these percutaneous procedures is clarifying their usefulness and indications. The goal of this study was to systematically review the published literature on the safety and effectiveness of vertebroplasty, kyphoplasty, and embolization in the treatment of spinal tumors and then make treatment recommendations based on the best available literature and consensus expert opinion.

■ Methods

Vertebral Augmentation

A systematic review of the English literature was performed to answer 2 research questions that were determined through con-

From the *Department of Neurosurgery, The Ohio State University Medical Center and The James Cancer Center, Columbus, OH; †Department of Radiology, The Ohio State University Medical Center, Columbus, OH; ‡Department of Neurosurgery, University of Pittsburgh Medical Center, Pittsburgh, PA; and §Department of Neurosurgery, McGill University, Jewish General Hospital, Montreal, Canada. The manuscript submitted does not contain information about medical device(s)/drug(s).

No funds were received in support of this work. No benefits in any form have been or will be received from a commercial party related directly or indirectly to the subject of this manuscript.

Address correspondence and reprint requests to Ehud Mendel, MD, FACS, N1037 Doan Hall, 410 W 10th Ave, Columbus, OH 43210; E-mail: ehud.mendel@osumc.edu

sensus following discussion among a multidisciplinary panel of experts (Spine Oncology Group). Question 1: Should cement augmentation be used in patients with painful compression fractures associated with metastatic spine disease? Question 2: Should embolization procedures be used in hypervascular metastatic tumors?

The first search was performed using PubMed with the following keywords: (1) cancer or tumor; (2) vertebroplasty, kyphoplasty, or vertebral augmentation; and (3) outcome, safety, pain, or quality of life. All abstracts were reviewed between September 3, 2008 and September 30, 2008. Original peer-reviewed articles including at least 10 patients with primary or secondary spinal tumors were included. Review articles, biomechanical, and basic science studies were excluded. Studies combining vertebral augmentation with other treatment methods such as radiofrequency ablation, radiosurgery, radiation therapy, and alcohol ablation were included. Articles including osteoporotic fractures or cementoplasty of bones other than vertebrae were only included if relevant primary clinical data were reported separately and specifically on at least 10 patients with spinal tumors. The references of these articles were reviewed to identify additional studies. The second search was performed using PubMed with the following keywords: (1) embolization; (2) spinal; and (3) tumors. The search was performed on December 15, 2008. Review articles were excluded. Only studies that included at least 10 patients were reviewed. Selected articles were graded according to the US Preventive Services Task Force hierarchy of research design.⁴

Studies were reviewed using a standardized data collection form. The type of study (prospective or retrospective) was noted. Data were collected on technique (vertebroplasty or kyphoplasty, fluoroscopy or computed tomography-assisted, type of cement used, levels treated, uni- or bilateral injection), treatment indications and exclusions, the total number of patients and levels treated, the total number of patients treated with tumors and the number of levels treated, and the type of tumors treated. The methods of clinical and radiologic pre- and postoperative evaluations were recorded. All temporary and permanent complications were collected, including locations and consequences of cement extravasations, as well as adjacent segment fractures and new levels requiring treatment. Some authors were contacted directly to clarify certain aspects of their studies.

A meta-analysis using the prospective studies was not possible due to the heterogeneity of study designs, inconsistent reporting of complications, and the use of different grading scales for pain and functional outcomes. Some studies reported results of their statistical analyzes by grouping osteoporotic and tumor patients, whereas others did not perform statistical analysis on pain and functional outcomes. Whenever possible, primary data were collected to calculate the mean preoperative, mean postoperative, and mean improvement in pain and functional outcomes as determined by the various scales and questionnaires used in each study. Changes in preoperative and postoperative scores were analyzed using one-sided paired Student *t* test. Standard deviation and the 95% confidence intervals were also calculated with an alpha value of 0.05. All statistical analyzes were performed using Microsoft Excel.

The results of the literature reviews, evidentiary tables, and preliminary conclusions were used to answer 2 research questions. A summary of the best available literature and answers to the questions were presented to the SOSG. A consensus-based decision-making process using a modified Delphi approach was then taken by the SOSG to make final treatment recom-

mendations. The recommendations were either strong or weak as per the GRADE recommendation methodology.⁵

■ Results

Vertebral Augmentation

A total of 1396 abstracts were identified using the various keywords. Many of these articles were identified on multiple searches. All abstracts were reviewed and the complete texts of all potential articles were retrieved. Six prospective⁶⁻¹¹ (level II) and 22 retrospective articles¹²⁻³³ (level III) using vertebroplasty reported on a total of 877 patients and 1599 treated levels (Table 1). Seven prospective³⁴⁻⁴⁰ (level II) and 5 retrospective articles^{14,23,25,30,41} (level III) using kyphoplasty reported on 333 patients and 481 treated levels (Table 2). Of these, 4 studies provided data on a mixed group of patients that were treated using both vertebroplasty and kyphoplasty.^{14,23,25,28} One kyphoplasty study³⁸ was a 2-year follow-up that included patients published in a 1-year follow-up study.³⁹ One vertebroplasty study was published in 2 different journals.^{9,10}

All studies on vertebral augmentation procedures were performed primarily on metastatic lesions and/or multiple myeloma (Tables 1, 2), except 1 study.²⁴ In prospective studies, vertebroplasty⁶⁻¹¹ was used in 98 patients to treat compression fractures due to metastatic disease (74%), multiple myeloma (24%), and hemangiomas (2%). Kyphoplasty³⁴⁻⁴⁰ was used in 204 patients to treat multiple myeloma (55%) and metastases (45%). Some reported procedures performed on patients with hemangiomas,^{11,23,27,30,32,33,41} although only 3 patients were clearly noted to have undergone kyphoplasty.⁴¹ Five patients underwent vertebroplasty for lymphoma,³² 1 patient had chondrosarcoma,¹⁹ and 1 patient had hemangiopericytoma.³³

Pain Relief

Most studies reported on pain following vertebral augmentation. The various methods of evaluating pain included the Visual Analog Scale, Verbal Rating Scale, McGill and Melzack classification, Site Specific Pain Score, Pain Intensity Numerical Rating Scale, Short-Form 36 Bodily Pain subscore, and self-designed 4-point pain questionnaires to determine whether patients had excellent improvement, good improvement, no improvement, or deterioration. All the studies reported improvement in pain scores. In all, 3 of the studies did not include specific data on pain.^{17,23,31} Prospective studies had more detailed pre- and postoperative data and most demonstrated statistically significant results (Table 3). Both techniques were successful at improving pain.

Functional Outcome

Some studies reported on function following vertebral augmentation. The various methods of evaluating function included the Eastern Cooperative Oncology Group Performance Scale, the Townsend Functional Assess-

Table 1. Evidentiary Table for Question 1

Study	LE	Tumor			Total	Extravasation %			Complications %	
		Patients	Levels	Types		Epid	Distal	Sympt	Med	Neuro
Cahana <i>et al</i> ⁶	II	22	48	M, MM				0	0	0
Cheung <i>et al</i> ⁷	II	13		M		1		7.7	0	7.7%
Ramos <i>et al</i> ⁸	II	12	19	MM	84	2	0	0	0	0
Cotten <i>et al</i> ^{9,10}	II	37	40	M, MM	72.5	57.5	0	2	0	8.1
Anselmetti <i>et al</i> ¹¹	II	14	42	M, MM, H	33			0	0	0
Anselmetti <i>et al</i> ¹²	III	50		M		3.9*		3.9*	0.3*	3.9*
Jang and Lee ¹³	III	28	72	M, MM	72.2	26.9	5.8	3.8	7.1	0
Fourney <i>et al</i> ¹⁴	III		65	M, MM	9.2	0	0	0	0	0
Barragan <i>et al</i> ¹⁵	III	117	304	M, MM	139				1.7	3.4
Calmels <i>et al</i> ¹⁶	III	52	103	M	50.5	26.9	7.7	13.5	5.1	6.8
McDonald <i>et al</i> ¹⁷	III	67	114	MM	19	4	0	0	0	0
Alvarez <i>et al</i> ¹⁸	III	21	27	M	44	37	0	0	0	4.8
van der Linden <i>et al</i> ¹⁹	III	12	12	M, C	58.3		0	0	0	0
Weill <i>et al</i> ²⁰	III	37	52	M	38.5	1	1	9.6	5.4	8.1
Shimony <i>et al</i> ²¹	III	50	129	M, MM				0	0	0
Hoffmann <i>et al</i> ²²	III	14	14	M, MM	57.1	14.3	0	0	0	0
Hentschel <i>et al</i> ²³	III	37†	102*	M, MM, H	19.6*	1*	0	1*	0	1*
Chen <i>et al</i> ²⁴	III	12	12	H				0	0	0
Kose <i>et al</i> ²⁵	III	16	28	MM				0	3.6	0
Sun <i>et al</i> ²⁶	III	32	51	M		7.8	0	0	0	0
Muto <i>et al</i> ²⁷	III	30		M, H	37.8*			1.9*	0	1.9*
Masala <i>et al</i> ²⁸	III	33†	40†	M, MM, H†	35			0	0	0
Caudana <i>et al</i> ²⁹	III	39	62	M, MM	69.4			3.2	0	3.2
Masala <i>et al</i> ³⁰	III	64	198	MM		0	0	0	0	0
Mont'Alverne <i>et al</i> ³¹	III	12	12	M	58.3		8.3	8.3	0	16.7%
Barbero <i>et al</i> ³²	III	37	53	M, MM, H, L	19.6*	5.2*	0	0	0	0
Anselmetti <i>et al</i> ³³	III	19		M, MM, HP, H	58*		3.5*	0	0.9*	0

Studies using vertebroplasty to treat spine tumors (M indicates metastasis; MM, multiple myeloma or plasmacytoma; H, hemangioma; C, chondrosarcoma; L, lymphoma; HP, hemangiopericytoma).
 Question 1: Should cement augmentation be used in patients with painful compression fractures associated with metastatic spine disease?
 *Data reported in a mixed group of osteoporosis and tumor.
 †Data reported in a mixed group of kyphoplasty and vertebroplasty.
 LE indicates level of evidence; Epid, Epidural or foraminal; Sympt, symptomatic; Med, medical; Neuro, neurological.

ment Scale, the Oswestry Disability Index, the Frankel scale, the Roland Morris Disability Questionnaire, the Short Form 36 Physical Function, and self-designed 3- and 4-point gait or mobility scales. Only 5 of the retrospective studies included specific data on func-

tion.^{17,18,21,24,29} In all 5 studies, functional outcome improved. Prospective studies had more detailed pre- and postoperative data and most demonstrated statistically significant results (Table 3). Both techniques were successful at improving function.

Table 2. Evidentiary Table for Question 1

Study	LE	Tumor			Complications		Extravasation %				Correction	
		Patients	Levels	Types	Med	Neuro	Total	Epid	Distal	Sympt	Height	Kyphosis
Khanna <i>et al</i> ³⁴	II	56		MM	0.5*							
Gerszten <i>et al</i> ³⁵	II	26	26	M	0	0	0	0	0	0	y	y
Dudeney <i>et al</i> ³⁶	II	18	55	MM	0	0	4	2	0	0	y	
Lane <i>et al</i> ³⁷	II	19	46	MM	0	0	26.3	2.6			y ^{ss}	
Pflugmacher <i>et al</i> ³⁸	II	65	99	M	0	0	12.1			0	y ^{ss}	y ^{ss}
Pflugmacher <i>et al</i> ³⁹	II	31	64	M	0	0	12.5		0	0	y	y
Pflugmacher <i>et al</i> ⁴⁰	II	20	48	MM	0	0	10.4	0	0	0	y ^{ss}	y ^{ss}
Atalay <i>et al</i> ⁴¹	III	10	19	M, MM, H	0	0	2.6*	0		0		
Fourney <i>et al</i> ¹⁴	III		32	M, MM	0	0	0	0	0	0	y ^{ss}	y ^{ss}
Hentschel <i>et al</i> ²³	III	37†	30*	M, MM, H	0	0	0	0	0	0		
Kose <i>et al</i> ²⁴	III	18	22	MM	0	0						
Masala <i>et al</i> ³⁰	III	33†	40†	M, MM, H*	0	0	0	0	0	0	y	y

Studies using kyphoplasty to treat spine tumors (M indicates metastasis; MM, multiple myeloma or plasmacytoma; H, hemangioma).
 Question 1: Should cement augmentation be used in patients with painful compression fractures associated with metastatic spine disease?
 *Data reported in a mixed group of osteoporosis and tumor.
 †Data reported in a mixed group of kyphoplasty and vertebroplasty.
 LE indicates level of evidence; y, Yes (y^{ss} statistically significant); Epid, Epidural or foraminal; Sympt, symptomatic; Med, medical; Neuro, neurological.

Table 3. Pain and Functional Outcome Reported in Prospective Studies Using Vertebroplasty and/or Kyphoplasty

Prospective Study	Method	Scale Best-Worst	Patients	Preop (SD)	Postop (SD)	Follow-up	P
Pain							
Vertebroplasty							
Cahana <i>et al</i> ⁶	VRS	0–5	22	4.8 (0.4)	2.3 (1.1)		<0.001
Cheung <i>et al</i> ⁷	SPSS	0–10	13			12 w	<0.001
Ramos <i>et al</i> ⁸	VAS	0–10	12	7.5 (2.3)	3.3 (2.1)	4 w	<0.001
Anselmetti <i>et al</i> ¹¹	VAS	0–10	14	8.1 (1.4)	1.0 (1.0)	6 m	<0.001
Cotten <i>et al</i> ^{9,10}	McGill/Melzack	0–5	37†			36 h	
Kyphoplasty							
Khanna <i>et al</i> ³⁴	SF36-BP	100–0	56	28.2 (15.3)	48.0 (20.5)	55 w	<0.001
Gerszten <i>et al</i> ³⁵	VAS	0–10	26	7.5	2.8	4 w	
Dudney <i>et al</i> ³⁶	SF36-BP	100–0	18	23.2	55.4	7.4 m	<0.001
Lane <i>et al</i> ³⁷							
Pflugmacher <i>et al</i> ³⁹	VAS	0–10	20	8.2	1.9	3 m	<0.05
Pflugmacher <i>et al</i> ⁴⁰	VAS	0–10	65	8.3 (1.5)	2.9 (0.9)	3 m	<0.001
Function							
Vertebroplasty							
Cahana <i>et al</i> ⁶	ECOG-PS	0–4	22	1.9 (1.0)	0.9 (1.0)		<0.001
Cheung <i>et al</i> ⁷	TFAS	1–4	13			12 w	0.223
Ramos <i>et al</i> ⁸	ECOG-PS	0–4	12	3.1 (1.0)	2.4 (1.2)	4 w	0.035
Anselmetti <i>et al</i> ¹¹	ODI	0–100	14	63.3 (14.1)	10.6 (6.5)	6 m	<0.001
Cotten <i>et al</i> ^{9,10}							
Kyphoplasty							
Khanna <i>et al</i> ³⁴	SF36-PF	100–0	56	26.2 (22.2)	44.2 (26.2)	55 w	<0.001
Gerszten <i>et al</i> ³⁵							
Dudney <i>et al</i> ³⁶	SF36-PF	100–0	18	21.3	50.6	7.4 m	0.001
Lane JM <i>et al</i> ³⁷	ODI	0–100	19	48.9 (16.6)	32.6 (13.6)	3 m	<0.001
Pflugmacher <i>et al</i> ³⁹	ODI	0–100	20	71.5	22.0	3 m	<0.05
Pflugmacher <i>et al</i> ⁴⁰	ODI	0–100	65	8.1 (0.8)	3.3 (0.6)	3 m	<0.001

*Data analysis performed using primary data published in the article.

†Partial or complete pain relief obtained in 36/37 patients.

SD indicates standard deviation; VAS, Visual Analog Scale; SPSS, Site-Specific Pain Score; SF-36, short form-36; BP, bodily pain; PF, physical function; VRS, Verbal Rating Scale; ECOG-PS, Eastern Cooperative Oncology Group-Performance Scale; TFAS, Townsend Functional Assessment Scale; ODI, Oswestry Disability Index; RDQ, Roland Morris Disability Questionnaire.

In follow-up, w indicates weeks; m, months; h, hours.

Sagittal Alignment

Most of the studies using kyphoplasty reported some correction in sagittal alignment following surgery,^{14,28,35–38,40,41} but only 2 of these^{38,40} had reliable long-term data. In 1 study,⁴⁰ 20 patients with multiple myeloma were evaluated prospectively and all were available for 1-year follow-up. Initial improvement in vertebral body height was achieved in 64.5% of fractures by a mean of 4.3 mm ($P < 0.05$), while kyphotic deformity was corrected in 78.5% of patients by a mean of 6.3° ($P < 0.05$). At 1 year, the statistical significance was lost as height decreased by 1.1 mm and angulation deteriorated by 1.8°. In the other study,³⁸ 65 patients with metastatic lesions were treated prospectively and 41 of them were followed for 2 years. The initial height and kyphotic deformities were significantly improved; however, both variables returned to preoperative levels at 2 years.

Studies using vertebroplasty were inconsistent in reporting sagittal alignment. Some authors^{8,9,13,18} specified that none of their patients collapsed further, while progressive collapse of the treated level was reported in 3 patients.^{17,32}

Complications

Reported complications are generally medical, neurological, or technical. The prospective studies included 302

patients and reported one possible adverse medical event (Table 4). This was a myocardial infarction that occurred in the postanesthesia care unit, but it is unclear if the patient underwent kyphoplasty for osteoporosis or

Table 4. Summary of Prospective Studies Using Vertebroplasty and Kyphoplasty

Prospective Studies	Vertebroplasty	Kyphoplasty
No. studies	5	6
No. tumor patients	98	204
No. tumor levels	152*	330†
Tumor types per patient		
Metastases	73 (74.5%)	91 (44.6%)
Multiple myeloma	23 (23.5%)	113 (55.4%)
Hemangioma	2 (2.0%)	0
Complications		
Medical	0	1/204 (0.5%)‡
Neurological	4 (4.1%)	0
Corrective surgery	3 (3.1%)	0
Extravasation		
Total per level	59/101 (58.4%)	12/239 (12.1%)
Symptomatic patients	3/98 (3.1%)	0
Adjacent vertebral fracture	0	6/204 (2.9%)
Corrective surgery	0	3/204 (1.5%)

*Number may be higher, as Cheung *et al*⁷ did not report number of levels per tumor patient.

†Number may be higher, as Khanna *et al*³⁴ did not report number of levels per tumor patient.

‡Khanna *et al*³⁴ reported 1 myocardial infarction without specifying if this was a tumor patient.

Table 5. Summary of Studies Using Embolization to Treat Spinal Tumors

Study	Controls	Embolized Patients	Completely Embolized	Unable to Embolize	Permanent Complications	Transient Complications	Tumors	Embolic Agents	Blood Loss
Sundaresan <i>et al</i> ⁴²	13	17	11	2	0	3	Renal (30)	Alcohol (usually) PVA	Embolized 2200 mL
Smith <i>et al</i> ⁴³	0	20	19	0	0	1	Renal (14)	PVA (usually), coils, Gelfoam	871 mL
Vetter <i>et al</i> ⁴⁴	0	38	27	2	2	1	Thyroid (8), multiple myeloma (7), breast (6)	PVA (26), coils (25), Gelfoam	2400 mL
Jayakumar <i>et al</i> ⁴⁵	0	12	11	0	0	0	Hemangiomas (12)	Lyophilized dura (6), Gelfoam (5), cyanoacrylate (1)	
Berkefield <i>et al</i> ⁴⁶	10	59	48	0	0	1	Renal (32), prostate (7), thyroid (6)	PVA only (90), PVA and coils (24), coils only (26)	PVA only 1800 mL PVA and coils 1850 mL Coils only 2650 mL Control 4350 mL
Shi <i>et al</i> ⁴⁷	0	18	15	0	0	0	Renal (2), other (16)	PVA	
Manke <i>et al</i> ⁴⁸	10	17	10	1	0	1	Renal (17)	PVA, gelfoam	Embolized 1500 mL Control 5000 mL
Prabhu <i>et al</i> ⁴⁹	0	51	34	2	2*	0	Renal (30), sarcoma (8)	PVA (9), PVA and coils (38), PVA, coils, and Gelfoam (2)	Embolized 2600 mL
Wirbel <i>et al</i> ⁵⁰	20	21	19	0	0	0	Renal, thyroid, other	PVA (2), coils (21)	Embolized 1650 mL Control 3880 mL
Guzman <i>et al</i> ⁵¹	0	24	22	0	0	0	Renal (14), thyroid (4)	PVA (24), coils (3)	Complete embo 1900 mL Partial embo 5500 mL
Total	53	277	21680.0%	72.5%	41.4%	72.5%	>50% renal	PVA most common	Embolized 2004 mL Control 4278 mL

The level of evidence is III for all studies.

Question 2: Should embolization procedures be used in hypervascular metastatic tumors?

*Asymptomatic cerebellar infarcts.

PVA indicates polyvinyl alcohol particle embolization.

multiple myeloma.³⁴ None of the retrospective studies on kyphoplasty reported medical complications, while the retrospective vertebroplasty studies identified a total of 11,^{13,15,16,25} including 7 pulmonary embolisms,^{13,15,16} 1 hemothorax,¹⁶ 2 soft tissue hematomas,¹⁵ 1 wound infection,²⁵ and 1 death, which resulted from a symptomatic pulmonary embolism.¹⁵ Taken together, the medical complication rate was 1.3% for vertebroplasty and 0.3% for kyphoplasty.

The reported range of radiologic extravasation in vertebroplasty was 9.2% to 139% (multiple areas of extravasations occurred per level), whereas the range was 0% to 26.3% in kyphoplasty. The reported range of symptomatic extravasation in vertebroplasty was 0% to 13.5%, while there were none in kyphoplasty. These complications were better described in the prospective vertebroplasty studies and their sequelae resulted in the 4 neurologic complications (4.1%); 1 patient had a femoral neuropathy due to cement leakage into the psoas muscle that resolved within 3 days,⁹ 2 had radiculopathies from nerve root compression following cement leakage and required surgical decompression,⁹ and 1 had cement leakage into the spinal canal causing dorsal column dysfunction that required surgical decompression.⁶ The retrospective vertebroplasty studies reported a total of 27 patients^{15,16,18,20,21,23,29,31} who had symptomatic leaks that led to neurologic deficits (3.4%) that resulted in 4 decompressive^{16,20} procedures (0.5%).

Adjacent segment fractures were reported in 6 of the 204 patients^{38,40} in the prospective kyphoplasty studies (2.9%). These fractures were symptomatic and required subsequent kyphoplasty correction in 3 cases

(1.5%).^{38,40} One patient had progressive kyphosis despite successful kyphoplasty and required a decompressive procedure at this level.³⁵ No other adjacent segment fractures were reported in the retrospective studies. In 1 case,²⁵ the balloon ruptured during inflation without harming the patient. In the prospective vertebroplasty studies, no adjacent segment compression fractures were reported following vertebroplasty. In the retrospective vertebroplasty studies, 17 patients were reported to have had adjacent level fractures, with 9 who required repeat vertebroplasty.^{17,24,29,32,33} The total rate of adjacent segment fracture following vertebroplasty was 1.9% and 1.8% following kyphoplasty.

Embolization

The literature search yielded 269 articles of which 201 were in English. No prospective studies were found. Ten retrospective studies⁴²⁻⁵¹ (level III) were included in the analysis (Table 5). A total of 330 patients were reported, 53 controls who were not embolized and 277 patients who were embolized. Of the embolized patients, 216 of 277 (80.0%) were embolized completely, 54 of 277 (19.5%) were embolized partially, and 7 of 277 (2.5%) could not be embolized. Renal cell carcinoma metastases were the most common lesions treated accounting for more than 50% of lesions treated. Thyroid, breast, and prostate metastases, multiple myeloma, hemangiomas, giant cell tumors, and sarcomas were also among the lesions treated. Polyvinyl alcohol (PVA) was most commonly used for embolization, with coils, alcohol, lyophilized dura, Gelfoam, Dextran, and cyanoacrylate also used.

The overall risk of neurologic complications due to embolization was 4.0%. There were 4 (1.4%) permanent neurologic complications, with 2 being minor as both were asymptomatic cerebellar infarcts seen on magnetic resonance imaging and 2 major brain stem infarcts in embolization of 2 cervical tumors. Transient neurologic complications were seen in 7 (2.5%) and included 2 cases of paraparesis, a conus medullaris syndrome with urinary retention, numbness of the lower extremity, myoclonus, dizziness, and progressive lower extremity weakness, which resolved after surgery. Non-neurologic complications were apparently not reported as there were no groin hematomas, allergic reactions, or contrast induced renal failures. There were no skin or muscle necrosis complications reported.

Blood loss at the time of surgery was significantly reduced with preoperative embolization by over 50%. The average blood loss of those who were embolized was 2004 mL with a range of 1500 to 5500 mL, whereas for controls it was 4278 mL with a range of 3880 to 5000 mL. Sundaresan *et al*⁴² noted major complications at the time of surgery related to excessive blood loss in patients not embolized. Berkefeld *et al*⁴⁶ compared the blood loss between those embolized and controls and compared embolization with particles, particles and coils, and coils alone, and concluded that particle and particle-coil embolization showed very similar results and reduced hemorrhage significantly as compared to unembolized and coil only occlusion.

■ Discussion

Vertebral augmentation techniques provide a minimally invasive alternative to open surgery in controlling pain due to pathologic compression fractures in selected patients. In some instances, such as multiple myeloma, vertebral augmentation is the treatment of choice due to poor bone quality that frequently precludes successful implantation of screw rod constructs and cages for complex reconstruction. Similarly, transarterial embolization is an important adjuvant to open surgery when dealing with vascular tumors and may be the preferred treatment modality for some tumors, such as aneurysmal bone cysts (ABCs).⁵²

Vertebral augmentation is predominantly used to treat painful vertebrae with osteolysis or compression fractures secondary to tumor infiltration. All studies found a statistically significant improvement in pain and function after surgery. Some correction of kyphotic deformity and vertebral collapse was reported following kyphoplasty,^{35–38,40} but this may be temporary.³⁸ The rate of radiologic cement extravasation was 4 times higher using vertebroplasty and resulted in 3 cases of symptomatic cement extravasation following vertebroplasty, which required surgical decompression. Adjacent segment vertebral body fractures occurred more fre-

quently following kyphoplasty with 3 patients requiring secondary kyphoplasty stabilizations. No other medical complications were reported in these studies; however, catastrophic complications have been described in other studies.¹⁵

There is an ongoing multi-institutional randomized trial of balloon kyphoplasty and nonsurgical care for cancer patients with vertebral compression fractures by the Cancer Patient Fracture Evaluation (CAFE) Study Investigators. Preliminary results were recently presented in a podium presentation (Vrionis, FD. A randomized trial of balloon kyphoplasty and nonsurgical care for cancer patients with vertebral compression fractures. AANS/CNS Section on Disorders of the Spine and Peripheral Nerves, 25th Annual Meeting: Phoenix, AZ, March 11–14). About 21 sites enrolled 70 patients to kyphoplasty and 64 patients to nonsurgical care. The primary endpoint was the 1-month change in the 25-point Roland-Morris Disability questionnaire, while back pain was evaluated using an 11-point scale. Statistically significant improvements were demonstrated in disability and pain following kyphoplasty. There were no significant differences in the number of patients with serious adverse events between 2 groups. While these results have not yet been published in a peer-review journal, they are encouraging and consistent with the results of other prospective studies.

Absolute contraindications to vertebral augmentation include asymptomatic lesions, patients who are improving on medical care, ongoing local or systemic infection, retropulsed bone fragment or epidural tumor causing myelopathy, uncorrectable coagulopathy, and allergy to bone cement or opacification agent.⁵³ Radiculopathy that is in excess of vertebral pain, caused by tumor or bone fragments, may be better treated by decompressive surgery and/or radiation therapy. In general, radiation therapy, radiosurgery, and chemotherapy are used to treat the underlying neoplastic component. Some have recently combined vertebral augmentation with radiofrequency ablation^{19,22,28} or direct alcohol injection²³ to improve local control.

Embolization of spinal tumors has been advocated since the 1960s. Tumors most commonly reported and that seem to benefit most from embolization are highly vascular tumors such as metastatic renal cell and thyroid carcinoma, hemangiomas, and ABCs. Preoperative embolization has been shown to decrease blood loss at the time of surgery, which is believed to decrease surgical morbidity, shorten the operative procedure time, increase the chances of complete surgical resection, decrease the risk of damage to adjacent normal tissue, and finally allow better visualization of the surgical field with decreased overall surgical complications.

The most significant and feared risk of paraplegia/quadruplegia due to spinal cord ischemia/infarction from embolization of spinal cord vessels and in particular the artery of Adamkiewicz was not reported in the studies reviewed. Nonetheless, the risks related to spinal angiog-

raphy are sufficient to dissuade its common practice in preoperative planning for cases where embolization is not sought. The only exception, in our experience, is if segmental feeders are to be disrupted bilaterally at any 1 level between T8 and L2.

Embolization has been reported with PVA, coils, Gelfoam, glue (N-butyl cyanoacrylate), Onyx (ethylene vinyl alcohol polymer), Embospheres, and alcohol. PVA is most commonly used providing an inexpensive material that penetrates the tumor bed very effectively. Larger particles reduce chance of cord and skin infarction. Embolized vessels will recanalize over several weeks and so surgery is ideally performed within a few days of embolization. Given that embolization is generally performed before surgery, there is no need to use permanent embolic agents such as glue, Onyx, embospheres, and alcohol.

Direct percutaneous embolization is also possible as an adjunct to or instead of transarterial embolization.⁵⁴ Recently, transarterial embolization for palliation alone has been reported to offer rapid and lasting relief of pain, improve neurologic symptoms, and provide local control of tumor growth.⁵⁵ This is particularly true of giant cell tumors. Boriani *et al*⁵² treated 4 ABCs with embolization alone for curative purposes with 3 having no recurrence and suggested arterial embolization may be the treatment of choice in managing these tumors. Another technology is chemoembolization that combines intra-arterial local chemotherapy and embolization. This technique has been shown to provide durable pain relief with up to 30% demonstrating a radiologic response.⁵⁶

■ Conclusion

The percutaneous techniques reviewed for the treatment of spinal tumors offer numerous advantages and greatly enhance our ability to treat complex, refractory, and palliative cases. Numerous prospective studies support vertebroplasty and kyphoplasty as both safe and effective treatment methods in spinal metastases.

Question 1: Should cement augmentation be used in patients with painful compression fractures associated with metastatic spine disease? The SOSG recommends cement augmentation in patients with painful compression fractures secondary to metastatic spine disease. Strong Recommendation, moderate quality evidence. Each cement augmentation modality has its advantages and the better technique will ultimately depend on the comfort-level of the treating clinician.

Embolization is less well studied but overwhelming clinical experience suggests it is safe and effective in decreasing intraoperative blood loss in hypervascular tumors.

Question 2: Should embolization procedures be used in hypervascular metastatic tumors? We recommend embolization procedures to reduce operative blood loss in hypervascular tumors. Strong Recommendation, very low quality evidence. Future research in this field will

depend on collaborative efforts among cancer centers to further our knowledge on the usefulness, safety, and applicability of these percutaneous procedures.

■ Key Points

- There is strong recommendation and moderate evidence for the use of vertebral augmentation procedures in alleviating pain and improving function in patients with osteolysis or compression fractures secondary to tumor infiltration.
- Vertebral augmentation is most commonly used to treat pain in metastatic and multiple myeloma lesions.
- There is strong recommendation and very low evidence for transarterial and percutaneous direct embolization in reducing intraoperative blood loss.
- Further research is required to confirm these results.

References

1. Jensen ME, Kallmes DE. Percutaneous vertebroplasty in the treatment of malignant spine disease. *Cancer J* 2002;10:194–206.
2. Dahl OE, Garvik LJ, Lyberg T. Toxic effects of methyl methacrylate monomer on leukocytes and endothelial cells in vitro. *Acta Orthop Scand* 1994; 65:147–53.
3. Deramond H, Wright NT, Belkoff SM. Temperature elevation caused by bone cement polymerization during vertebroplasty. *Bone* 1999;25(suppl 2): 17S–21S.
4. Harris RP, Helfand M, Woolf SH, et al. Current methods of the US. Preventive Services Task Force: a review of the process. *Am J Prev Med* 2001;20: 2135.
5. Guyatt G. *User's Guide to the Medical Literature: A Manual for Evidence-Based Clinical Practice*. 2nd ed. New York, NY: McGraw Hill; 2008.
6. Cahana A, Seium Y, Diby M, et al. Percutaneous vertebroplasty in octogenarians: results and follow-up. *Pain Pract* 2005;4:316–23.
7. Cheung G, Chow E, Holden L, et al. Percutaneous vertebroplasty in patients with intractable pain from osteoporotic or metastatic fractures: a prospective study using quality-of-life assessment. *Intervent Radiol* 2006;57:13–21.
8. Ramos L, de las Heras JA, Sanchez S, et al. Medium-term results of percutaneous vertebroplasty in multiple myeloma. *Eur J Haematol* 2006;77:7–13.
9. Cotten A, Dewatre F, Cortet B, et al. Percutaneous vertebroplasty for osteolytic metastases and myeloma: effects of the percentage of lesion filling and the leakage of methyl methacrylate at clinical follow-up. *Radiology* 1996; 200:525–30.
10. Cortet B, Cotten A, Boutry N, et al. Percutaneous vertebroplasty in patients with osteolytic metastases or multiple myeloma. *Rev Rhum [Eng]* 1997;64: 177–83.
11. Anselmetti GC, Zoarski G, Manca A, et al. Percutaneous vertebroplasty and bone cement leakage: clinical experience with a new high-viscosity bone cement and delivery system for vertebral augmentation in benign and malignant compression fractures. *Cardiovasc Intervent Radiol* 2008;31:937–47.
12. Anselmetti GC, Carrao G, Della Monica P, et al. Pain relief following percutaneous vertebroplasty: results of a series of 283 consecutive patients treated in a single institution. *Cardiovasc Intervent Radiol* 2007;30:441–7.
13. Jang JS, Lee SH. Efficacy of percutaneous vertebroplasty combined with radiotherapy in osteolytic metastatic spinal tumors. *J Neurosurg Spine* 2005; 2:243–8.
14. Fournay DR, Schomer D, Nader R, et al. Percutaneous vertebroplasty and kyphoplasty for painful vertebral body fractures in cancer patients. *J Neurosurg Spine* 2003;98:21–30.
15. Barragan-Campos HM, Vallee JN, Lo D, et al. Percutaneous vertebroplasty for spinal metastases: complications. *Radiology* 2006;238:354–62.
16. Calmels V, Vallee JN, Rose M, et al. Osteoblastic and mixed spinal metastases: evaluation of the analgesic efficacy of percutaneous vertebroplasty. *AJNR* 2007;28:570–4.

17. McDonald RJ, Trout AT, Gray LA, et al. Vertebroplasty in multiple myeloma: outcomes in a large patient series. *AJNR* 2008;29:642–8.
18. Alvarez L, Perez-Higueras A, Quinones D, et al. Vertebroplasty in the treatment of vertebral tumors: postprocedural outcome and quality of life. *Eur Spine J* 2003;12:356–60.
19. van der Linden E, Kroft LJM, Dijkstra S. Treatment of vertebral tumor with posterior wall defect using image-guided radiofrequency ablation combined with vertebroplasty: preliminary results in 12 patients. *J Vasc Interv Radiol* 2007;18:741–8.
20. Weill A, Chiras J, Simon JM, et al. Spinal metastases: indications for and results of percutaneous injection of acrylic surgical cement. *Radiology* 1996;199:241–7.
21. Shimony JS, Gilula LA, Zeller AJ, et al. Percutaneous vertebroplasty for malignant compression fractures with epidural involvement. *Radiology* 2004;232:846–53.
22. Hoffmann RT, Jacobs TF, Trumm C, et al. Radiofrequency ablation in combination with osteoplasty in the treatment of painful metastatic bone disease. *J Vasc Interv Radiol* 2008;19:419–25.
23. Hentschel SJ, Burton AW, Fourney DR, et al. Percutaneous vertebroplasty and kyphoplasty performed at a cancer center: refuting proposed contraindications. *J Neurosurg Spine* 2005;2:435–40.
24. Chen L, Zhang CL, Tang TS. Cement vertebroplasty combined with ethanol injection in the treatment of vertebral hemangioma. *Chin Med J* 2007;120:1136–9.
25. Kose KC, Cebesoy O, Akan B, et al. Functional results of vertebral augmentation techniques in pathological vertebral fractures of myelomatous patients. *J Natl Med Assoc* 2006;98:1654–8.
26. Sun G, Cong Y, Xie Z, et al. Percutaneous vertebroplasty using instruments and drugs made in China for vertebral metastases. *Chin Med J* 2003;116:1207–12.
27. Muto M, Muto E, Izzo R, et al. Vertebroplasty in the treatment of back pain. *Radiol Medica* 2004;109:208–19.
28. Masala S, Lunardi P, Fiori R, et al. Vertebroplasty and kyphoplasty in the treatment of malignant vertebral fractures. *J Chemo* 2004;16:S30–3.
29. Caudana R, Renzi Brivio L, Ventura L, et al. CT-guided percutaneous vertebroplasty: personal experience in the treatment of osteoporotic fractures and dorsolumbar metastases. *Radiol Med* 2008;113:114–33.
30. Masala S, Anselmetti GC, Marcia S, et al. Percutaneous vertebroplasty in multiple myeloma vertebral involvement. *J Spinal Disord Tech* 2008;21:344–8.
31. Mont'Alverne F, Valle JN, Cormier E, et al. Percutaneous vertebroplasty for metastatic involvement of the axis. *AJNR* 2005;26:1641–5.
32. Barbero S, Casorzo I, Durando M, et al. Percutaneous vertebroplasty: the follow-up. *Radiol Med* 2008;113:101–13.
33. Anselmetti GC, Corgnier A, Debernardi F, et al. Treatment of painful compression vertebral fractures with vertebroplasty: results and complications. *Radiol Med* 2004;11:262–72.
34. Khanna AJ, Reinhardt MK, Togawa D, et al. Functional outcomes of kyphoplasty for the treatment of osteoporotic and osteolytic vertebral compression fractures. *Osteoporos Int* 2006;17:817–26.
35. Gerszten PC, Germanwala A, Burton SA, et al. Combination kyphoplasty and spinal radiosurgery: a new treatment paradigm for pathological fractures. *J Neurosurg Spine* 2005;3:296–301.
36. Dudeney S, Lieberman IH, Reinhardt MK, et al. Kyphoplasty in the treatment of osteolytic vertebral compression fractures as a result of multiple myeloma. *J Clin Oncol* 2002;9:2282–7.
37. Lane JM, Hong R, Koob J, et al. Kyphoplasty enhances function and structural alignment in multiple myeloma. *Clin Orthop Relat Res* 2004;426:49–53.
38. Pflugmacher R, Taylor R, Agarwal A, et al. Balloon kyphoplasty in the treatment of metastatic disease of the spine: a 2-year prospective evaluation. *Eur Spine J* 2008;17:1042–8.
39. Pflugmacher R, Beth P, Schroeder RJ, et al. Balloon kyphoplasty for the treatment of pathological fractures in the thoracic and lumbar spine caused by metastasis: one-year follow-up. *Acta Radiol* 2007;48:89–95.
40. Pflugmacher R, Kandziora F, Schroeder RJ, et al. Percutaneous balloon kyphoplasty in the treatment of pathological vertebral body fracture and deformity in multiple myeloma: a one-year follow-up. *Acta Radiol* 2006;47:369–76.
41. Atalay B, Caner H, Gokee C, et al. Kyphoplasty: 2 years of experience in a neurosurgery department. *Surg Neurol* 2005;64:S2:72–6.
42. Sundaresan N, Choi IS, Hughes, et al. Treatment of spinal metastases from kidney cancer by presurgical embolization and resection. *J Neurosurg* 1990;73:548–54.
43. Smith TP, Gray L, Weinstein JN, et al. Preoperative transarterial embolization of spinal column neoplasms. *J Vasc Interv Radiol* 1995;6:863–9.
44. Vetter SC, Strecker EP, Ackerman LW, et al. Preoperative embolization of cervical spine tumors. *Cardiovasc Intervent Radiol* 1997;20:343–7.
45. Jayakumar PN, Vasudev MK, Srikanth SG. Symptomatic vertebral haemangioma: endovascular treatment of 12 patients. *Spinal Cord* 1997;35:624–8.
46. Berkefeld J, Scale D, Kirchner J, et al. Hypervascular spinal tumors: influence of the embolization technique on perioperative hemorrhage. *AJNR* 1999;20:757–63.
47. Shi HB, Suh DC, Lee HK, et al. Preoperative transarterial embolization of spinal tumor: embolization techniques and results. *AJNR* 1999;20:2009–15.
48. Manke C, Bretschneider T, Lenhart M, et al. Spinal metastases from renal cell carcinoma: effect of preoperative particle embolization on intraoperative blood loss. *AJNR* 2001;22:997–1003.
49. Prabhu VC, Bilsky MH, Jambhekar K, et al. Results of preoperative embolization for metastatic spinal neoplasms. *J Neurosurg* 2003;98(suppl 2):156–64.
50. Wirbel RJ, Roth R, Schulte M, et al. Preoperative embolization in spinal and pelvic metastases. *J Orthop Sci* 2005;10:253–7.
51. Guzman R, Dubach-Schwizer S, Heini P, et al. Preoperative transarterial embolization of vertebral metastases. *Eur Spine J* 2005;14:263–8.
52. Boriani S, De Iure F, Campanacci L, et al. Aneurysmal bone cyst of the mobile spine: report on 41 cases. *Spine* 2001;26:27–35.
53. McGraw KJ, Cardella J, Barr JD, et al. Society of Interventional Radiology quality improvement guidelines for percutaneous vertebroplasty. *J Vasc Interv Radiol* 2003;14:S311–5.
54. Quadros RS, Gallas S, Delcourt C, et al. Preoperative embolization of a cervicodorsal paraganglioma by direct percutaneous injection of Onyx and endovascular delivery of particles. *AJNR* 2006;27:1907–9.
55. Acosta FL, Sanai N, Chi JH, et al. Comprehensive management of symptomatic and aggressive hemangiomas. *Neurosurg Clin N Am* 2008;19:17–29.
56. Chiras J, Adem C, Vallee JN, et al. Selective intra-arterial chemoembolization of pelvic and spine bone metastases. *Eur Radiol* 2004;14:1774–80.



7075 Veterans Boulevard, Burr Ridge, IL 60527
Toll-free: (866) 960-6277 Phone: (630) 230-3600
Fax: (630) 230-3700 Web: www.spine.org

February 18, 2011

Washington State Health Technology Assessment
676 Woodland Square Loop SE
Lacey, WA 98503

RE: Vertebroplasty, Kyphoplasty and Sacroplasty
Washington State Health Technology Assessment:

I am writing on behalf of the North American Spine Society (NASS) to comment on the draft Washington State Health Technology Assessment (HTA) for Vertebroplasty, Kyphoplasty and Sacroplasty. The North American Spine Society was founded in 1984 and currently represents more than 5,500 spine care physicians and affiliated health practitioners both nationally and internationally. NASS is dedicated to fostering the highest quality, evidence-based, ethical spine care by promoting education, research and advocacy. NASS members include MDs, DOs and PhDs in 24 spine-related specialties including orthopedics, neurosurgery, physiatry, pain management and other disciplines, including allied health professionals.

Summary of Evidence

NASS welcomes the opportunity to comment on the HTA. We do not feel that a unilateral noncoverage determination is appropriate. NASS believes it would be far better to enforce appropriateness criteria to coverage of this procedure. Consistent with NASS recommendations to other insurance providers, we believe that the procedure is indicated after failure of conservative/nonoperative management that has been employed for the first 6 weeks following the onset of an acute osteoporotic compression fracture, as documented by an MRI or bone scan indicating increased bone edema at the levels in question, and a physical examination that demonstrates point tenderness over the fracture site. The rationale for this recommendation is that, as indicated by the literature cited, the majority of patients with acute osteoporotic compression fractures will have symptom resolution in the first few weeks. Delaying vertebral augmentation, except in severely debilitated patients who are bedbound from their pain (as detailed in the current policy), would avoid unnecessary intervention in many patients who will have satisfactory outcomes with nonoperative care. Likewise, the procedure may not be best suited for patients with pain from fractures that are chronic (greater than 3 to 6 months), as supported by the recent RCTs as well as other studies (Alvarez et al, 2006).

These recommendations are further supported by data from a very recently published randomized controlled trial (Klazen et al, 2010, Lancet). After screening 934 patients who had truly acute pain (6 weeks or less) associated with an osteoporotic compression fracture, 229 who could have been included in the study had spontaneous resolution of pain during further assessment and were subsequently excluded. Despite some methodological issues, the findings from this study lend further support to the effectiveness of vertebroplasty for acute osteoporotic compression fractures, as there was significantly better pain relief with the procedure compared to conservative treatment and support that a threshold of 6 weeks during which conservative treatment should be attempted before deciding to proceed with vertebroplasty. The study by Klazen et al, in distinction to the RCTs published by Buchbinder et al and Kallmes et al, presents more stringent selection criteria that would reflect best clinical practice and NASSs recommendations for vertebroplasty coverage. Specifically, Klazen et al included patients who had “visual analogue scale [pain] score of 5 or more; bone oedema of vertebral fracture on MRI; focal tenderness at fracture level...” Regardless of their methodological differences, the results of the most recent RCT do not contradict the findings of the Buchbinder et al and Kallmes et al. In fact, they help complete the picture in that the latter 2 RCTs demonstrate that vertebroplasty is minimally effective for subacute and chronic fractures while the former demonstrates that it is effective for acute fractures.

Finally, we strongly feel that vertebroplasty for the treatment of pathological fractures (i.e. metastatic lesions, multiple myeloma) should be covered as a medically necessary procedure. The coverage policy should distinguish between vertebroplasty for osteoporotic compression fractures, which should follow the above described appropriateness criteria, and pathological fractures, which should not, by nature of the disease, have a restricted time period of appropriate use.

NASS appreciates the opportunity to review and comment on this draft HTA. If you have any questions, please contact Allison Waxler in the NASS national office at (630) 230-3683 or via e-mail awaxler@spine.org.

Sincerely,

A handwritten signature in black ink, appearing to read 'Gregory Przybylski', with a long horizontal flourish extending to the right.

Gregory Przybylski, MD
President, North American Spine Society

On 2/5/11 4:12 PM, "Theodore Wagner" <wagner@u.washington.edu> wrote:

Dear Mr. Santoyo

As a spine surgeon at the UW and a member of both the Orthopedic and Neurosurgery Departments, I am writing to you after learning that your committee has asked whether kyphoplasty /vertebroplasty should be one of the many procedures to be considered safe and appropriate for our patients.

I strongly believe that after fifteen years of experience with kyphoplasty, we have learned how to select patients for this procedure for a single osteoporotic or pathologic fracture or as an important adjunct to a complicated surgery which leaves the end vertebrae at risk for collapse.

I have had added an addendum to this email which is a power point of a lecture that I gave to the oncologists. I hope you review this work in light of the pain reduction in a group of patients who suffered with real spinal pain. I do hope that you might consider this procedure appropriate for my family or your family if the need arrives.

Sincerely,

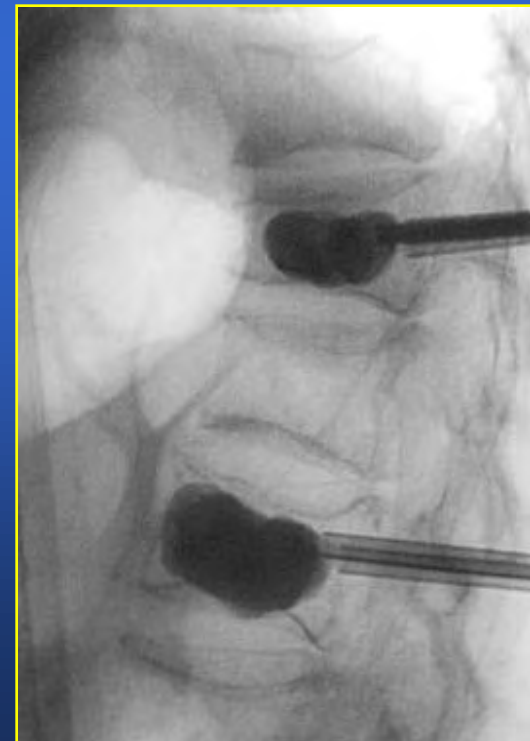
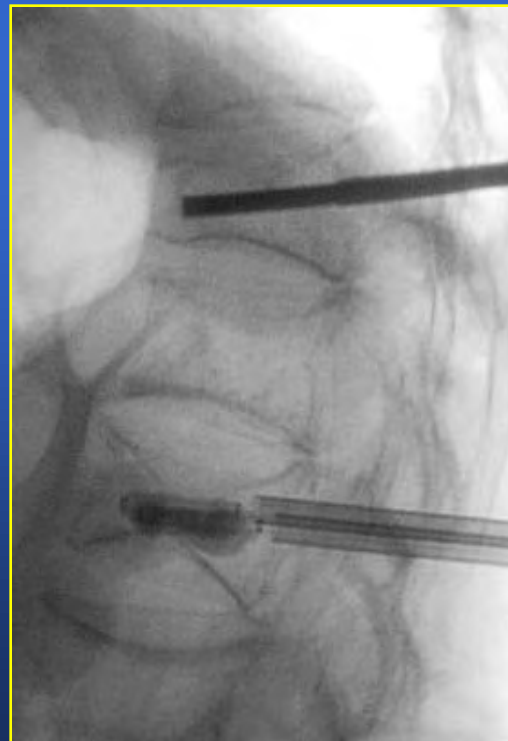Theodore A Wagner MD
Professor of Orthopedic Surgery
University of Washington
Seattle, WA

Challenges and Controversies in Breast Cancer

October 21, 2005

Kyphoplasty for Malignant Vertebral Fractures

Theodore A. Wagner
Clinical Professor
University of Washington
Orthopaedics & Sports Medicine



Spinal Mets in Cancer Patients

All Cancer Patients



70% develop metastatic disease



40% develop spinal Mets



10-20% of these patients develop spinal cord compression (25000 cases/year)



Location: 70 % T, 20% L, 10% C

Metastatic Bone Disease

Epidemiology - Etiology

	Estimated Number of Persons Living with Cancer ¹	Number of New Cases in 2004 ¹	Incidence of Bone Metastases ²
Breast	2,184,125 (24%)	217,440 (16%)	65-75%
Prostate	1,838,653 (20%)	230,110 (17%)	65-75%
Bladder	521,945 (6%)	60,240 (4%)	40%
Lung	388,538 (4%)	173,770 (13%)	30-40%
Thyroid	273,642 (3%)	23,600 (2%)	60%
Other	4,013,458 (43%)	705,160 (52%)	
Total	9,220,361 (100%)	1,368,030 (100%)	

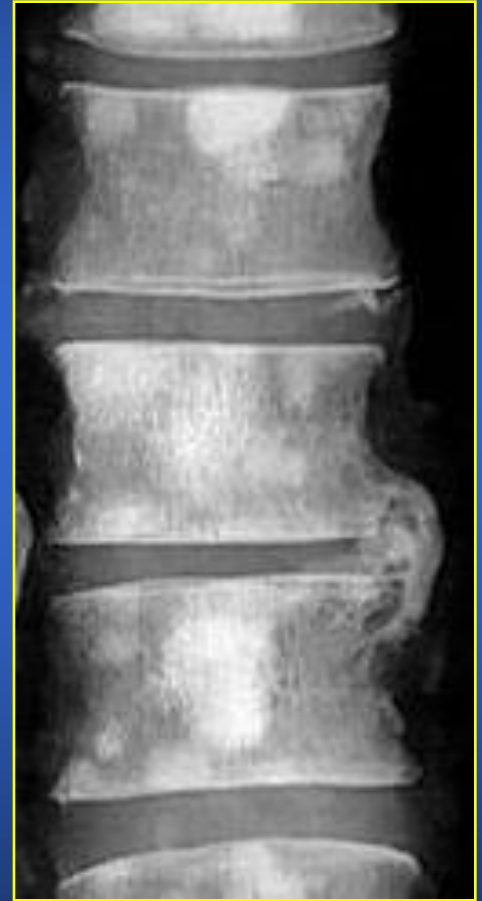1. SEER Cancer Statistics Review 1975 – 2001, National Cancer Institute

2. Coleman, R.E. *Cancer Treatment Reviews*. 2001;27:165-176.

Metastatic Bone Disease

Lesion Types

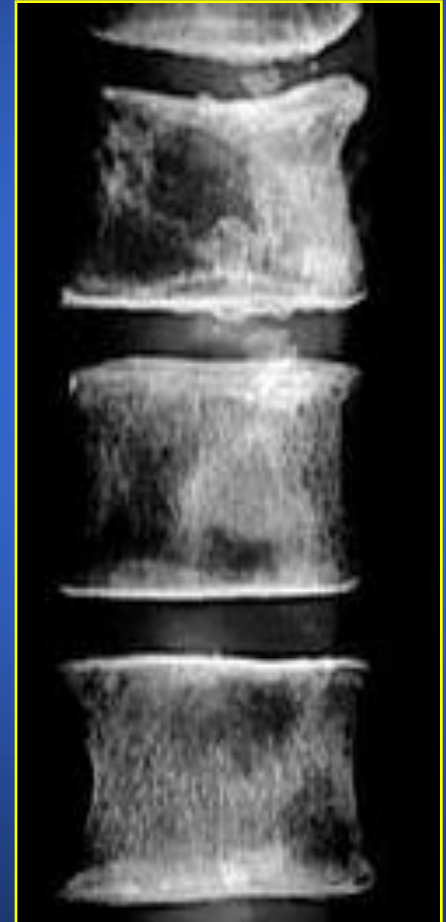- Osteoblastic
 - Increased bone density
 - Does not change bone strength but decreases bone stiffness
 - Common in prostate cancer



Metastatic Bone Disease

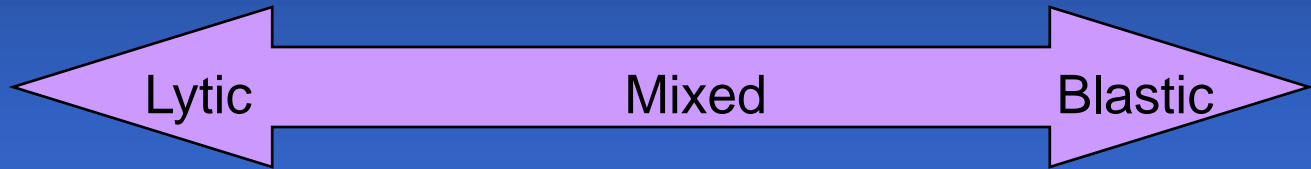Lesion Types

- Osteolytic
 - Decreased bone density
 - Decreases both bone strength and stiffness
 - Common in patients with metastatic cancer and multiple myeloma
 - *Higher risk for fracture than blastic lesions*



Metastatic Bone Disease

Radiographic Appearance of Skeletal Metastases



Breast	X	X	X
Prostate			X
Bladder	X		
Lung	X	X	
Thyroid	X		

Metastatic Bone Disease

Clinical Sequelae

- Bone pain
- Pathologic fracture
 - Vertebral compression fractures
 - Long bones
- Spinal cord compression
- Hypercalcemia

Metastatic Bone Disease

Fractures

- 17 – 50% of patients with metastatic breast cancer will develop VCFs annually.¹
- Median time to first fracture among breast cancer patients (not on bisphosphonate) with at least one lytic lesion is 12.8 months.²

1. Body. *Cancer*. 2003;97:859-865.

3. Hortobagyi GN, Theriault RL, Lipton A, et al. *J Clin Oncol*. 1998;16:2038-2044.

Metastatic Bone Disease

Prognosis

- Once bone metastasis occurs, prognosis is generally poor
- Patients with longer median survival will require treatment for skeletal complications

Disease Type	Median Survival (months)
Multiple Myeloma ¹	36 – 60
Breast ²	29*
Lung ³	5*
* After disease metastasizes to bone	

1. Attal, et al. *NEJM*. 1996;335:91-97.

2. Andre, et al. *J of Clinical Oncology*. 2004;22:3302-3308.

3. Ryo, et al. *Nihon Kokyuki Gakkai Zasshi*. 1998;36:317-22.

Metastatic Bone Disease

Treatment Goals

- Reduce pain
- Prevent neurologic complications
- Treat pathologic fractures and prevent recurrent fracture

Metastatic Bone Disease Management

- Surgical
- Non surgical
 - Radiotherapy
 - Chemotherapy
 - Hormone Therapy
 - Immunotherapy

Indications for Surgical Management

- Spinal Instability
- Significant neural compression
- Radioresistant tumors
- Intractable pain unresponsive for nonoperative measures
- Radiation failure
- No brain mets

Indications for Surgical Management

- General medical condition
 - Safe extubation
- Estimated life expectancy > 3 months???
- Scoring systems

Goal of Surgical Management

- Spine stabilization
- Decompressing neural elements
- Obtaining diagnosis for unknown primary

Outcome of Surgical Vs Radiation Management

RTC Patchell R et al; J Clin Oncol 2003;21:237

	Surgical Resection + Radiation	Radiation Alone
# of patients	50	51
Regain ability to walk in nonambulators	56%	19%
Length of retaining ambulatory and sphincter function	Longer	
Length of survival	No difference	

Complications of Surgical Management

- Wound infection
- New neurogenic deficit
- Hardware related
- DVT/PE

Minimally Invasive Spine Surgery (MISS)

- Minimize trauma to soft tissue
- Shorter operative time
- Less blood loss
- Less postoperative pain
- Lower medication use
- Shorter hospital stay
- Lower costs

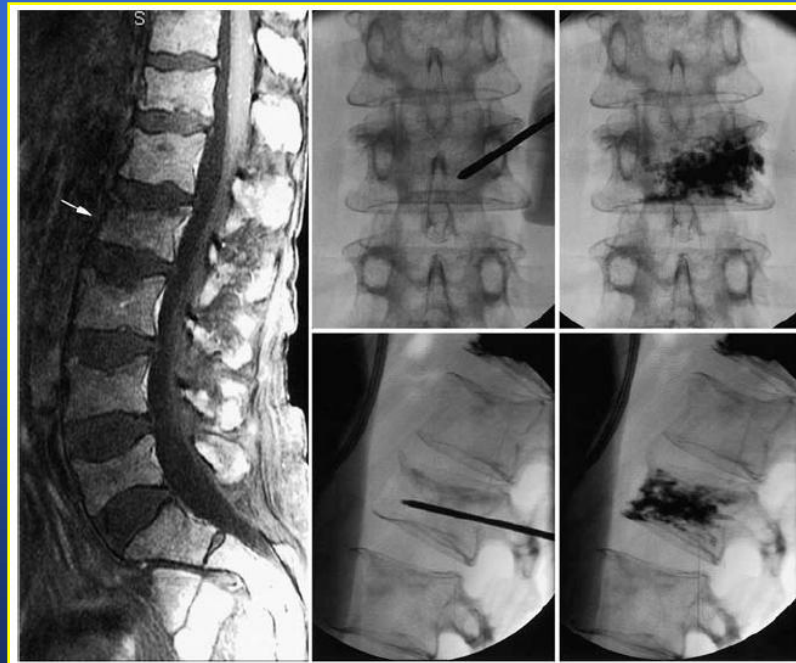Minimally Invasive Spine Surgery (MISS)

- Endoscopic resection
- Vertebroplasty
- Kyphoplasty

- **Vertebroplasty**
 - introduced in France 1984 by interventional neuroradiologist Herve Deramond
 - First US case series reported in 1997
- **Kyphoplasty** introduced by orthopedic surgeon Mark Reiley in early 1990s

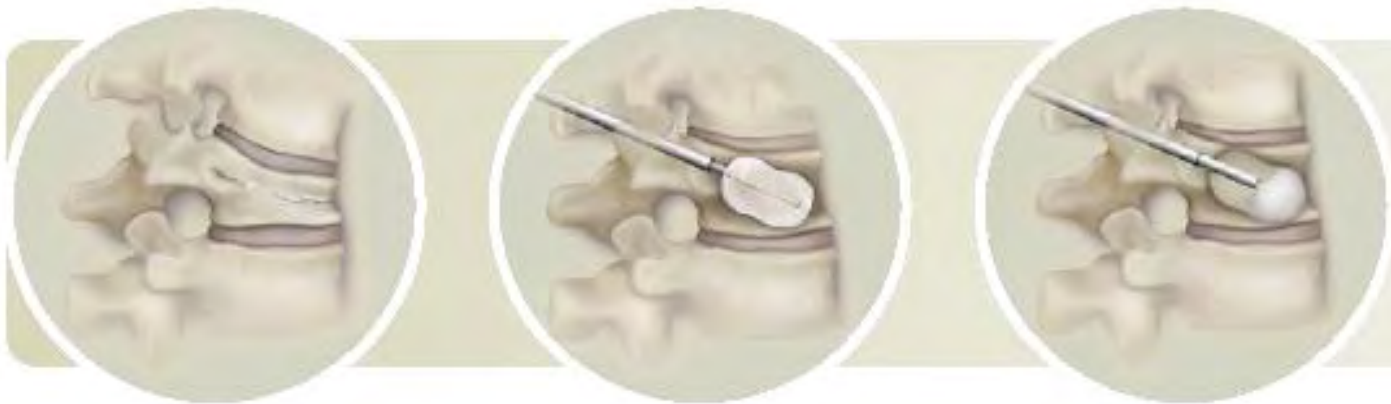Vertebroplasty / Kyphoplasty

- Both involve percutaneous injection of PMMA into collapsed vertebral body
- Vertebroplasty: vertebral body not re-expanded



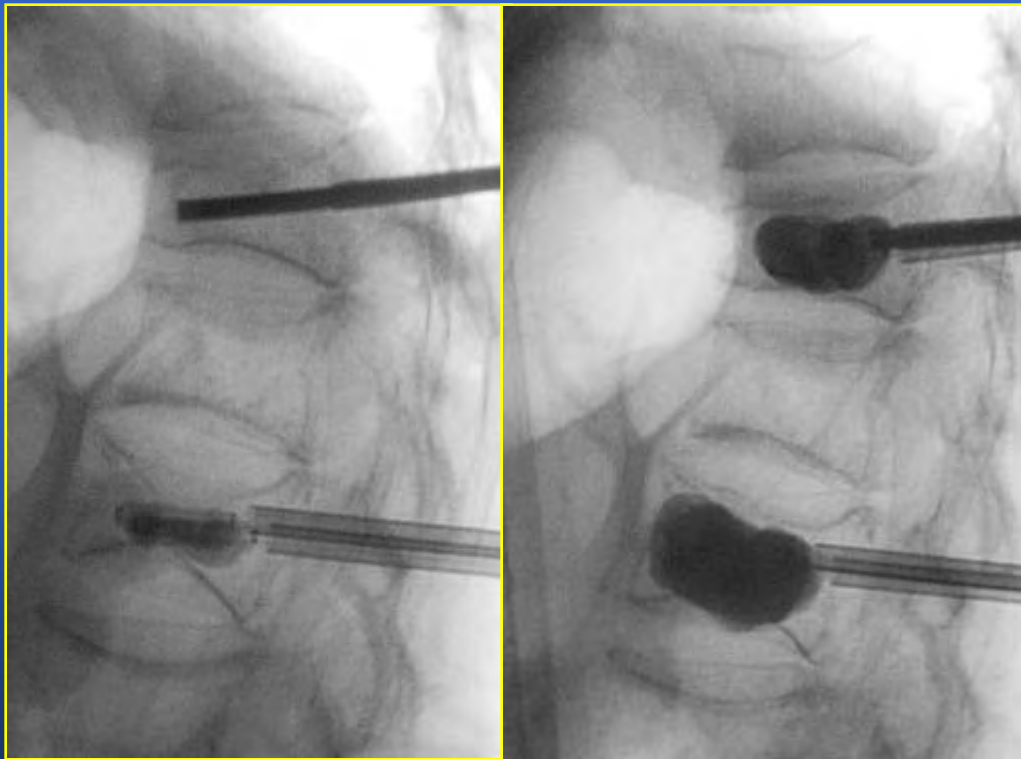
Balloon Kyphoplasty

A balloon (tamp) is placed into vertebral body followed by inflation deflation sequence to create a cavity prior to cement injection to improve body height and reduce kyphosis



Kyphoplasty Case Study

Patient: 61 YO Female
Diagnosis: Multiple Myeloma
Fracture Reduced: T11, L2, 1 ½ yrs old



Courtesy of Kent Grewe, M.D., Portland, OR

Tumor-Related VCFs

Balloon Kyphoplasty Procedure

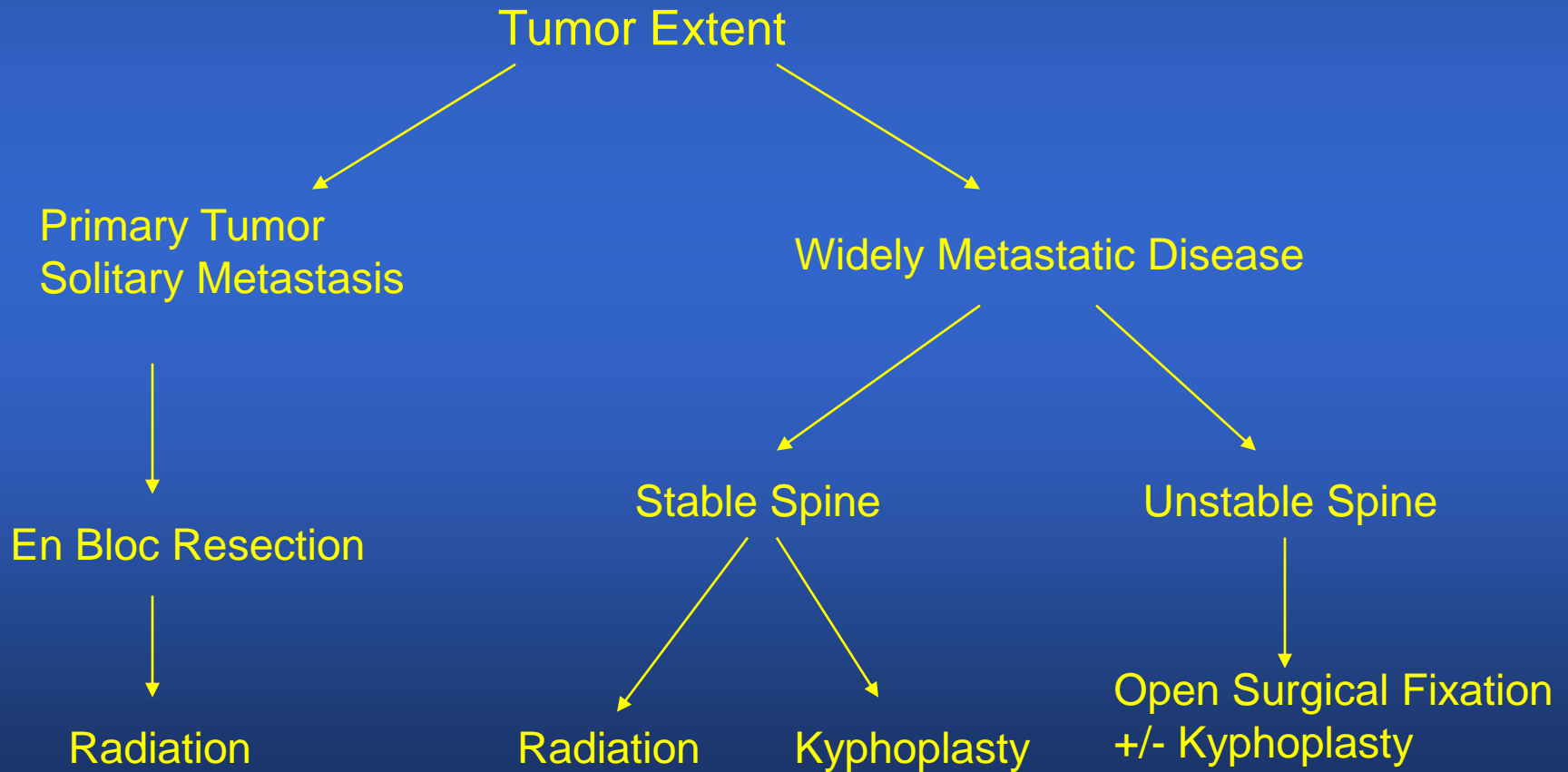
- Minimally invasive
- Bilateral, 1 cm incisions
- Typically one hour per treated fracture
- General or local anesthesia (supplemented by conscious sedation)
- May require an overnight hospital stay

Vertebroplasty / Kyphoplasty

- Indications
 - Osteoporotic fractures
 - Spinal Mets
 - Ideal patient
 - Poor surgical candidate
 - Disabling pain secondary to pathological T or L
Compression vertebral body fracture
 - No epidural compression

Treatment Algorithm

Managing Tumor-Related VCFs



Tumor-Related VCFs

Balloon Kyphoplasty Treatment Goals

- Restoration of height and stability in fractured vertebral body
- Treatment of pain related to vertebral collapse

Tumor-Related VCFs

Vertebroplasty vs. Balloon Kyphoplasty

	Vertebroplasty	Balloon Kyphoplasty
Fracture Reduction	Postural Reduction	Inflatable Bone Tamp
Cavity Creation	--	Inflatable Bone Tamp
Cement Injection	<ul style="list-style-type: none">• High pressure injection into interstices• Runny cement	<ul style="list-style-type: none">• Low pressure fill into cavity created by IBT• Doughy cement

Complications

Kyphoplasty < Vertebroplasty

- PMMA related
 - Hypotension
 - Cardiac arrest
 - Cerebrovascular accident
 - Myocardial infarction
 - Pulmonary embolism

Complications

Kyphoplasty < Vertebroplasty

- Procedure related
 - Wound infection
 - Hematoma
 - Heterotopic new bone formation
 - Spinal cord and nerve compression due to extrusion of bone cement

Balloon Kyphoplasty: Clinical Outcomes for Oncology Patients

Effectiveness

- Data suggest marked pain relief in kyphoplasty
- Comparative studies are not available

Kyphoplasty in the Treatment of Osteolytic Vertebral Compression Fractures as a Result of Multiple Myeloma

Dudeney, Lieberman: *Journal of Clinical Oncology*. 2002;20:2382-2387

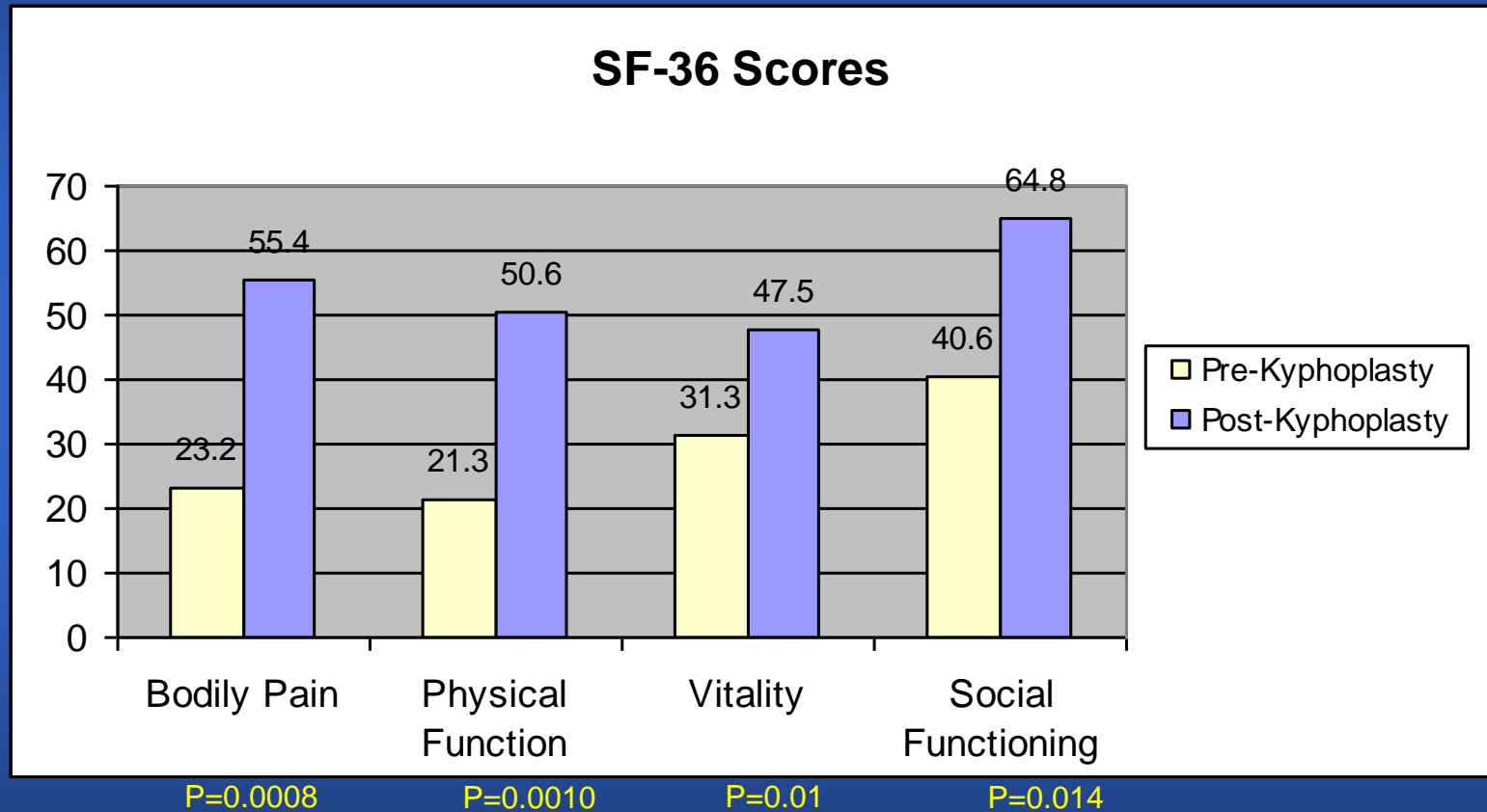
Dudenev and Lieberman Study

Parameters

- 18 patients, 55 levels treated with kyphoplasty
- Levels T6-L5 (27% at T12 or L1)
- Mean follow-up 7.4 months
- Indication: Painful, multiple myeloma-related VCFs

Dudenev and Lieberman Study

Outcomes



Kyphoplasty provides statistically significant improvement in Bodily Pain, Physical Function, Vitality and Social Functioning as measured in SF-36 scores.

Dudenev and Lieberman Study

Outcomes

- Height restoration: 34% restoration of lost vertebral body height.
- Safety: 4% bone cement extravasation rate (2 levels). Both were asymptomatic.

Vertebroplasty and Kyphoplasty for Osteolytic Vertebral Collapse

Lieberman and Reinhardt: *Clinical Orthopaedics and Related Research*. 2003;415(S):176-186

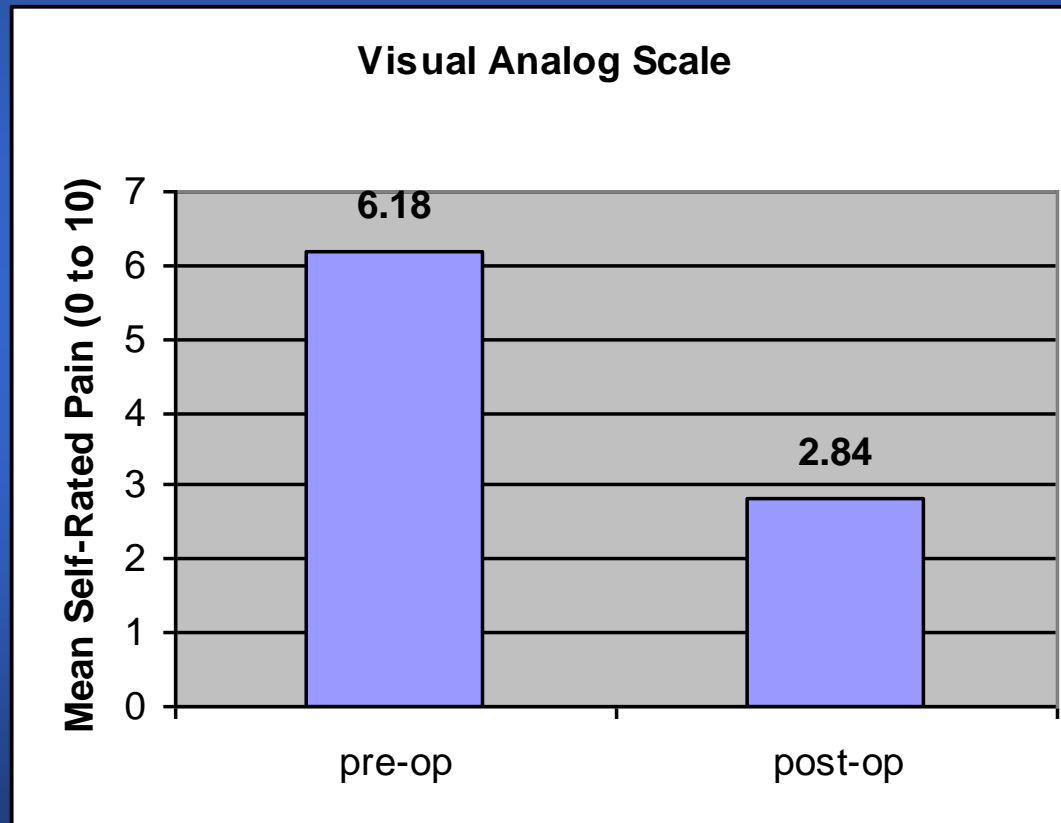
Lieberman and Reinhardt Study

Parameters

- 63 patients with osteolytic collapse
 - 52 with multiple myeloma
 - 11 with osteolytic metastases
- 264 vertebral bodies treated with kyphoplasty
- Mean follow-up
 - 18 weeks in multiple myeloma patients
 - 3 weeks in patients with metastases

Lieberman and Reinhardt Study

Myeloma Patient Outcomes

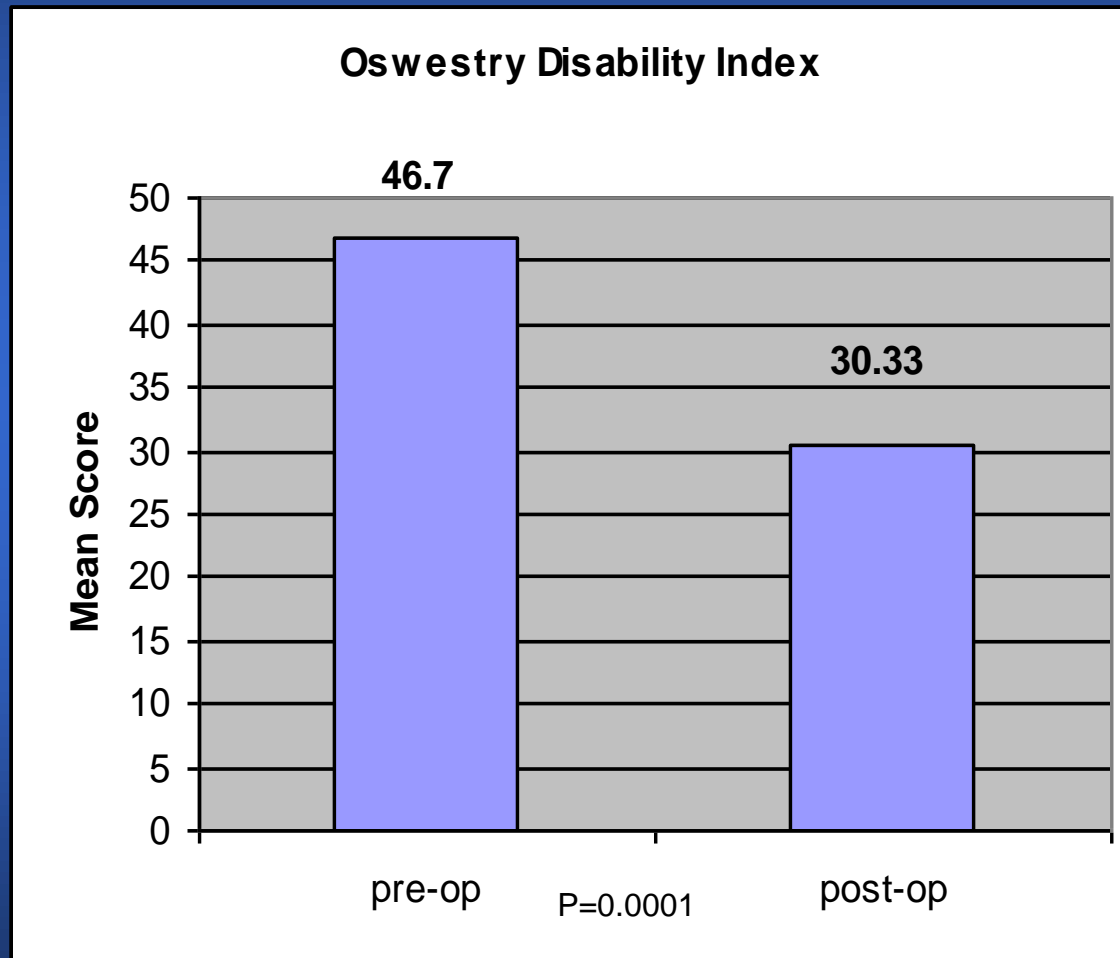


$p < 0.0001$

0 = no pain

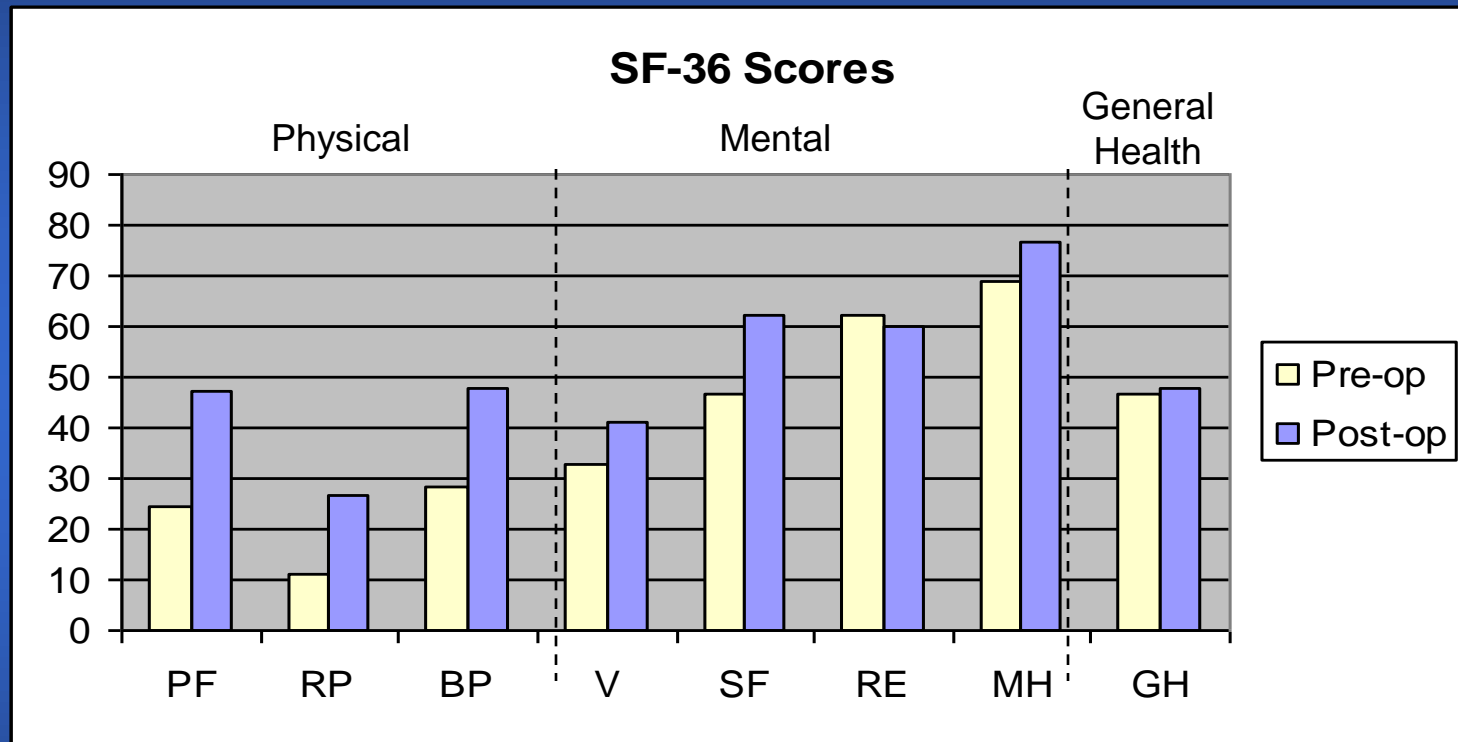
Lieberman and Reinhardt Study

Myeloma Patient Outcomes



Lieberman and Reinhardt Study

Myeloma Patient Outcomes



P<0.0001* P=0.043 *P*=0.0003* P=0.043 P=0.016 P=0.806 P=0.008 P=0.683

**Kyphoplasty provides statistically significant improvement in Bodily Pain and Physical Function as measured in SF-36 scores*

Lieberman and Reinhardt Study

Myeloma Patient Outcomes

- “Less than 5%” asymptomatic leaks in 264 vertebral bodies treated
- No symptomatic cement leaks

Percutaneous Vertebroplasty and Kyphoplasty for Painful Vertebral Body Fractures in Cancer Patients

Fourney: *J. Neurosurg (Spine 1)*. 2003;98:21-30

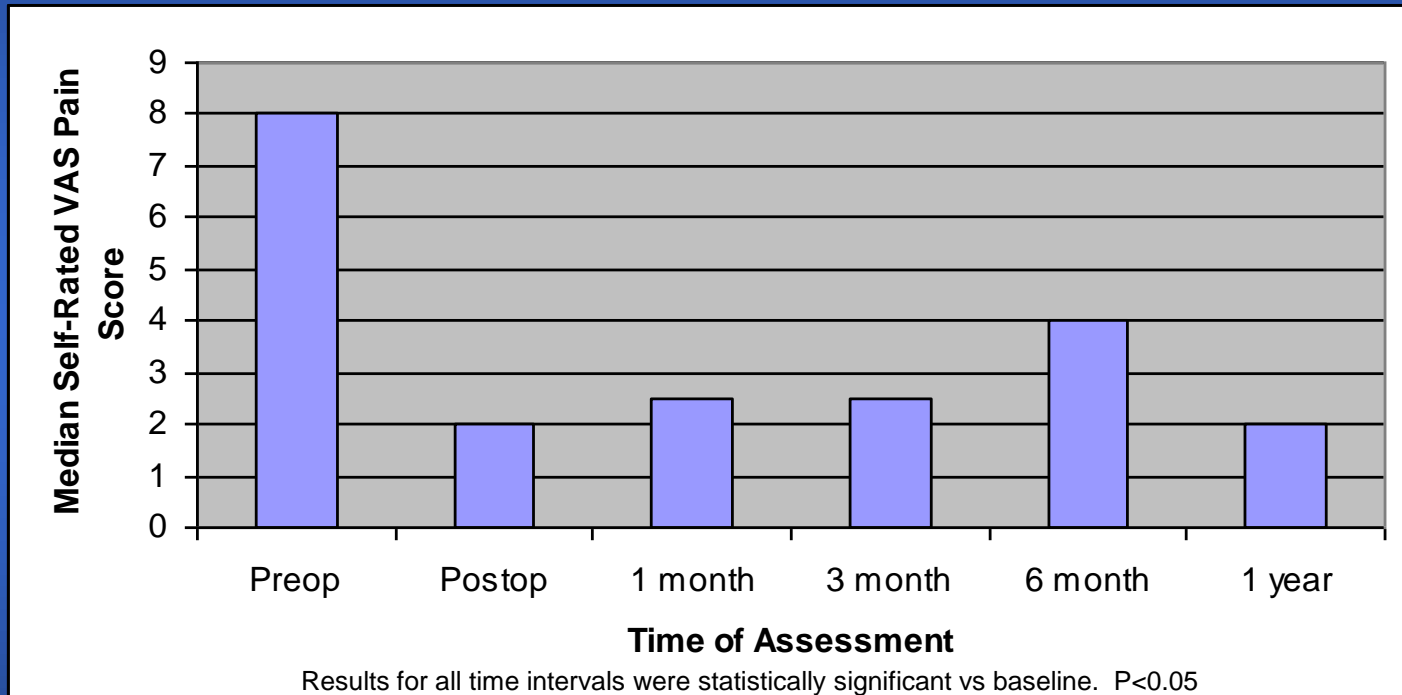
Fourney Study

Parameters

- 56 patients
 - 21 with multiple myeloma
 - 35 with bone metastases
- 97 levels treated
 - 32 with balloon kyphoplasty
 - 65 with vertebroplasty
- All patients had intractable pain due to VCFs
 - Median duration of symptoms 3.2 months
- Mean follow-up 4.5 months

Fourney Study

Outcomes




Kyphoplasty provides sustained pain reduction

Fourney Study

Outcomes

- Marked or complete pain relief in 49/58 patients (84%)
- 42% mean height restoration after kyphoplasty
- Reduced analgesic use in follow-up
- 2 patients underwent repeat procedures for new fractures
- Cement extravasation
 - 9.2% in vertebroplasty (asymptomatic)
 - 0% in kyphoplasty

A photograph of a sunset over a city skyline. The sky is filled with colorful clouds in shades of orange, red, and purple. The sun is low on the horizon, creating a bright glow. In the foreground, there is a body of water and silhouettes of trees. The city skyline is visible in the middle ground, with several tall buildings. The text "Thank You!" and "Ted Wagner, MD" is overlaid on the image in white.

Thank You!
Ted Wagner, MD

As one who has had a balloon Kyphoplasty on L1/L2 and a Vertebroplasty on L3-L5 in 2010 I highly recommend both procedures. My before and after progress was night and day and today I feel fine. As with any type of back surgery whether it be a full invasive surgery or a minimally invasive procedure such as these there is always an amount of residual discomfort after the procedure(s). My discomfort after both of these procedures was exceptionally minimal. Today my range of motion is great, but as with any back surgery I cannot lift heavy objects, but then who can after any back surgery? The other nice thing about these procedures is that the recovery time is minimal (most cases it's an out-patient procedure), the cost is significantly less than a full invasive surgery and one is able to return to work sooner with these procedures. Conservative medical treatment may be an option prior to these surgical procedures, but I feel that these just drag out the treatment process. With the short recovery time, conservative procedures may just delay the inevitable surgery. I strongly endorse all of these procedures as being in the best interest of the individual. Their problem can be fixed quicker, cheaper, they return to work sooner and their life gets back as close to normal like it was before the injury. Thank you for your time on this matter. Dennis

Dennis Eibe

VP Corporate Compliance, Risk Mgmt, Disaster Planning

Phone 206 870 1123

Fax 206 870 1209

DEibe@WesleyHomes.org

Wesley Homes

815 S. 216th Street

Des Moines, WA 98198

206-824-5000

www.wesleyhomes.org